

# Quantification of Levator Ani Cross-Sectional Area Differences Between Women With and Those Without Prolapse

Yvonne Hsu, MD, Luyun Chen, MS, Markus Huebner, MD, James A. Ashton-Miller, PhD, and John O. L. DeLancey, MD

**OBJECTIVE:** Compare levator ani cross-sectional area as a function of prolapse and muscle defect status.

**METHODS:** Thirty women with prolapse and 30 women with normal pelvic support were selected from an ongoing case-control study of prolapse. For each of the two groups, 10 women were selected from three categories of levator defect severity: none, minor, and major identified on supine magnetic resonance scans. Using those scans, three-dimensional (3D) models of the levator ani muscles were made using a modeling program (3D Slicer), and cross-sections of the pubic portion were calculated perpendicular to the muscle fiber direction using another program, I-DEAS. An analysis of variance was performed.

**RESULTS:** The ventral component of the levator muscle of women with major defects had a 36% smaller cross-sectional area, and women with minor defects had a 29% smaller cross-sectional area compared with the women with no defects ( $P < .001$ ). In the dorsal component, there were significant differences in cross-sectional area according to defect status ( $P = .03$ ); women with major levator defects had the largest cross-sectional area compared with the other defect groups. For each defect severity category (none, minor, major), there were no significant differences in cross-sectional area between women with and those without prolapse.

**CONCLUSION:** Women with visible levator ani defects on magnetic resonance imaging had significantly smaller cross-sectional areas in the ventral component of the pubic portion of the muscle compared with women with

intact muscles. Women with major levator ani defects had larger cross-sectional areas in the dorsal component than women with minor or no defects.

(*Obstet Gynecol* 2006;108:879–83)

**LEVEL OF EVIDENCE: II-2**

There is increasing awareness that pelvic floor dysfunctions are highly prevalent conditions. One in every 10 women has pelvic floor dysfunction severe enough to require surgery.<sup>1</sup> The majority of these approximately 300,000 inpatient operations each year are performed for pelvic organ prolapse followed by stress urinary incontinence.<sup>2,3</sup>

There is also a growing body of evidence that the levator ani muscles are important to pelvic organ support. Previous work using magnetic resonance (MR) imaging has found levator ani defects in the pubic portion after vaginal delivery<sup>4–6</sup> and showed that levator ani defects are most common in the pubic portion.<sup>7,8</sup> The pubic portion contains muscle fibers that originate from the pubic bone and include the pubovisceral muscle and puborectal muscle.<sup>9</sup> Despite the association between prolapse and levator damage, there are women with prolapse who do not have levator damage and women with normal support who do have levator damage.<sup>10</sup> This has led some investigators to quantify levator ani muscle bulk to see if this explains the discrepancy.

Several techniques have been used to quantify muscle loss. Hoyte measured the distance from the pubic bone to the remaining muscle<sup>7</sup> as well as muscle thickness.<sup>10</sup> Levator ani muscle volume has also been quantified.<sup>7,11</sup> Our group has assessed the degree of muscle damage visible in two-dimensional (2D) images.<sup>6</sup> This later technique focuses on the amount of muscle missing but does not quantify how much muscle remains. Despite a levator injury, a woman

From the University of Michigan, Ann Arbor, Michigan.

This study was sponsored by the National Institute of Child Health and Human Development (R01 HD-38665) and the German Research Foundation (DFG, HU1502/1-1).

Corresponding author: Yvonne Hsu, 1500 East Medical Center Drive, Women's Hospital L4000, Ann Arbor, MI 48109-0276; e-mail: yvonneh@med.umich.edu.

© 2006 by The American College of Obstetricians and Gynecologists. Published by Lippincott Williams & Wilkins.

ISSN: 0029-7844/06



who started off with a larger muscle may end up with the same amount of muscle as a woman who inherently had smaller muscles. Although comparing muscle volume provides useful information about muscle loss, muscle volume does not correlate as well with force because, although a longer muscle of a given cross-sectional area has a larger volume, it will not develop more force than a shorter muscle of the same cross-sectional area. Therefore, the parameter that best predicts a muscle's potential for developing contractile force is its cross-sectional area measured perpendicularly to fiber direction.<sup>12,13</sup> Unless the MR scans happen to be acquired perpendicularly to the levator ani fiber direction, which is highly unlikely given their origin and insertions, levator muscle cross-sectional area cannot be determined from 2D scans.

The present paper uses a 3D technique for determining the cross-sectional area of the pubic portion of the levator ani muscle perpendicularly to fiber direction.<sup>14</sup> We used this method to test the hypotheses that levator ani cross-sectional area would not vary with defect severity as identified on MR scans<sup>6</sup> and then to test the hypothesis that these cross-sectional areas would not differ in women with normal support from those with pelvic organ prolapse.

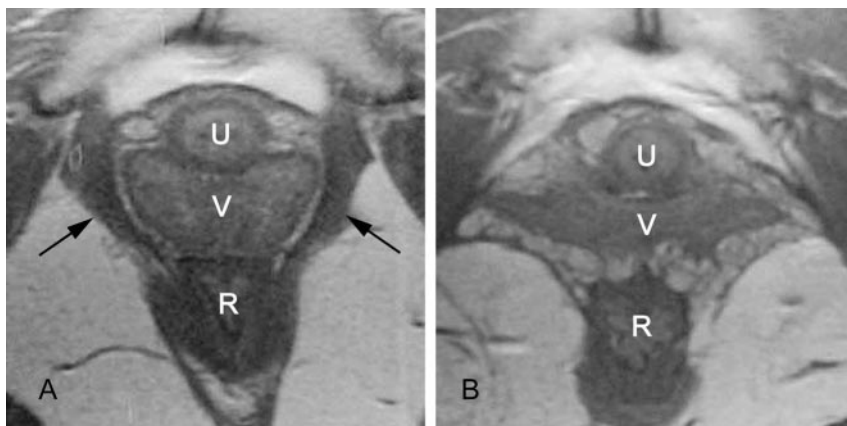
## MATERIALS AND METHODS

To perform this analysis, 60 subjects were selected from an ongoing case-control study that was approved by the University of Michigan Institutional Review Board. The case-control study compared findings in women who have normal support with women with pelvic organ prolapse between November 2000 and April 2005. Of these, 30 women had pelvic organ prolapse, as demonstrated by a vaginal wall or the cervix being at least 1 cm beyond the introitus upon supine examination during maximal Valsalva. Thirty controls, who had normal support with vaginal wall

and cervix 1 cm or more above the hymen were also selected for analysis. In both the prolapse and control group, women were selected from the parent study, with 10 women having "no levator ani defects," 10 women having "minor" defects, and 10 women having "major" defects (see below). Patients were selected such that the mean age of each group would be similar. Subjects were all white women, with the exception of one African-American woman. For the parent study, women with prolapse had been recruited from the University of Michigan Urogynecology Clinic, whereas controls were women recruited through advertisements, as well as through the Women's Health Registry, a database of women who expressed interest in participating in women's health projects. Women were excluded if they had previous surgery for prolapse or incontinence, had genital anomalies, or had delivered in the past year.

The severity of the defect in the pubovisceral portion of the levator ani muscle was determined by using MR images and a visual scoring system.<sup>6</sup> Defects were scored on each side as "0"=no defect, "1"=less than 50% muscle loss, "2"=more than 50% loss, and "3"=loss of all significant muscle (Fig. 1). Scores from both sides were added together for a summed score ranging from 0 to 6. Summed scores were then grouped into three categories: 0=no defect, 1-3=minor defect, and 4-6=major defects as previously described.<sup>6</sup>

All patients had a pelvic MR scan performed in the supine position. Multiplanar, two-dimensional, fast-spin, proton density MR images (echo time 15 ms, repetition time 4,000 ms) were obtained by using a 1.5 T superconducting magnet (General Electric Signa Horizon LX; GE Medical System, Milwaukee, WI) with version 9.1 software. The axial and coronal fields of view were each 16×16 cm, whereas the sagittal



**Fig. 1.** Axial magnetic resonance image showing the levator ani. **A.** Intact pubovisceral muscle bilaterally as demonstrated by arrows. **B.** Complete loss of bilateral muscles. U, urethra; V, vagina; R, rectum. © DeLancey 2006.

Hsu. Quantification of Levator Ani Cross-Sectional Area. *Obstet Gynecol* 2006.



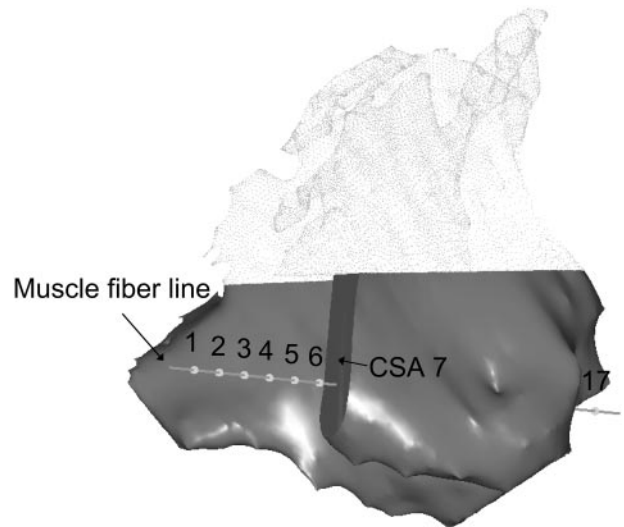
images were 20×20 cm. All three views had slice thicknesses of 4 mm with a 1 mm gap between slices.

Axial, sagittal, and coronal MR images were imported into a 3D imaging program (3D Slicer.v.2b1, Brigham and Women's Hospital, Boston, MA) and aligned using anatomic landmarks. Three-dimensional volume-rendering models were generated from axial and coronal planes (Fig. 2) and then imported into I-DEAS 9.0 (UGS, Plano, TX), an engineering graphics program, to perform measurements.

The pubic portion of the levator ani muscle was separated from the iliococcygeal portion by establishing a dividing plane through three anatomical landmarks that could be identified independently of the presence or absence of a muscle defect, as previously described (middle landmark: upper aspect of puborectalis; lateral landmarks: medial origins of the iliococcygeus from the arcus tendineus levator ani).<sup>14</sup> The muscle fiber direction is not directly observable on the MR scans, so it was approximated by establishing a line between the middle of the origin point and the center of the insertions using anatomic landmarks.<sup>14</sup> Using I-DEAS, cross-sectional areas of the pubic portion were calculated perpendicularly to a fiber direction line, from the pubic origin to the middle of the visceral insertion at 17 equidistant points (Fig. 3). A 2-by-3 analysis of variance was performed and then one-way analysis of variance was performed for each factor.  $P < .05$  was considered significant. A power calculation was not possible at the beginning of the study because no data were available concerning these measurements. Therefore, a post hoc power calculation was performed.

## RESULTS

Patient demographics are presented in Table 1. There was no significant difference in body mass index (BMI) between women with and those without pro-

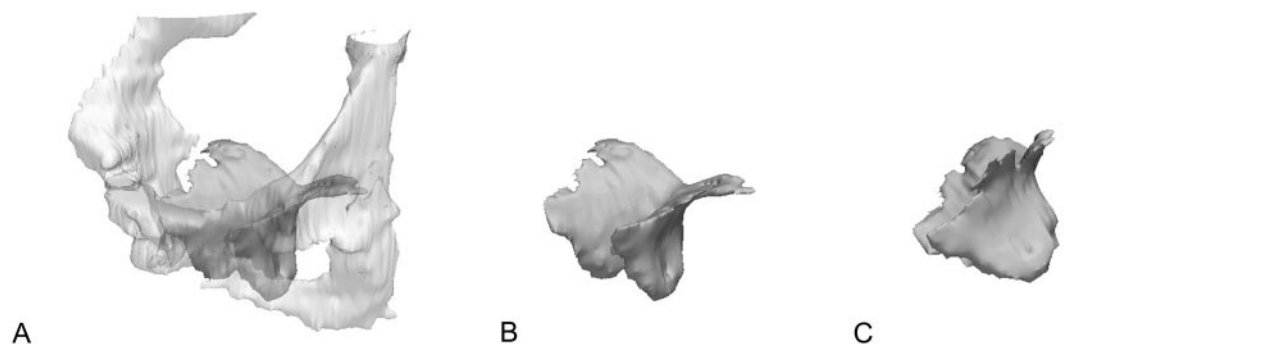

**Fig. 3.** Levator model and cross-sections. Fiber direction line for the left side of pubic portion of levator ani muscle is shown. The locations of cross-section areas (CSA) are shown and numbered from 1 (most ventral) to 17 (most dorsal). The model has been cut at CSA 7. Cross-section areas 8 to 16 are not numbered in the figure. © DeLancey 2006.

*Hsu. Quantification of Levator Ani Cross-Sectional Area. Obstet Gynecol 2006.*

lapse (mean BMI: prolapse=27.16 kg/m<sup>2</sup>, controls=25.92 kg/m<sup>2</sup>,  $P=.269$ ). The maximum pelvic organ prolapse quantification (POP-Q) point is also shown, which represents the most dependent vaginal wall point. In all patients with prolapse, the vaginal wall or cervix was 1 cm or more below the hymeneal ring. Of the 30 patients with prolapse, the majority had anterior compartment prolapse ( $n=25$ ), while three patients had posterior compartment prolapse, and two had apical prolapse.

The 2-by-3 analysis of variance showed that at locations 2–8 and 13–14, levator defect status was a



**Fig. 2.** 3D Slicer models. **A.** Three-fourths view of the levator ani muscle and pubic bone. **B.** Levator ani with pubic bones removed. **C.** Lateral view of muscle. © DeLancey 2006.

*Hsu. Quantification of Levator Ani Cross-Sectional Area. Obstet Gynecol 2006.*



**Table 1. Patient Demographics**

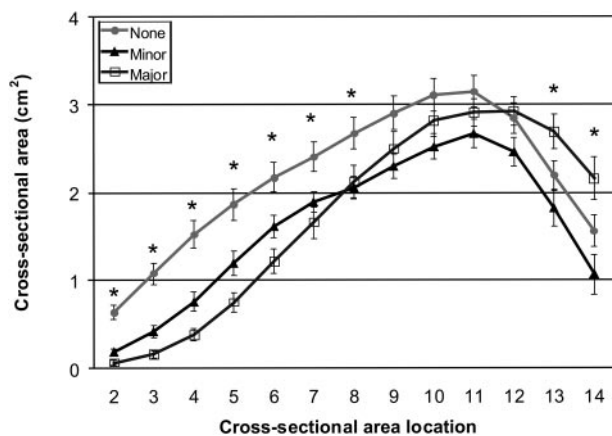
Defect Status	Group Status	Age (y)	Vaginal Parity	BMI (kg/m <sup>2</sup> )	Maximum POP-Q (cm)
None	Normal	63±2.4	2.8±0.3	23.7±0.6	-1.2±0.1
	Prolapse	62±3.1	2.7±0.5	29.5±1.4	+1.9±0.4
Minor	Normal	60.6±2.5	2.5±0.6	25.9±1.5	-1.5±0.2
	Prolapse	61.5±1.9	4.6±0.7	25.3±1.1	+2.6±0.3
Major	Normal	60.4±2.8	2.9±0.5	28.2±1.3	-1.2±0.1
	Prolapse	62.3±3.5	3.7±0.7	26.7±1.4	+2.5±0.5

BMI, body mass index; POP-Q, pelvic organ prolapse quantification. Data are expressed as mean±standard error of the mean.

significant factor ( $P<.05$ ). Prolapse appeared to be nonsignificant at all locations.

The mean cross-sectional areas at each location are shown in Figure 4. In locations 2–7, the women with major defects had the smallest cross-sectional area, followed by those with minor defects. These cross-sectional locations represent where the muscle originates from the pubic bone. We designated locations 2–10 as the ventral portion of the muscle based their locations on our 3D models. The mean (±standard error of the mean) cross-sectional area values for areas 2–10 taken as a group were as follows: no defects, 2.04±0.16 cm<sup>2</sup>; minor defects, 1.44±0.11 cm<sup>2</sup>; and major defects, 1.30±0.12 cm<sup>2</sup> ( $P<.001$ ). A post hoc power calculation revealed that the current sample size had 96% power to detect a cross-sectional area difference between the different defect status groups in the ventral portion.

In the dorsal portion of the muscle, at cross-section locations 11–14, where the fibers of the sling



**Fig. 4.** Levator cross-section areas at various locations (mean±standard error of the mean). \*Locations where 2-by-3 analysis of variance showed that levator defect status was a significant factor ( $P<.05$ ). For display purposes, locations 1 and 14–17 are not shown.

Hsu. Quantification of Levator Ani Cross-Sectional Area. *Obstet Gynecol* 2006.

of the puborectal muscle predominate behind the rectum, the women with major defects had the largest cross-sectional area compared with the minor or no-defect groups (no-defect group, 2.43±0.13 cm<sup>2</sup>; minor defect, 2.00±0.17 cm<sup>2</sup>; and major defect, 2.67±0.20 cm<sup>2</sup>;  $P=.03$ ).

The cross-sectional areas of the pubic portion of the levator muscle in women with prolapse and those with normal support in each defect grade are compared in Table 2. Within each group, (normal, minor, major) when the patients were divided according to prolapse status, there were no statistically significant differences in the cross-sectional area in either the ventral or dorsal regions.

## DISCUSSION

It is noteworthy that women with major defects exhibited a 36% reduction in cross-sectional area in the ventral portion of the levator ani muscle compared with women without defects, whereas in the posterior portion of the muscle, women with major defects exhibited a 9% larger cross-sectional area compared with those without defects. Although women with minor defects similarly exhibited a 29% smaller cross-sectional area in the ventral portion of the muscle compared with those with no defects ( $P<.001$ ), they had a smaller cross-section in the dorsal portion of the muscle.

The finding of smaller cross-sectional area in the ventral portion based on severity of visible defects on MR images reinforces the hypothesis that defects in the

**Table 2. Cross-Sectional Areas in Women With and Those Without Prolapse**

	Ventral (cm <sup>2</sup> )			Dorsal (cm <sup>2</sup> )		
	Prolapse	Normal	P	Prolapse	Normal	P
None	1.97±0.29	2.11±0.14	.65	2.32±0.25	2.55±0.11	.40
Minor	1.51±0.20	1.36±0.09	.52	2.00±0.25	2.00±0.26	.99
Major	1.34±0.21	1.25±0.12	.73	2.67±0.34	2.66±0.24	.98

Data are expressed as mean±standard error of the mean.





levator ani is localized to this area.<sup>4,5</sup> This region is where the pubovisceral or pubococcygeal muscles (pubovaginal muscle, puboanal muscle, and puboperineal muscle) predominate. Comparing cross-sectional area of the muscle between the groups begins the process of using morphological differences to explain differences in muscle function. For a parallel-fibered, nonpennate muscle, the smaller the cross-sectional area, the smaller the maximal force a muscle can generate.

What might explain the paradoxical finding of increased muscle cross-sectional area in the dorsal region of the pubic portion in women with severe defects? In this region, the fibers of the puborectalis muscle predominate and form a sling behind the rectum.<sup>9,15</sup> The increased cross-sectional area could represent compensatory hypertrophy. Alternatively, this increased posterior cross-sectional area may represent disrupted muscle that has retracted dorsally, but if this muscle has retracted because of detachment of its origin or insertion, atrophy should have occurred within months of the injury. Further research will be needed to clarify these newly identified issues.

In both ventral and dorsal regions of the pubic portion of the levator ani muscle, cross-sectional area measurements did not show statistically significant differences when women with prolapse were compared with women having normal support for each level of defect. This does not mean that muscle defects are unimportant to the occurrence of prolapse because muscle defects happen more often in the ventral levator ani of women with prolapse,<sup>10</sup> and differences in levator ani morphology have been observed between women with prolapse and normal support.<sup>7,8</sup> However, when defects are present, the amount of muscle is the same regardless of whether there is prolapse or not. In other words, a woman with prolapse and a defect in the levator ani muscle had a levator cross-sectional area similar to a woman with a similar severity of levator defect, but normal support. This is logical because the pelvic organ support system consists of connective tissue, striated muscle, and smooth muscle. Therefore, damage in any one of these systems will not explain all occurrences of prolapse.

This study quantified differences in levator ani muscle cross-sectional area perpendicular to the fiber direction in different patient populations. It should help investigators assess the biomechanical role of levator ani muscle loss in causing pelvic organ prolapse. The difference in cross-sectional area in the ventral and dorsal regions of the muscle indicates that the levator ani muscle is affected in a nonuniform manner, consistent with the fact that the levator ani is composed of several different component muscles<sup>9</sup>

that are differentially affected by damage. Specific patterns of damage to specific muscle elements may be important for the development of pelvic floor dysfunction. In addition, the predominance of anterior compartment prolapse in this analysis may not make the results applicable to prolapse in the other compartments. Further research will be needed to see if specific muscle elements may be important for the development of different types of pelvic floor dysfunction.

## REFERENCES

1. Olsen AL, Smith VJ, Bergstrom JO, Colling JC, Clark AL. Epidemiology of surgically managed pelvic organ prolapse and urinary incontinence. *Obstet Gynecol* 1997;89:501-6.
2. Boyles SH, Weber AM, Meyn L. Procedures for pelvic organ prolapse in the United States, 1979-1997. *Am J Obstet Gynecol* 2003;188:108-15.
3. Boyles SH, Weber AM, Meyn L. Procedures for urinary incontinence in the United States, 1979-1997. *Am J Obstet Gynecol* 2003;189:70-5.
4. DeLancey JO, Kearney R, Chou Q, Speights S, Binno S. The appearance of levator ani muscle abnormalities in magnetic resonance images after vaginal delivery. *Obstet Gynecol* 2003; 101:46-53.
5. Dietz HP, Lanzarone V. Levator trauma after vaginal delivery. *Am J Obstet Gynecol* 2005;106:707-12.
6. Kearney R, Miller JM, Ashton-Miller JA, DeLancey JOL. Obstetric factors associated with levator ani muscle injury after vaginal birth. *Obstet Gynecol* 2006;107:144-9.
7. Hoyte L, Fielding JR, Versi E, Mamisch C, Kolvenbach C, Kikinis R. Variations in levator ani volume and geometry in women: the application of MR based 3D reconstruction in evaluating pelvic floor dysfunction. *Arch Esp Urol* 2001;54: 532-9.
8. Singh K, Jakab M, Reid WMN, Berger LA, Hoyte L. Three-dimensional magnetic resonance imaging assessment of levator ani morphologic features in different grades of prolapse. *Am J Obstet Gynecol* 2003;188:910-5.
9. Kearney R, Sawhney R, DeLancey JO. Levator ani muscle anatomy evaluated by origin-insertion pairs. *Obstet Gynecol* 2004;104:168-73.
10. Hoyte L, Jakab M, Warfield SK, Shott S, Flesh G, Fielding JR. Levator ani thickness variations in symptomatic and asymptomatic women using magnetic resonance-based 3-dimensional color mapping. *Am J Obstet Gynecol* 2004;191:856-61.
11. Fielding JR, Dumanli H, Schreyer AG, Okuda S, Gering DT, Zou KH, et al. MR-based three-dimensional modeling of the normal pelvic floor in women: quantification of muscle mass. *Am J Radiology* 2000;174:657-60.
12. Ikai M, Fukunaga T. Calculation of muscle strength per unit cross-sectional area of human muscle by means of ultrasonic measurement. *Int Z Angew Physiol* 1968;26:26-32.
13. Ikai M, Fukunaga T. A study on training effect on strength per unit cross-sectional area of muscle by means of ultrasonic measurement. *Int Z angew Physiol* 1970;28:173-180.
14. Chen L, Hsu Y, Ashton-Miller JA, DeLancey JOL. Measurement of the pubic portion of the levator ani muscle in women with unilateral defects in 3D models from MR images. *Int J Gynaecol Obstet* 2006;92:234-41.
15. Lawson JO. Pelvic anatomy. I. Pelvic floor muscles. *Ann R Coll Surg Engl* 1974;54:244-52.

