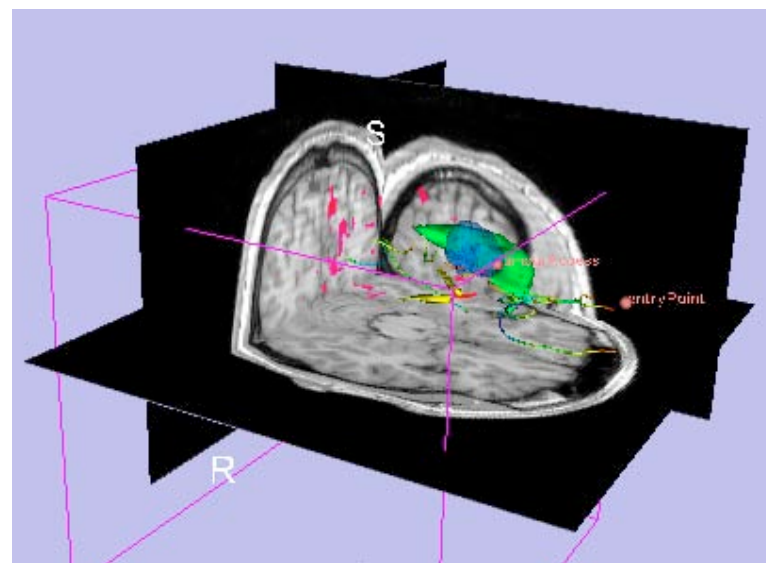




Image Guided Therapy in Slicer3

Planning for Image Guided
Neurosurgery

Danielle Pace, B.CmpH





Acknowledgements



National Alliance for Medical Image Computing



Surgical Planning Lab, Harvard Medical School

Nobuhiko Hata, Steve Pieper, Ron Kikinis, Haiying Liu, Sonja Pujol, Randy Gollub, Rodrigo de Luis Garcia, Carl-Fredrik Westin

(any more people to thank? Or perhaps some of these people go with different logos? Neuroimage analysis center or Laboratory of Mathematics in Imaging?)

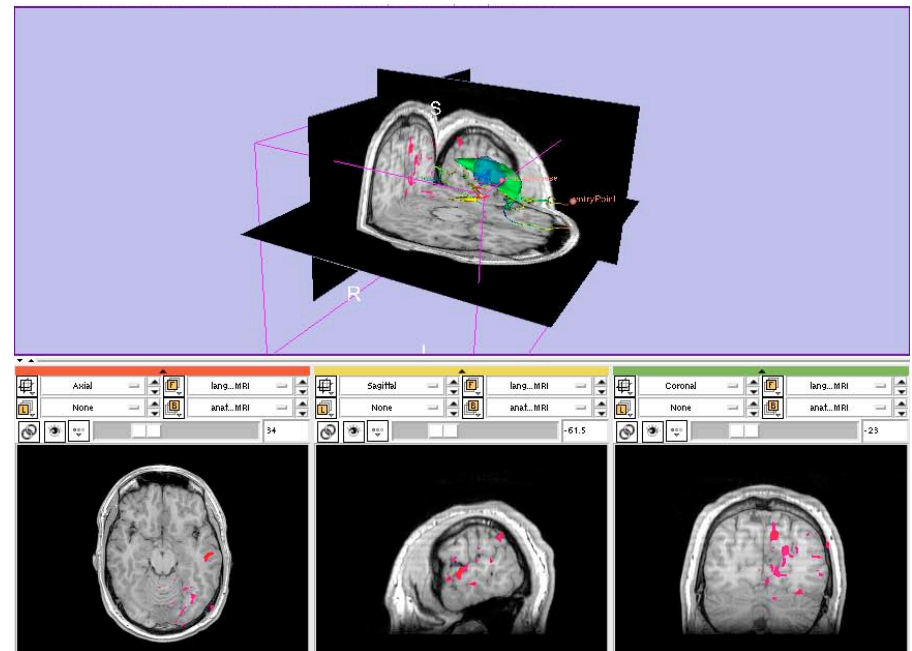
GRANTS?



Learning objectives

Following this tutorial, you will be able to perform all of the steps involved in preoperative planning for image guided neurosurgery within Slicer3, including:

- image registration
- model making
- DTI tractography





Material

This course requires the installation of the Slicer3 software and the training datasets accessible at the following locations:

- Slicer3 software and building instructions:
<http://www.slicer.org/pages/Downloads>
- Patient dataset:
[URL TBA](#)
- SPL-PNL brain atlas:
http://www.na-mic.org/pages/Special:PubDB_View?dspaceid=1265
- Two pre-computed MRML scenes:
[URL TBA](#)

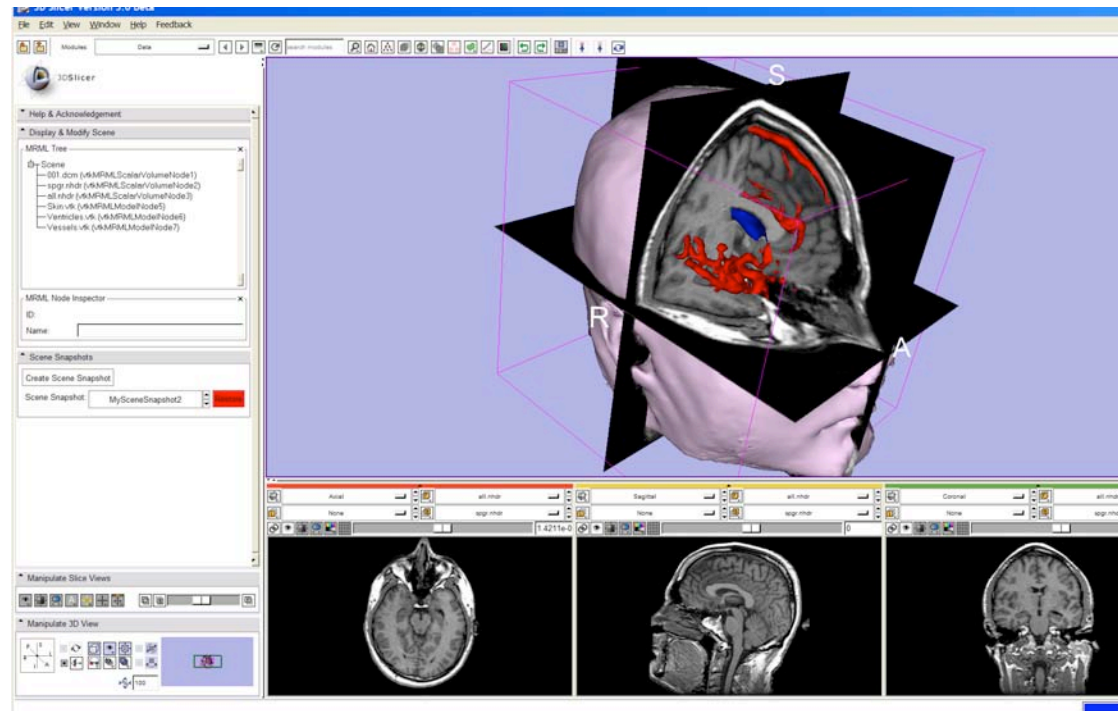
Disclaimer: It is the responsibility of the user of 3D Slicer to comply with both the terms of the license and with the applicable laws, regulations and rules.



Prerequisites

- Data Loading and Visualization in Slicer3:

http://wiki.na-mic.org/Wiki/index.php/Slicer:Workshops:Slicer3_Training





3D Slicer

- Integrates algorithms and utilities for medical image computing research and Image Guided Therapy into a single framework
- Is both an end-user application and a platform for research
- The precompiled program and the source code are both freely downloadable

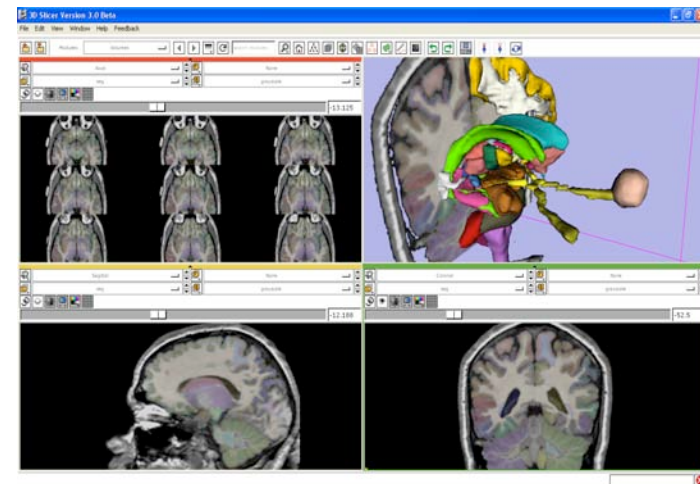
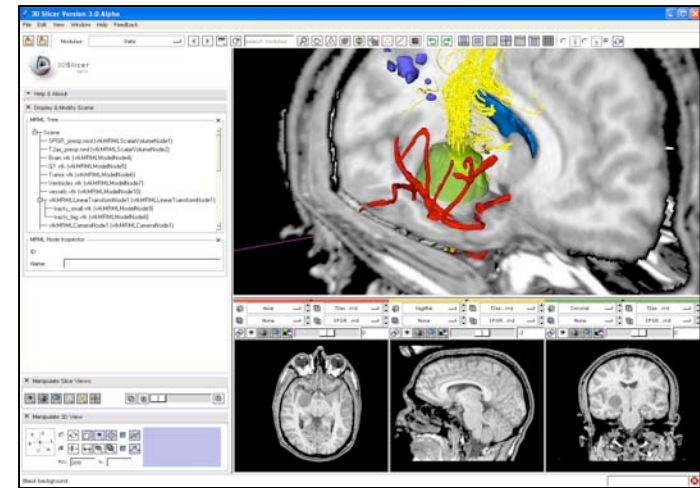




Image Guided Therapy (IGT) in Slicer3

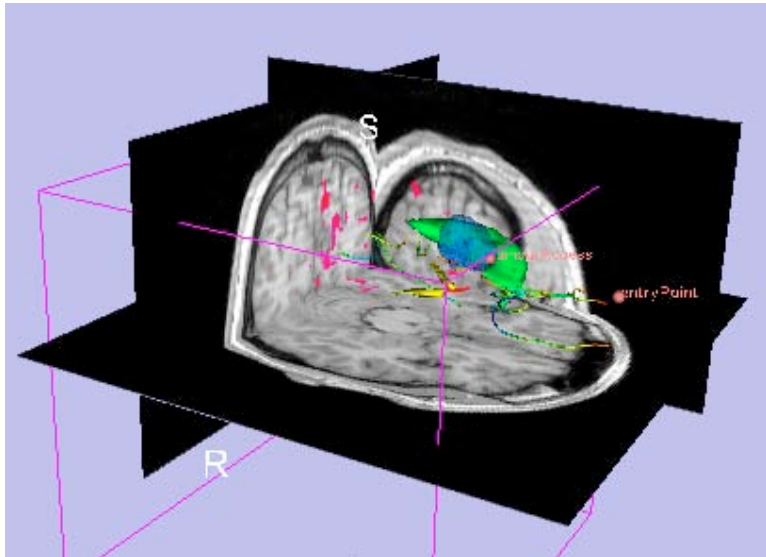
Slicer3 has extensive support for IGT, including:

- Visualization
- Registration
- Segmentation
- Model making
- Diffusion Tensor Imaging
- Quantification
- Filtering
- Interfacing to imaging devices, trackers and medical robots

**Focus of
this tutorial**



The goal of neurosurgical planning



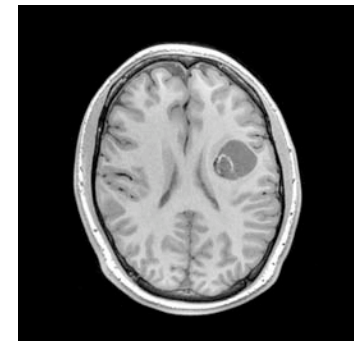
- Prior to surgery:
 - Integrate image information from multiple sources, including anatomical MRI, functional MRI and diffusion tensor imaging
 - Highlight structures of interest
 - Determine the best surgical approach



Clinical Case - brain tumour resection

- Imaging showed a large lesion in the left frontal region of the brain, predicted to be a glioma (brain tumour originating from glial cells)
- Preoperative imaging included 3D SPGR, T2-weighted and FLAIR MRI imaging, language and motor functional MRI (fMRI) imaging, and diffusion tensor imaging (DTI)
- fMRI showed speech areas close to the lesion
- Surgical procedure: left frontal craniotomy and tumour resection

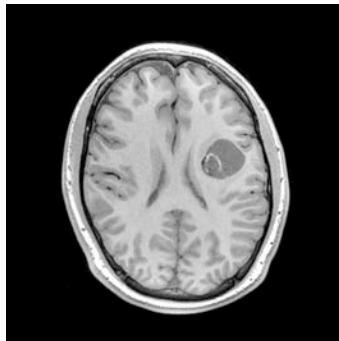
See the [clinical_background](#) file within the patient dataset for more information



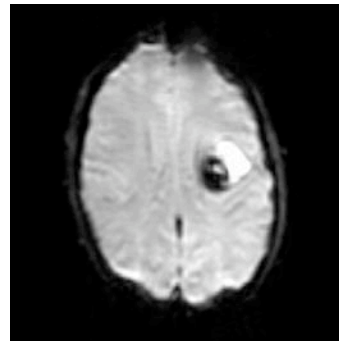


Tutorial datasets

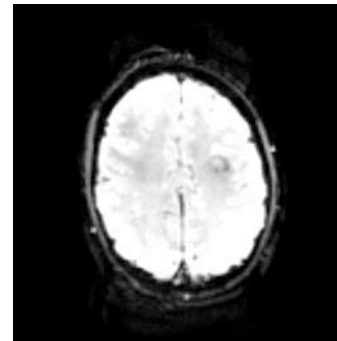
- Four clinical datasets from a single patient with a large tumour in the left frontal region:



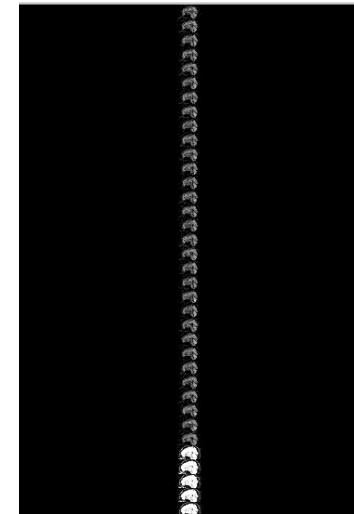**SPGR MRI
(anatomical)**



**Language
fMRI**

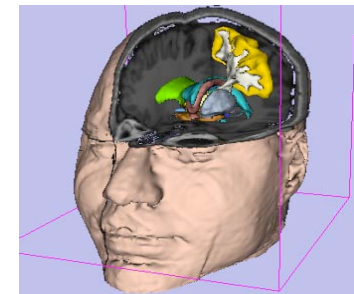


**Motor
fMRI**



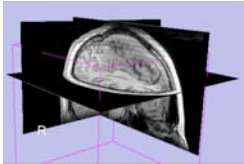
DTI

- The SPL-PNL brain atlas, based on a single healthy patient

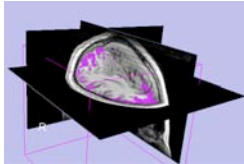




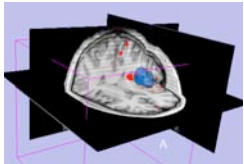
Overview



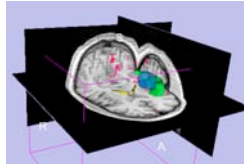
1. **Loading and visualizing anatomical MRI data**



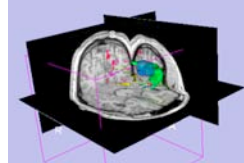
2. Incorporating fMRI data using image registration and thresholding



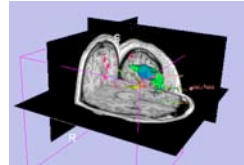
3. Creating a 3D model of the tumour volume



4. Predicting the locations of brain structures using image registration and a brain atlas



5. Incorporating brain fiber tractography from diffusion weighted images



6. Annotating the preoperative plan and saving the scene



Anatomical imaging

- **Utility of anatomical imaging in IGT:**
 - Visualize brain structures of interest, such as the lesion
 - Perform measurements on structures of interest
 - Provide context for the rest of the scene



Anatomical imaging

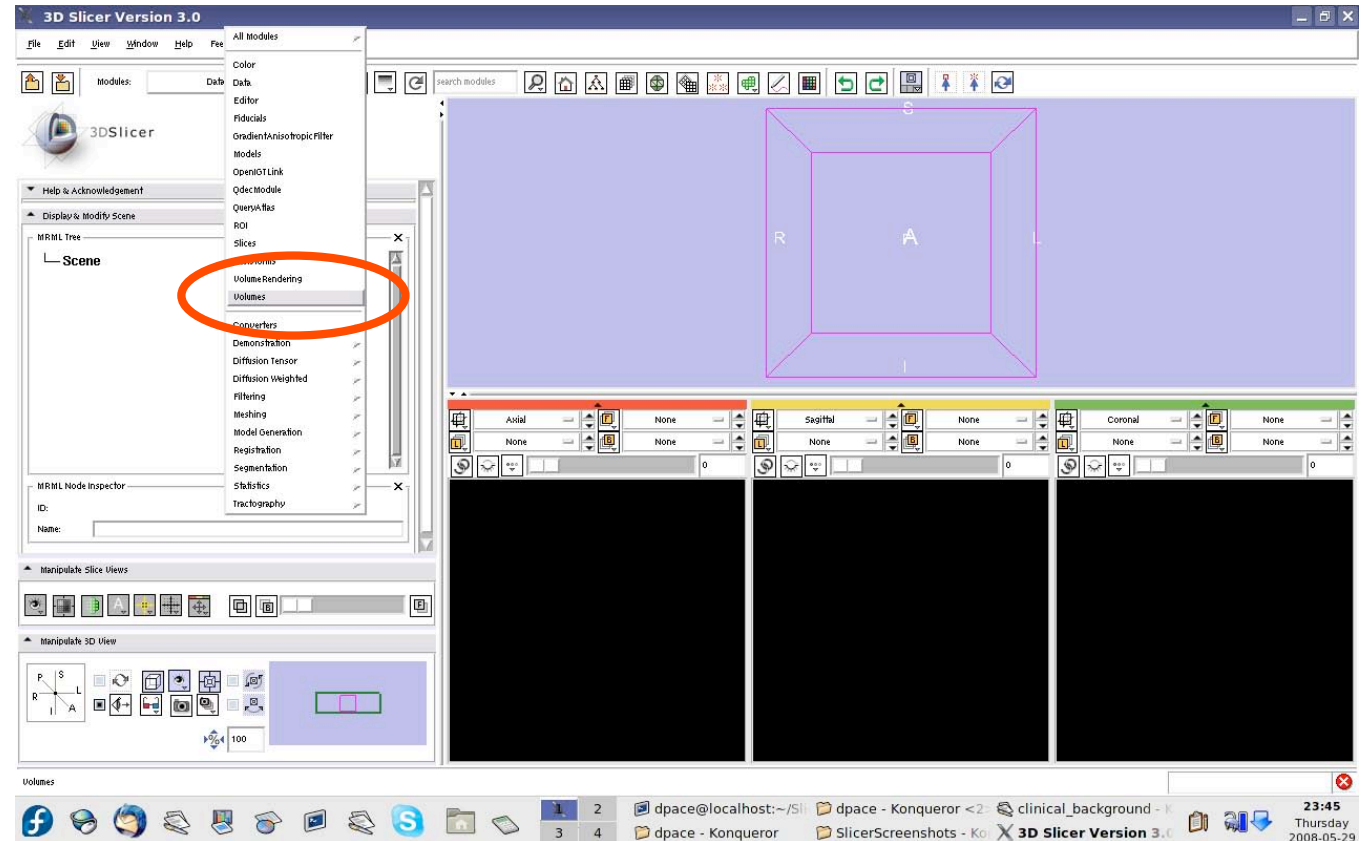
- **Steps involved in this section:**

Load anatomical MRI from patient dataset



Load the anatomical MRI data

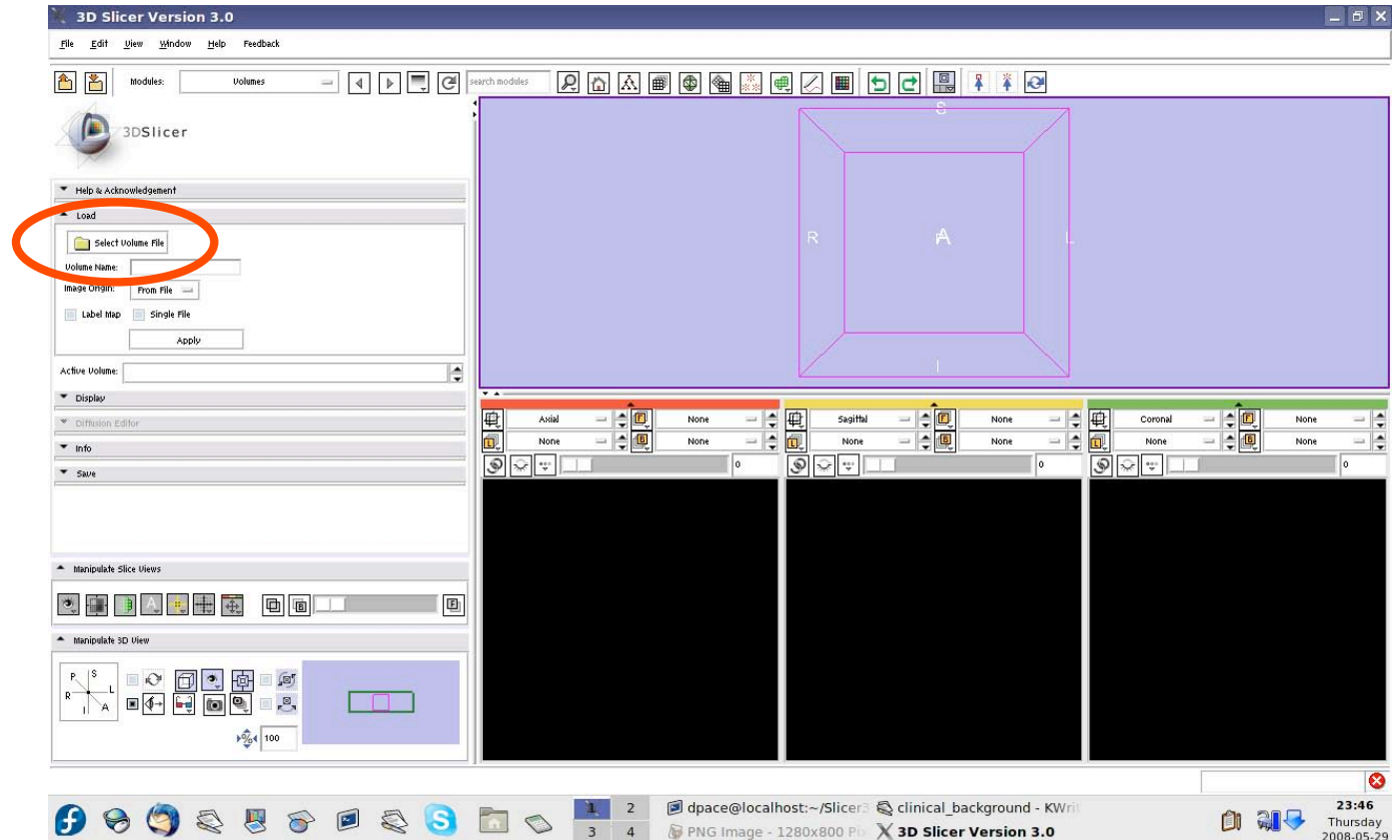
Open the
Volumes
module





Load the anatomical MRI data

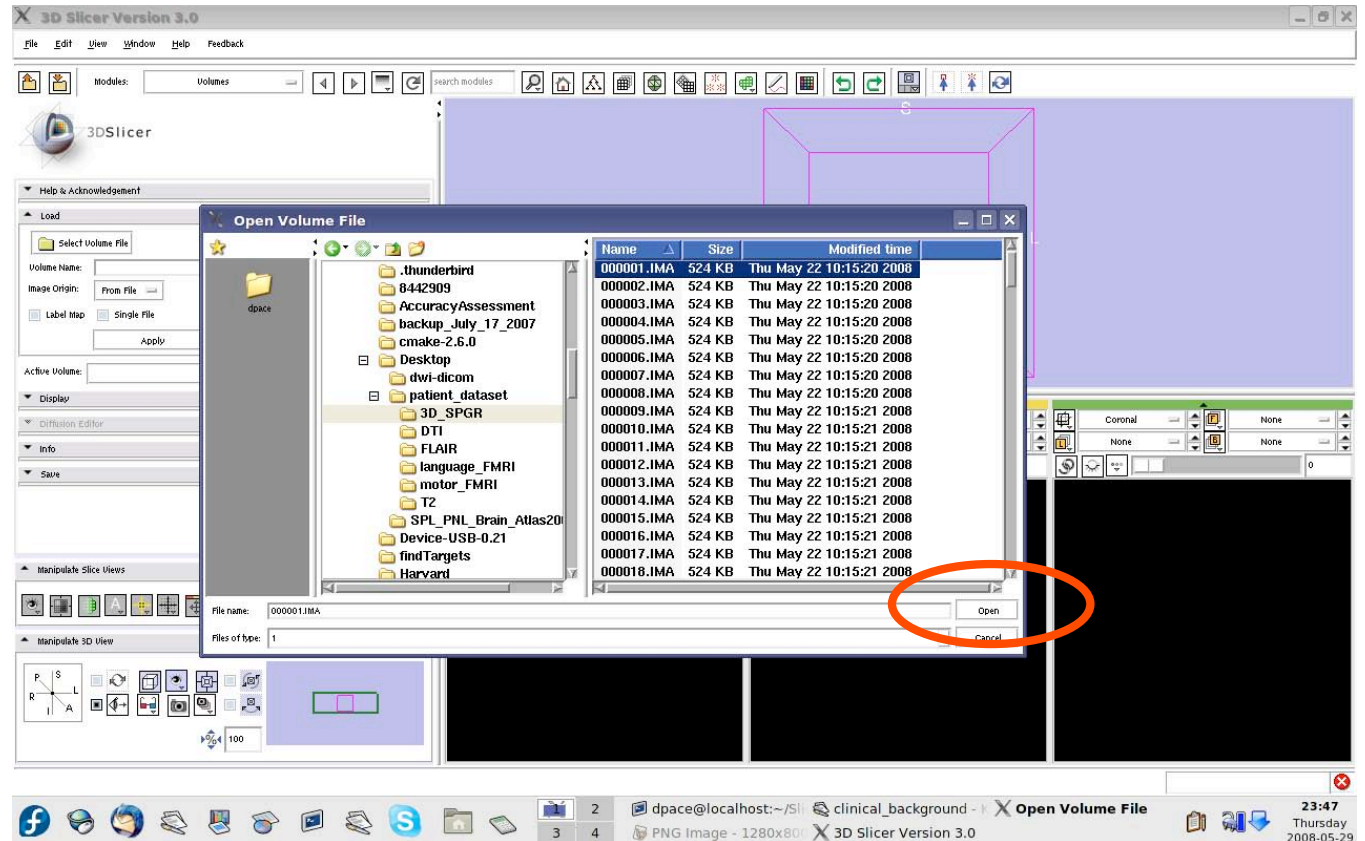
Click on
“Select
Volume File”





Load the anatomical MRI data

Click on the first image in the 3D_SPGR folder of the patient dataset, then click “Open”

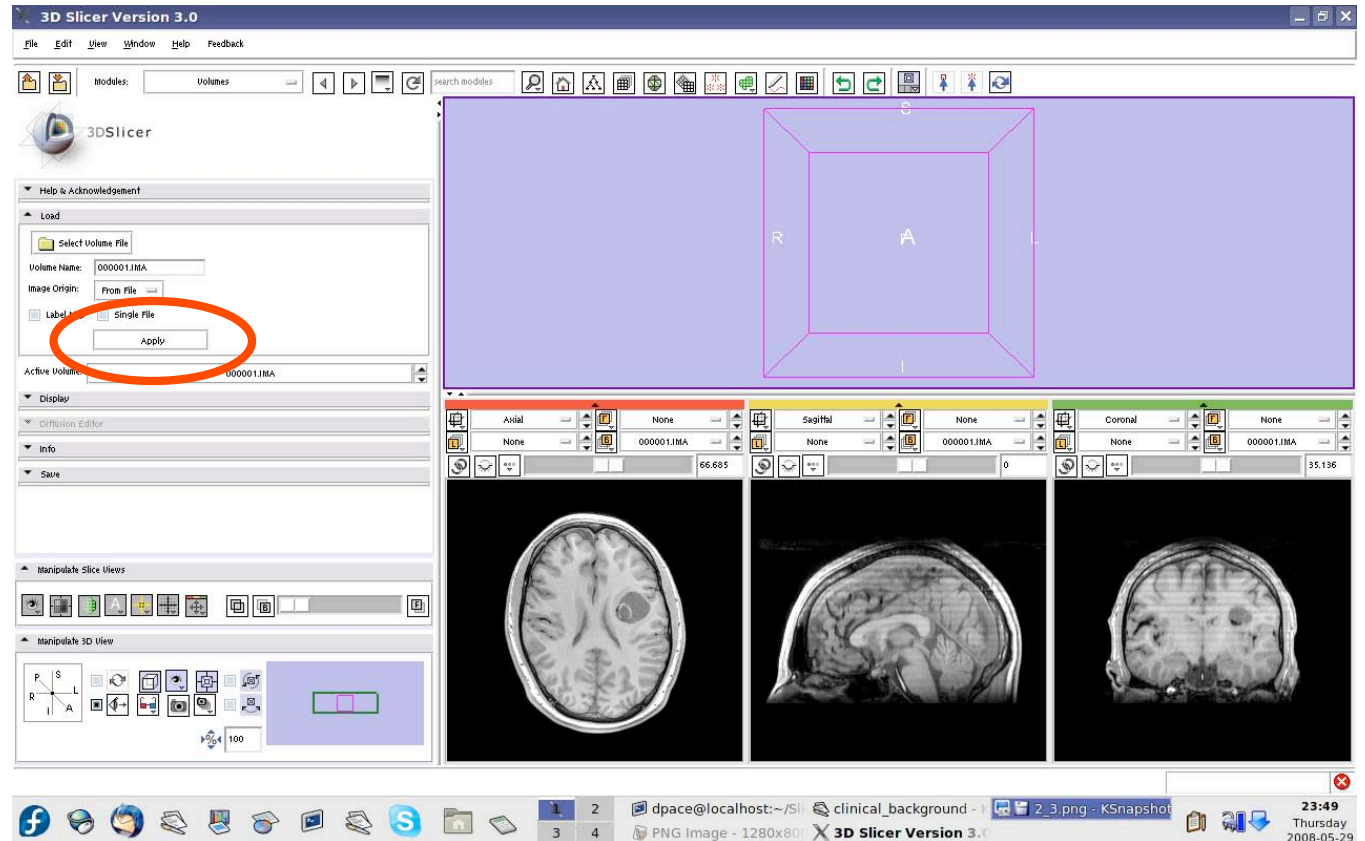




Load the anatomical MRI data

Keep the image origin set to “From File”

Click on “Apply” to load the image volume





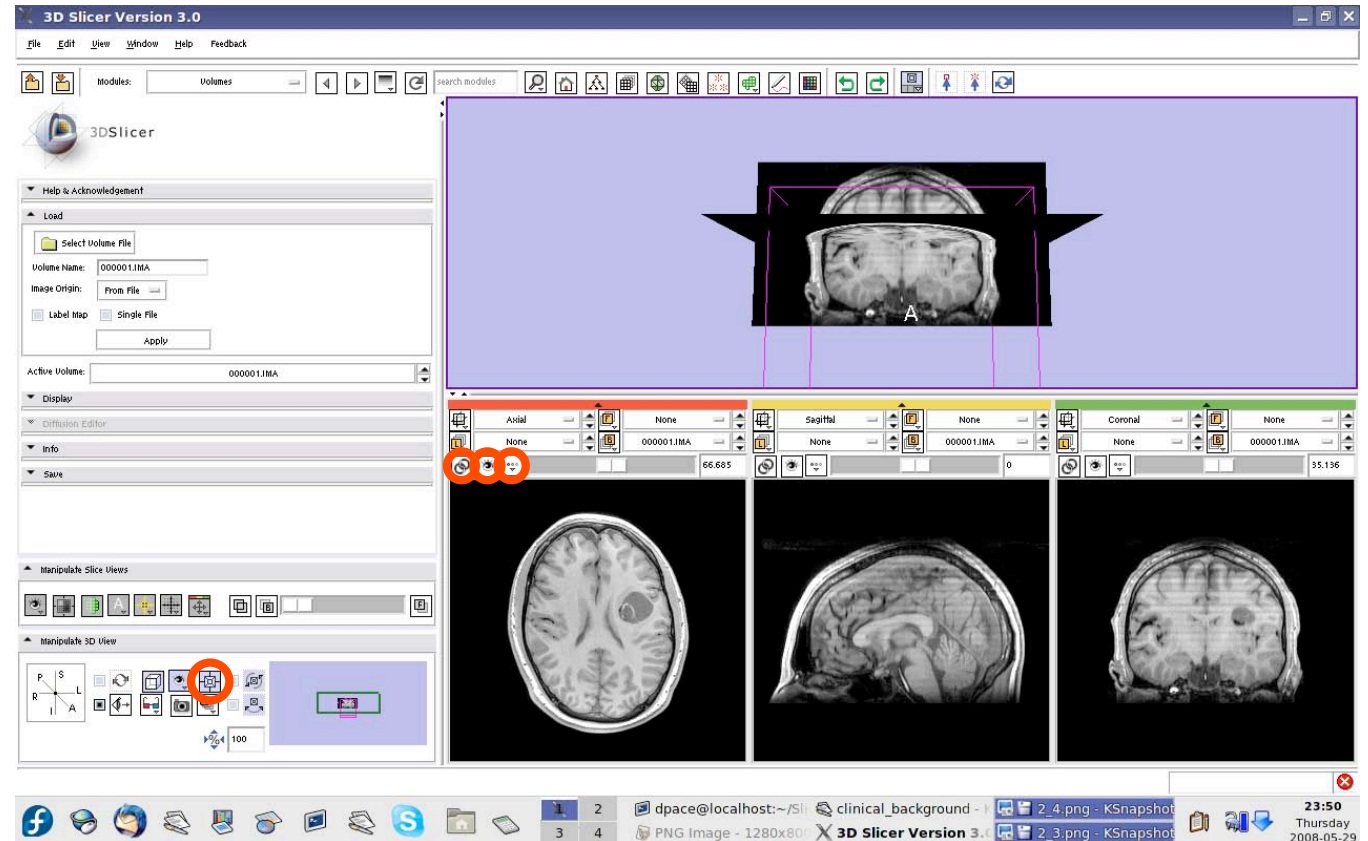
Load the anatomical MRI data

Click on the “link” button

Click on the “visibility” button

Click on the “fit to window” button

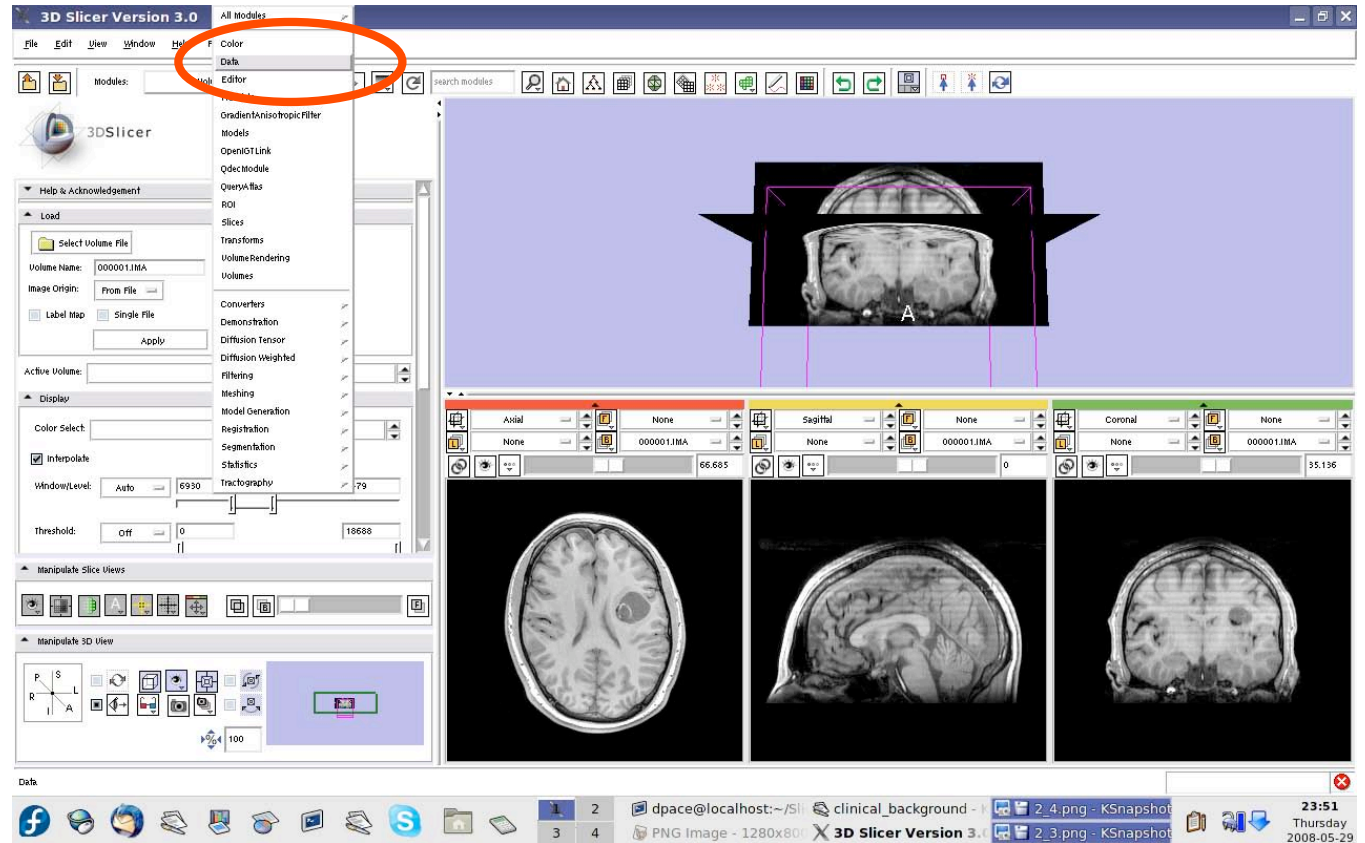
Click on the “center 3D view” button





Load the anatomical MRI data

Open the Data module

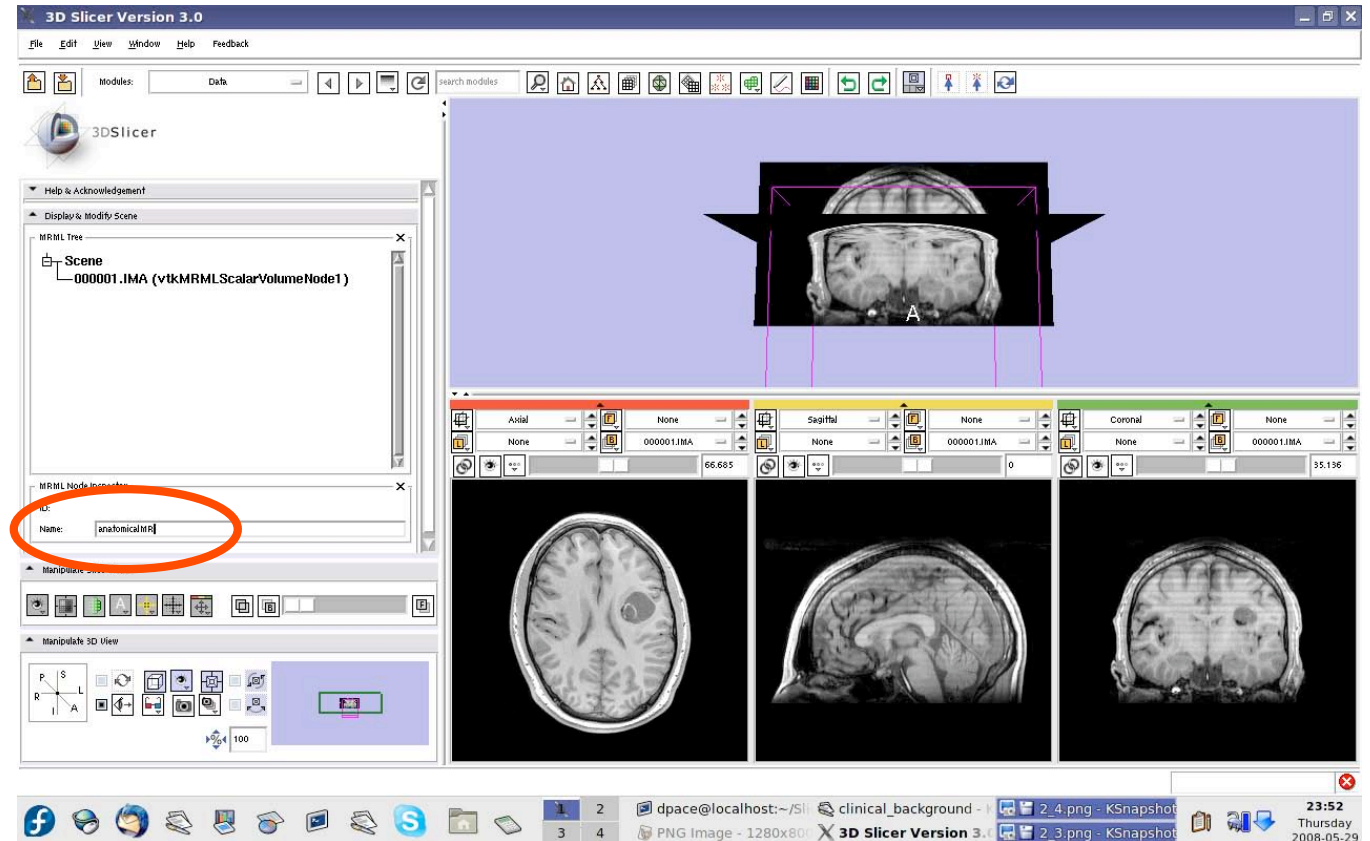




Load the anatomical MRI data

Click on the 00001.IMA node

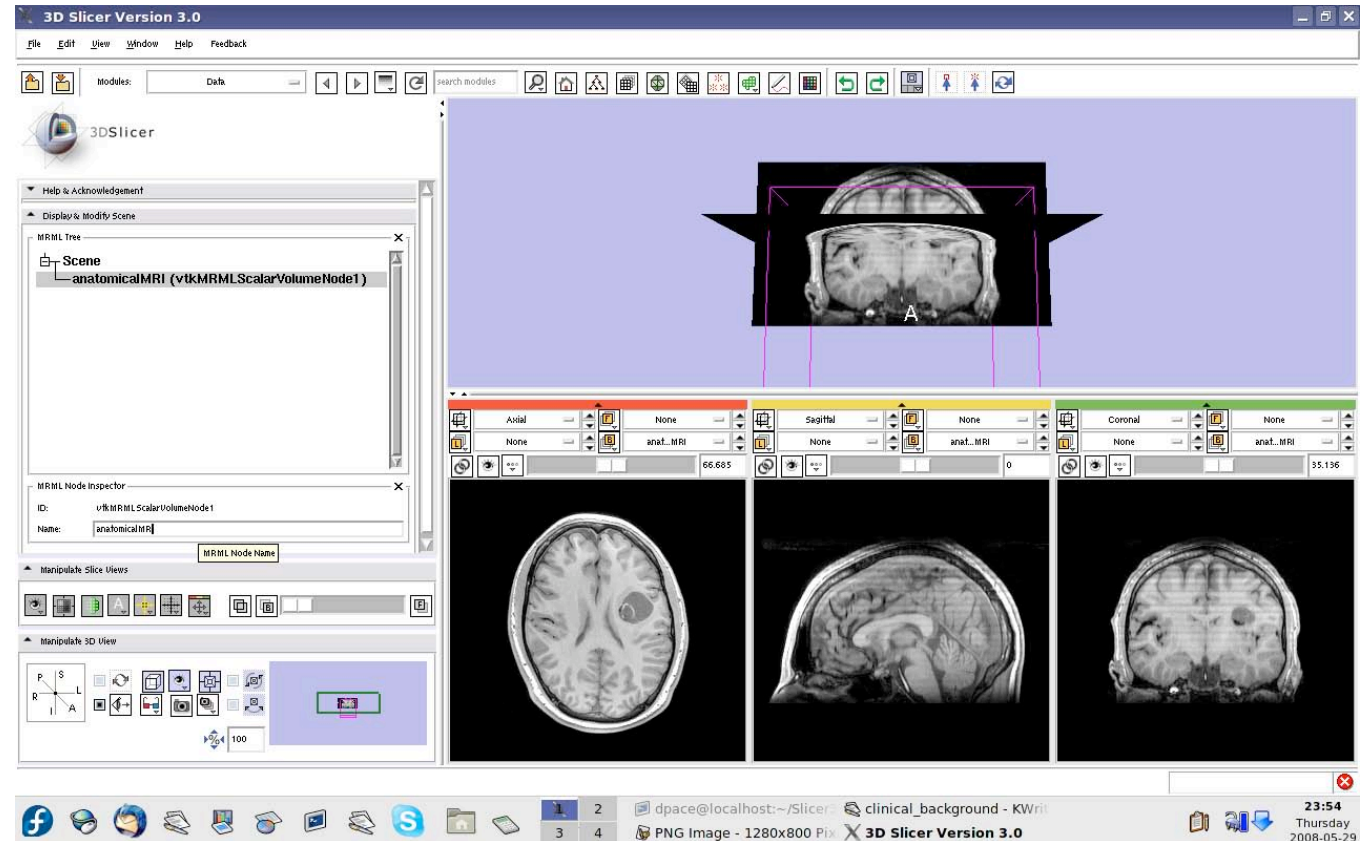
Change the name of the MRML node to “anatomical-MRI” and press Enter





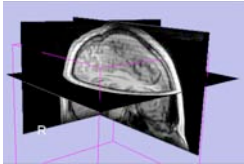
Load the anatomical MRI data

Observe that the name of the node is changed in the MRML tree

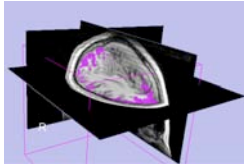




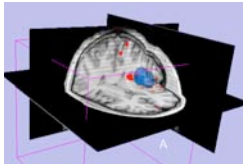
Overview



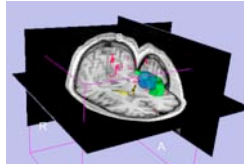
1. Loading and visualizing anatomical MRI data



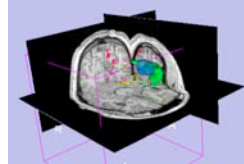
2. Incorporating fMRI data using image registration and thresholding



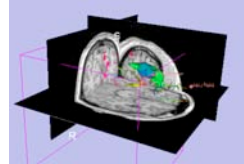
3. Creating a 3D model of the tumour volume



4. Predicting the locations of brain structures using image registration and a brain atlas



5. Incorporating brain fiber tractography from diffusion weighted images



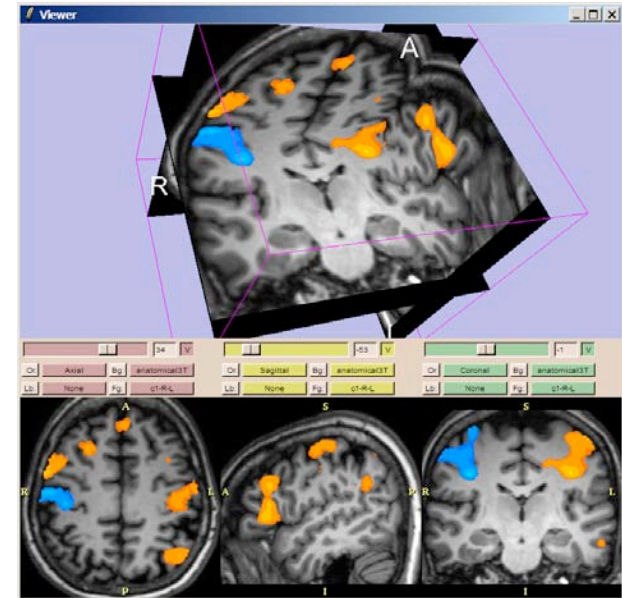
6. Annotating the preoperative plan and saving the scene



Functional MRI (fMRI)

- **fMRI:**
 - Measures the blood oxygen level in each part of the brain while the patient performs a task, such as a speech or motor task
 - Statistical techniques are used determine which brain regions are active during the task
 - This statistical pre-processing has already been done using SPM

[\(http://www.fil.ion.ucl.ac.uk/spm/\)](http://www.fil.ion.ucl.ac.uk/spm/)



SPM



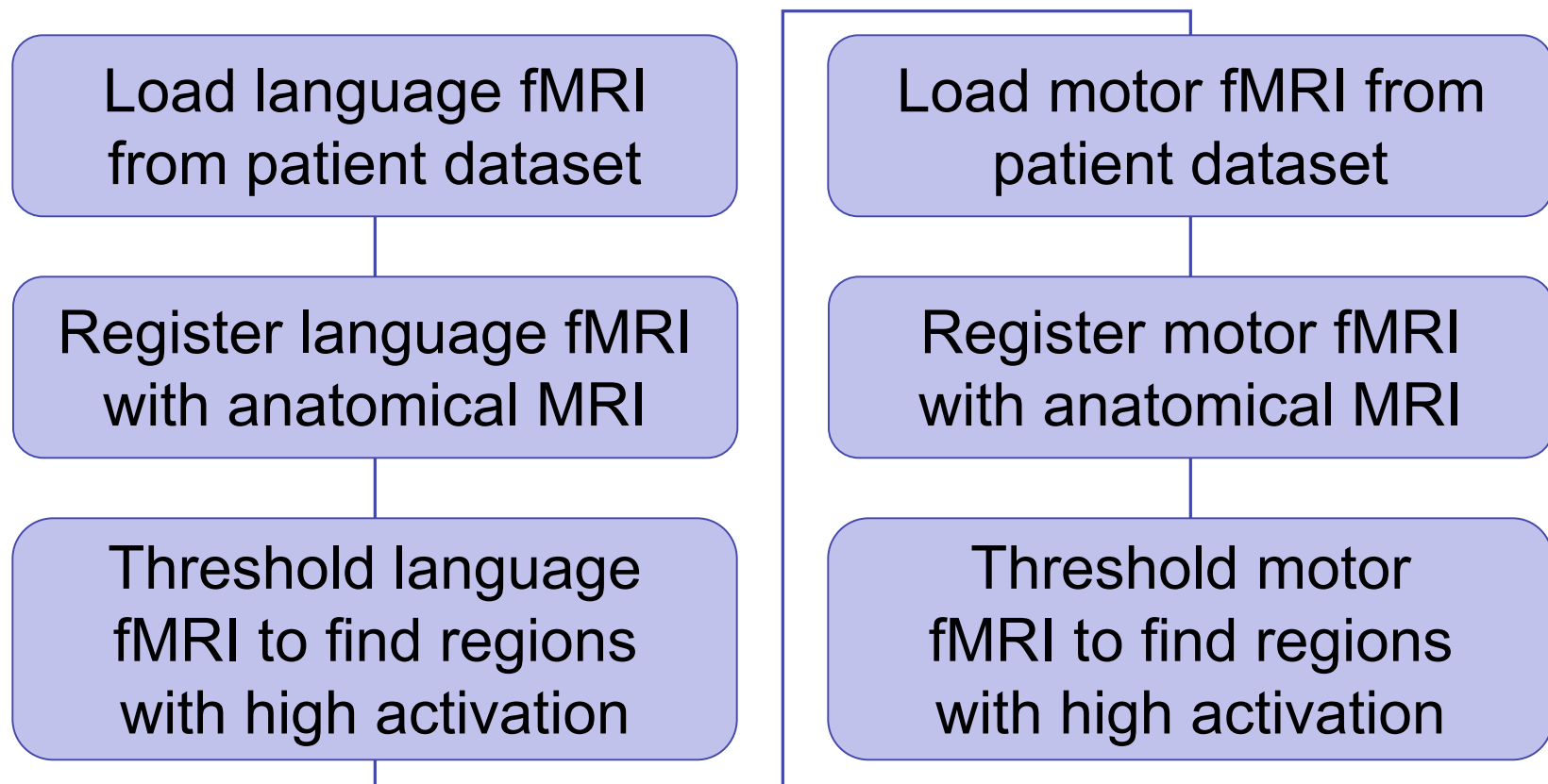
Functional MRI (fMRI)

- **Utility of functional MRI in IGT:**
 - Damaging brain regions that are active during speech or motor tasks during the surgery may reduce or eliminate the patient's ability to speak or move
 - Knowing where these regions are allows us to modify our surgical plan so that we avoid them (as much as possible)



Functional MRI (fMRI)

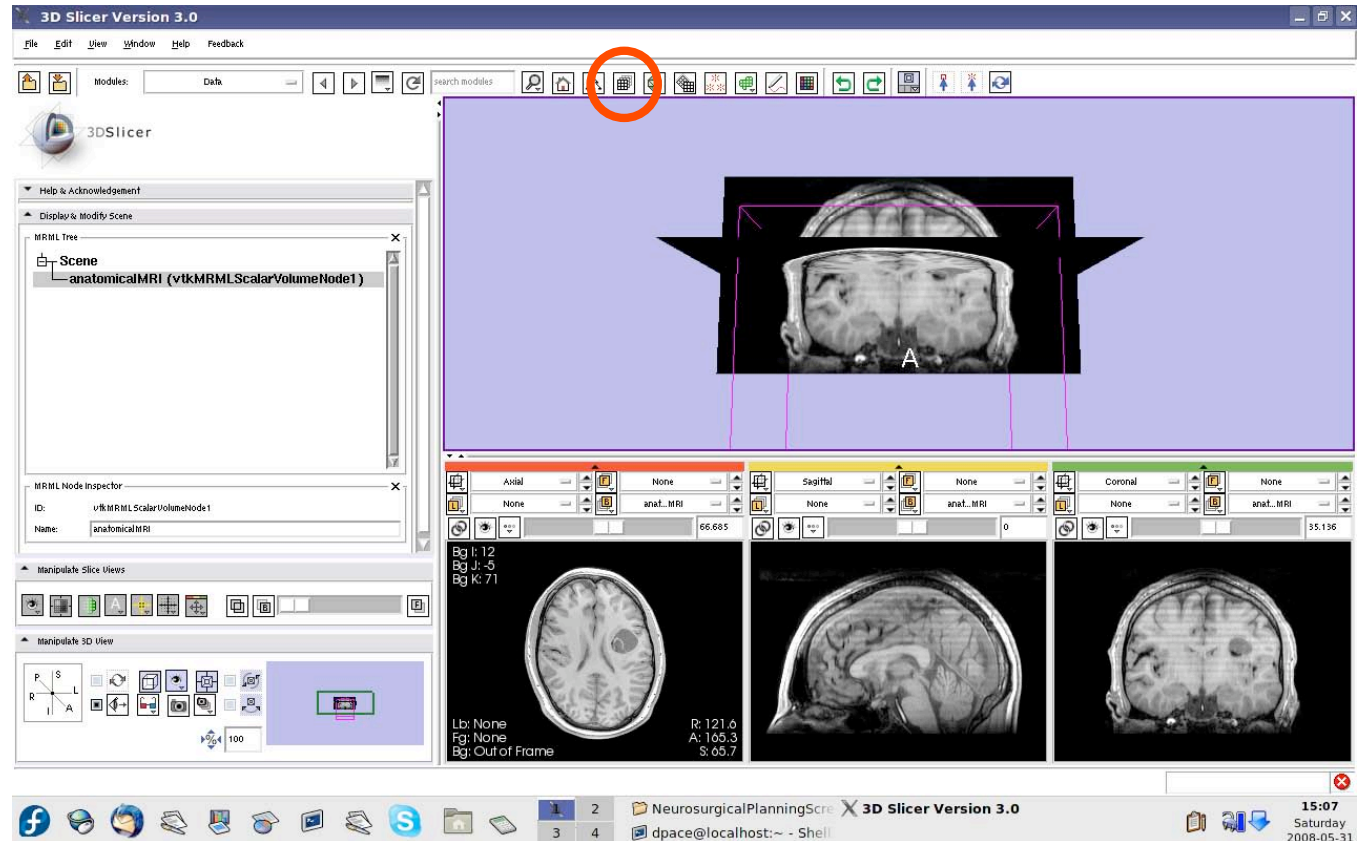
- **Steps involved in this section:**





Load the language fMRI data

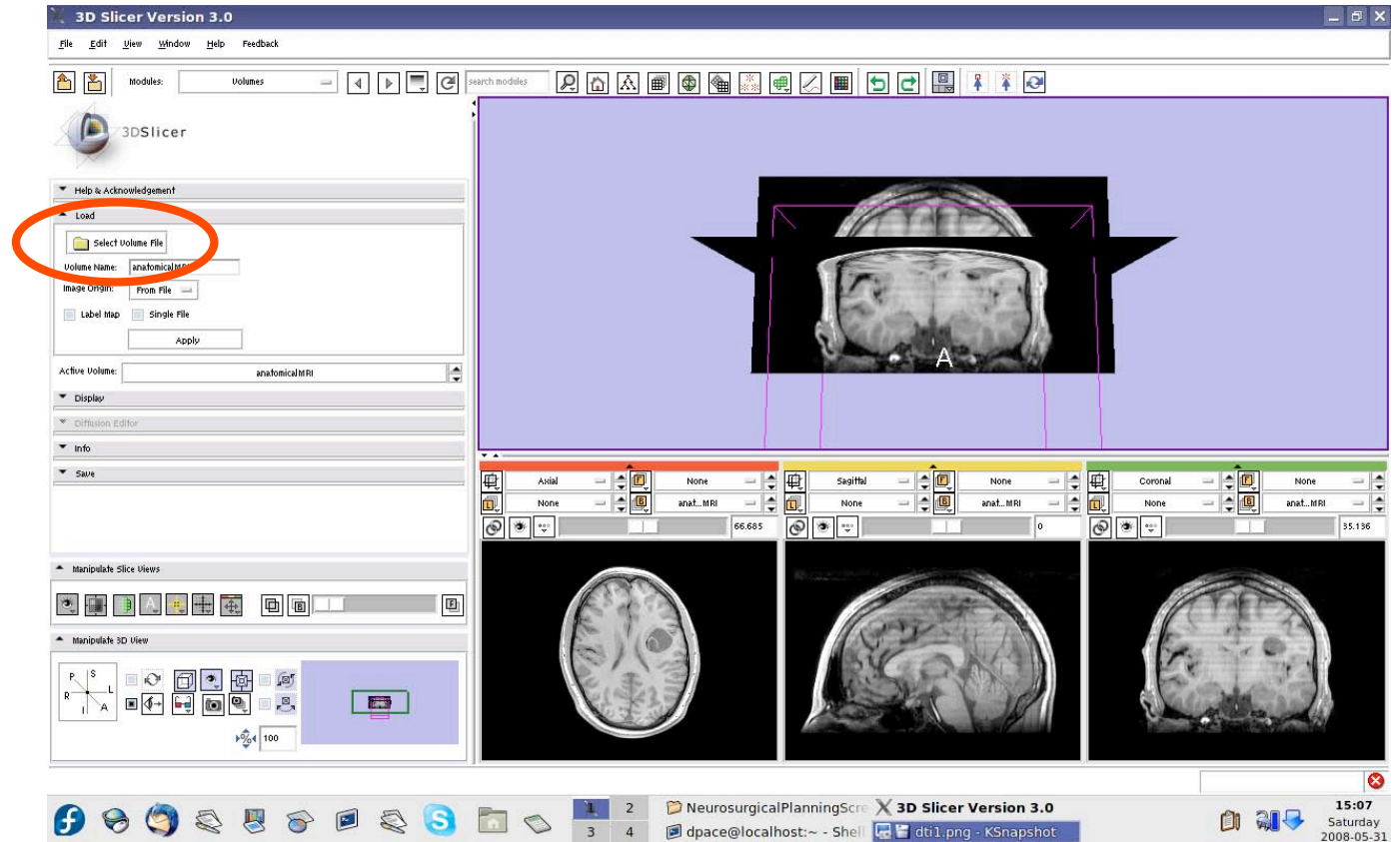
Open the
Volumes
module





Load the language fMRI data

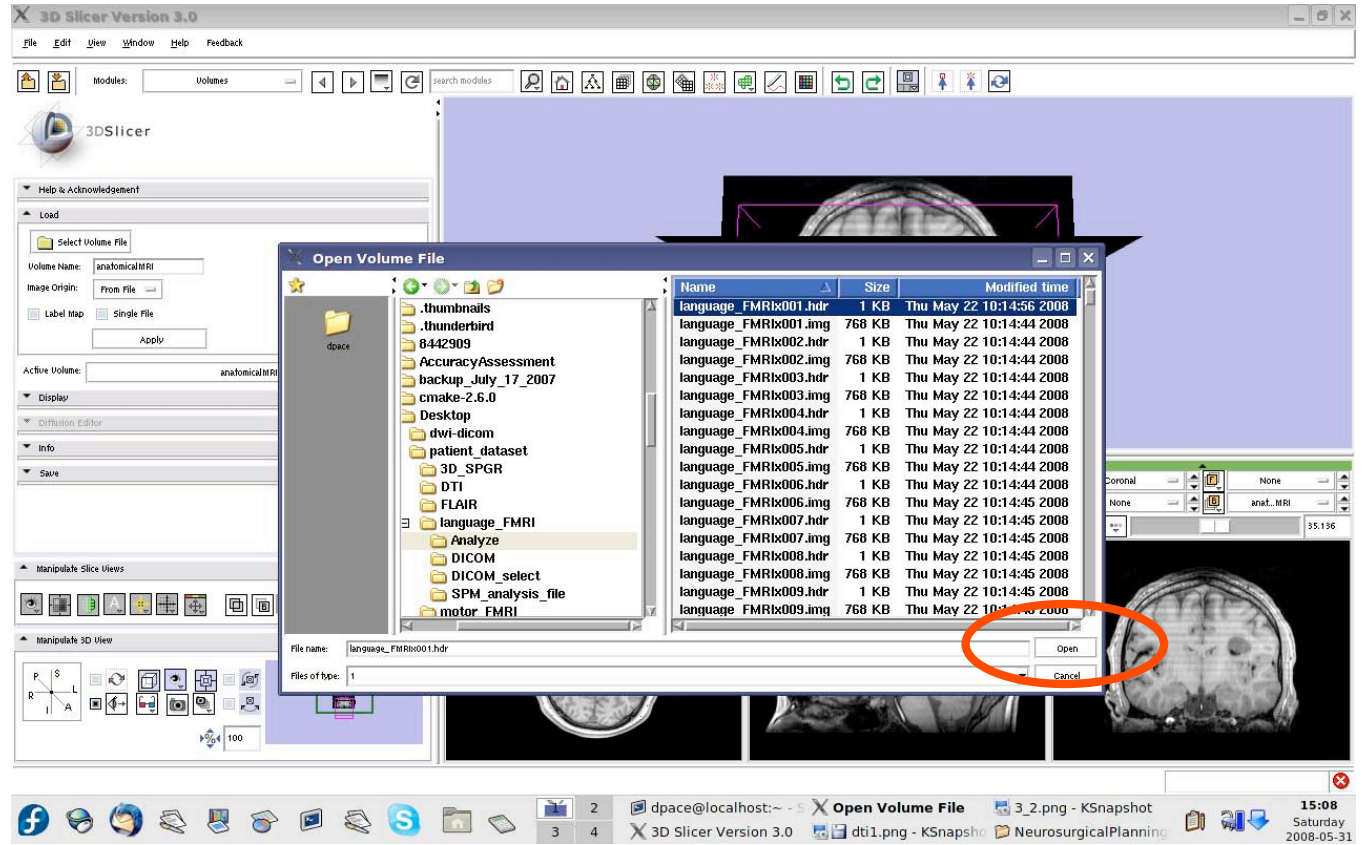
Click on
“Select
Volume File”





Load the language fMRI data

Click on the first image in the Analyze folder within the language_FMRI folder of the patient dataset, then click "Open"



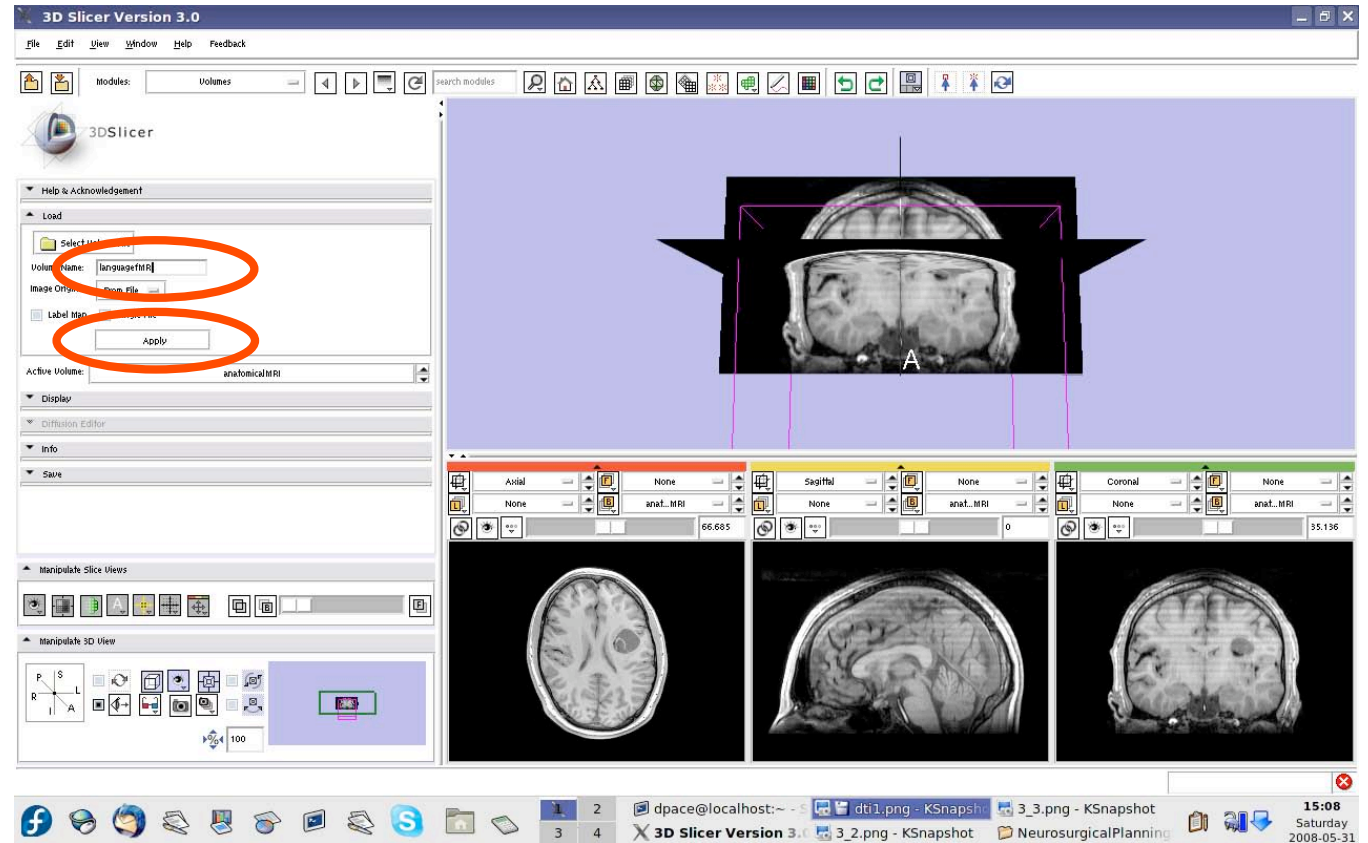


Load the language fMRI data

Set the Volume Name to languagefMRI

Keep the image origin set to "From File"

Click on "Apply"

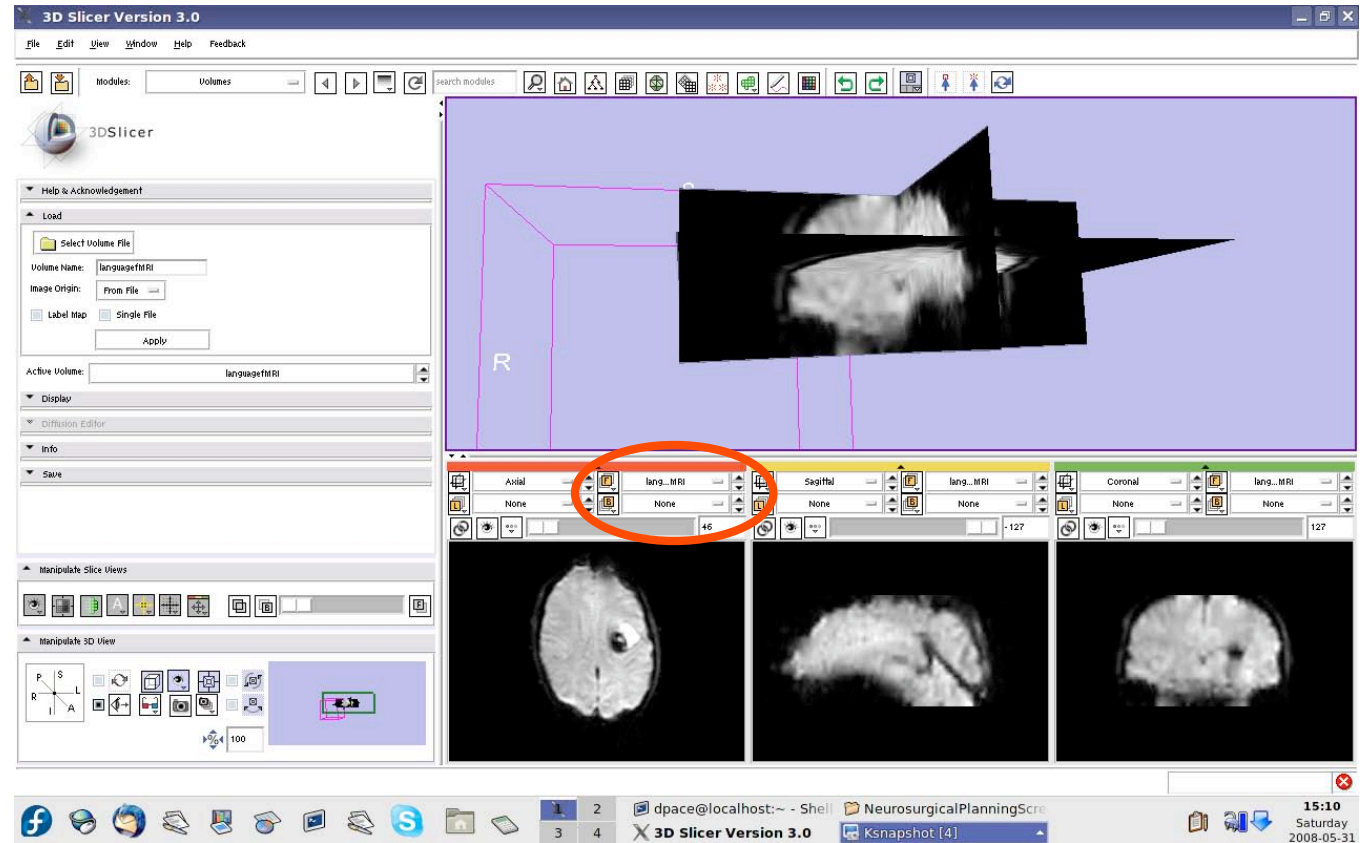




Load the language fMRI data

Set the foreground volume to languagefMRI

Set the background volume to none



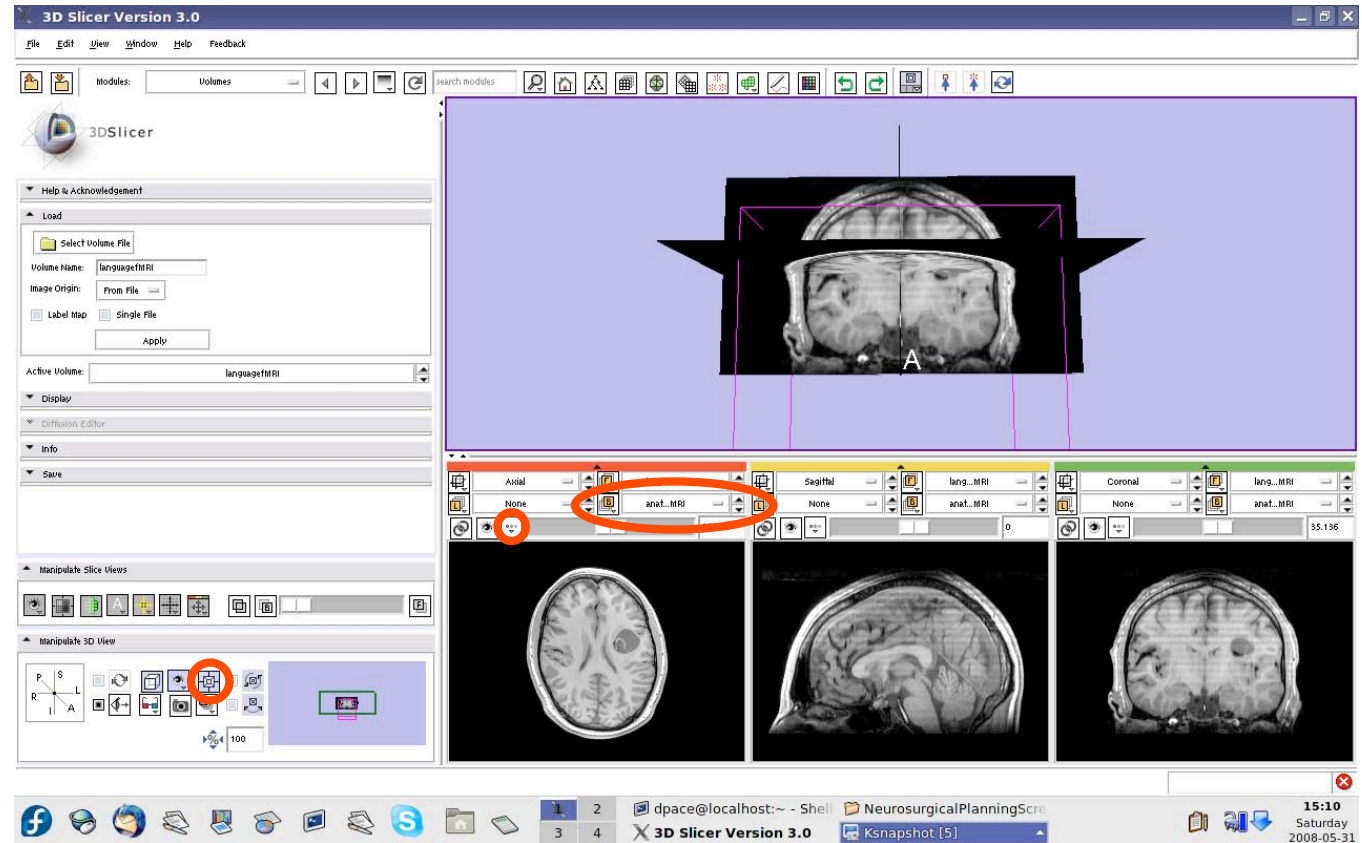


Load the language fMRI data

Set the background volume to anatomicalMRI

Click on the “fit to window” button

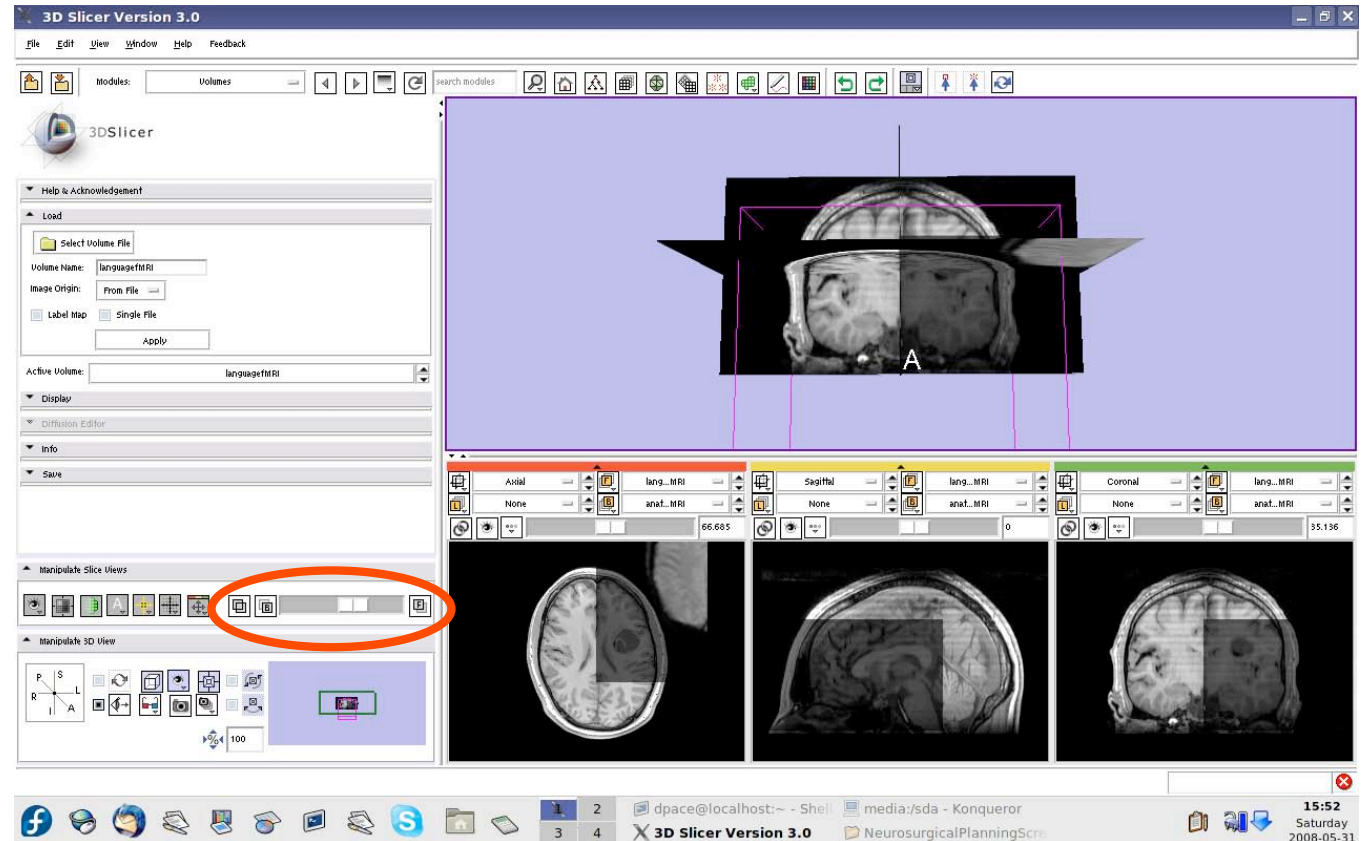
Click on the “center 3D view” button





Load the language fMRI data

Scale the opacities to see both the foreground and background layers





Load the language fMRI data

Note that the image volumes are not aligned

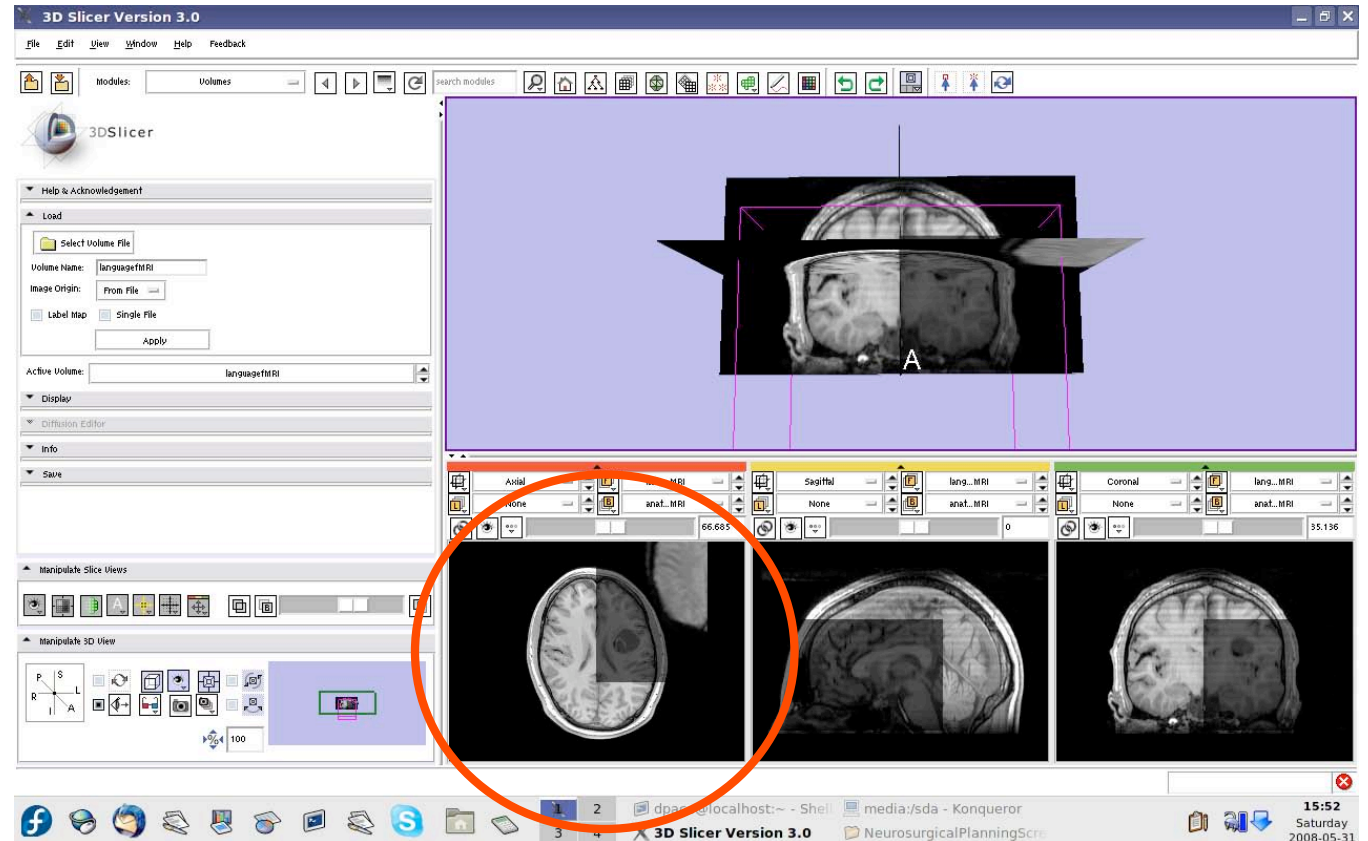
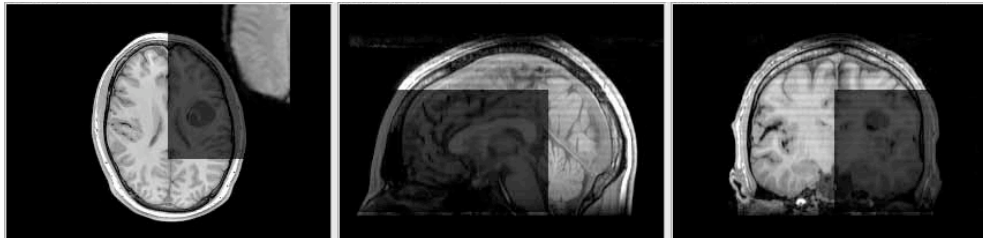
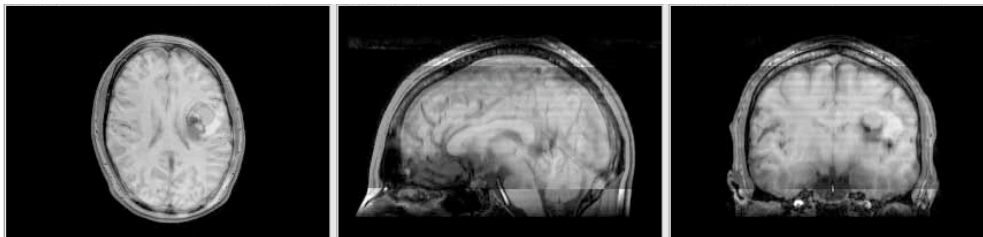




Image-to-Image registration



The anatomical MRI and functional MRI image volumes are **not aligned**



The anatomical MRI and functional MRI image volumes **overlap**

Image registration aligns two images together with the goal of making the corresponding anatomy overlap



Image-to-image registration

- **Steps involved in image registration:**

Initial manual transformation

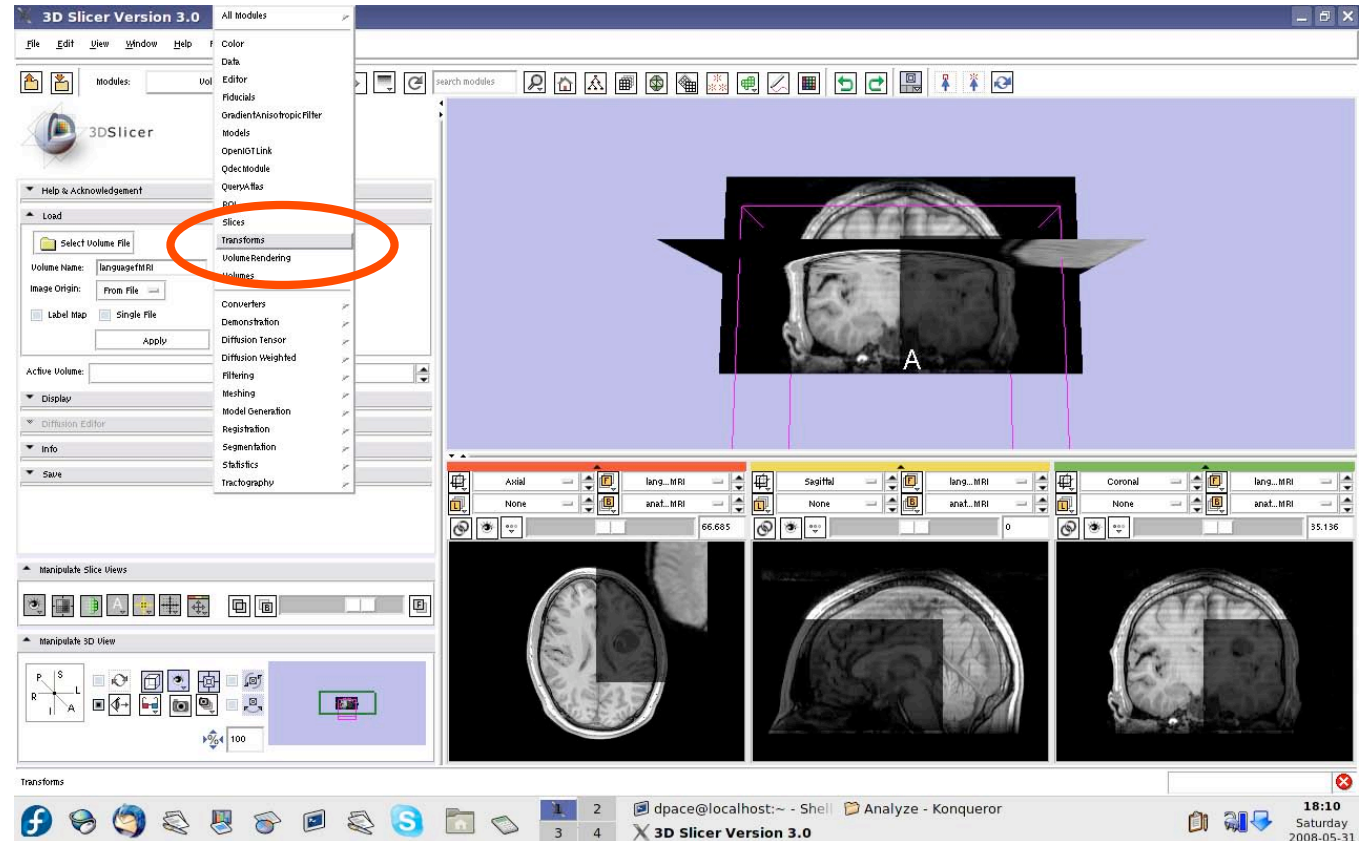
Automatic affine registration

- An affine transformation estimates the rotation, translation, scale and shear needed to align the **moving** image with the **fixed** image
- Slicer's affine registration module uses **mutual information** to estimate the similarity between two images



Initial manual transformation

Open the
Transforms
module

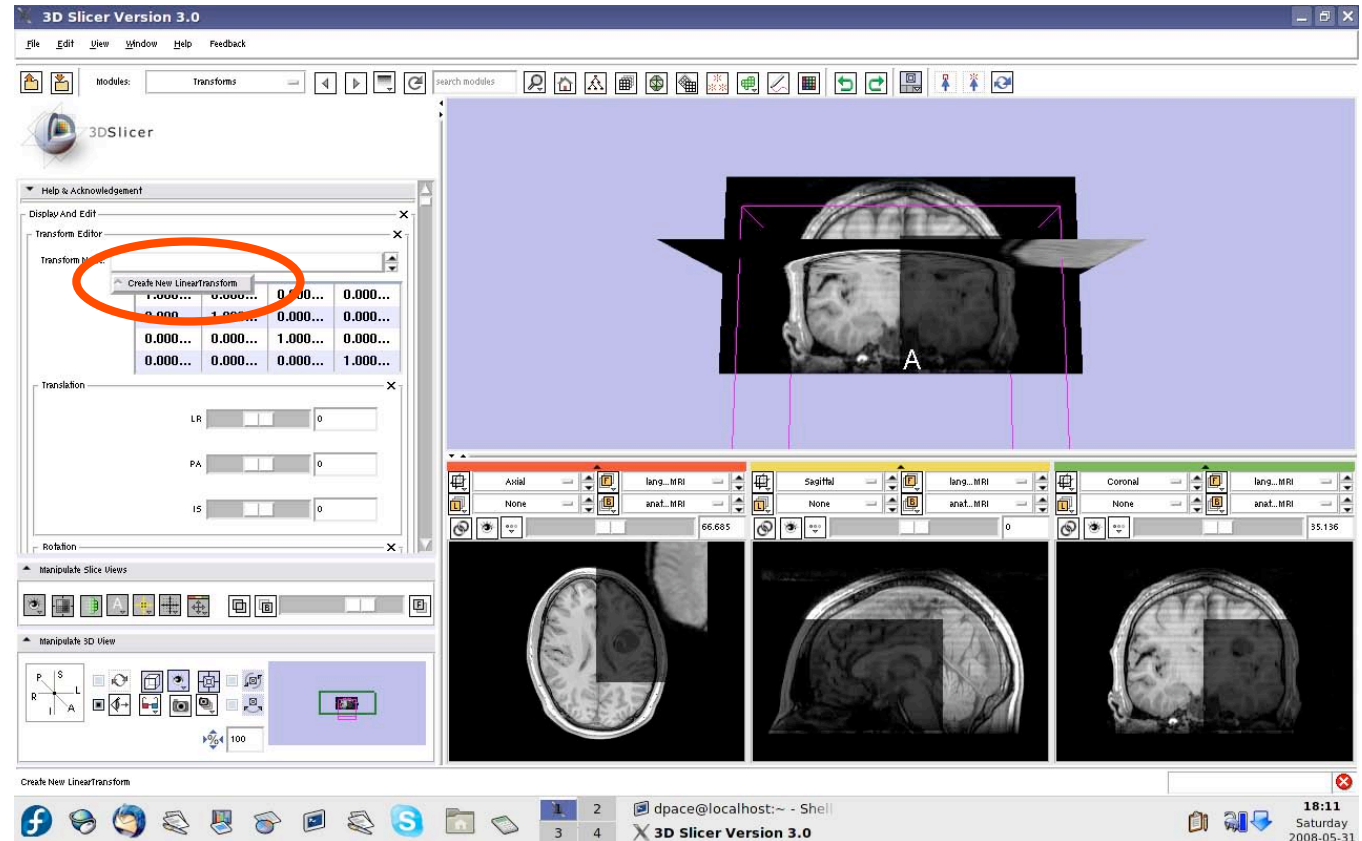




Initial manual transformation

Create a new linear transform

The new transform is initialized to the identity matrix

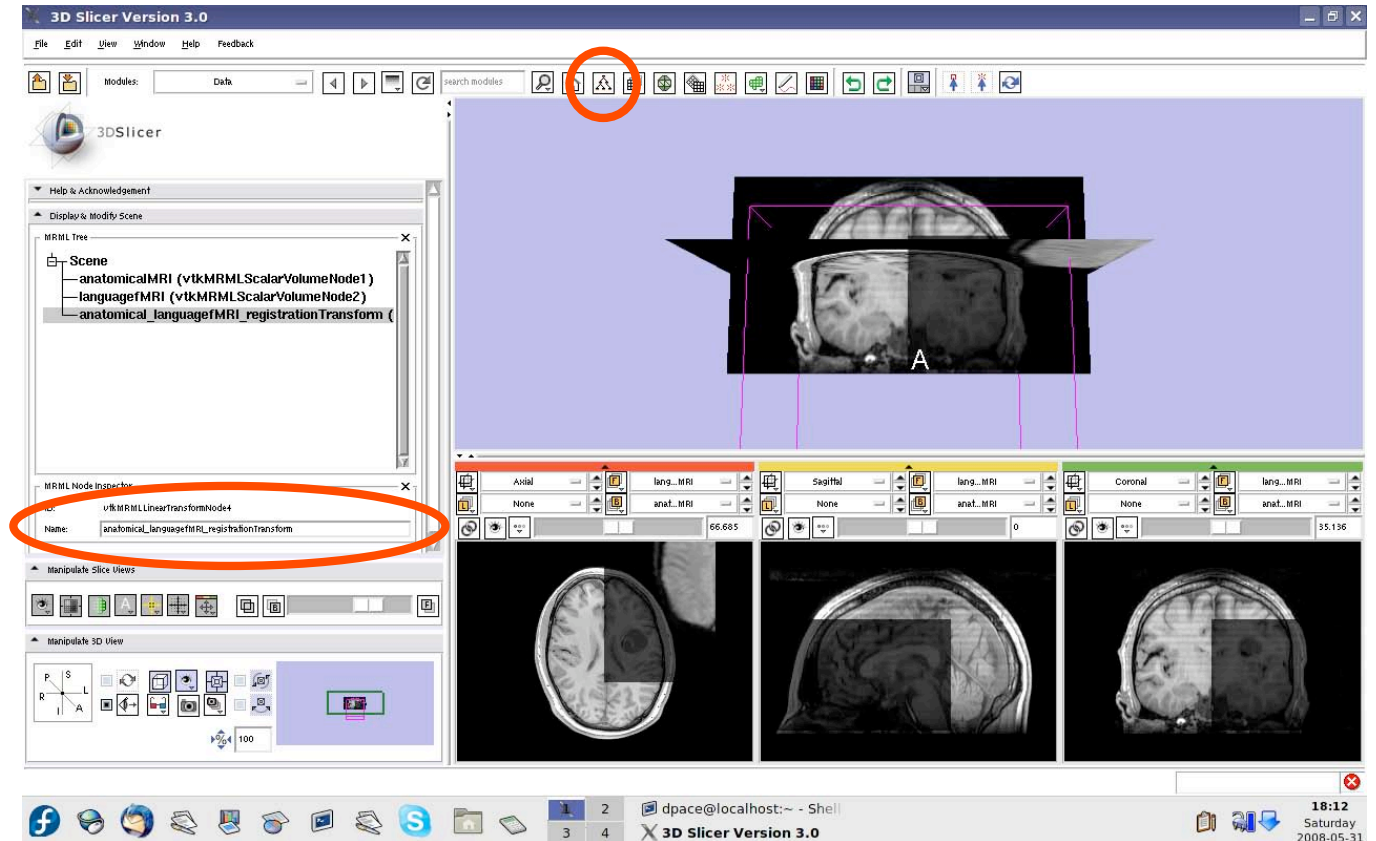




Initial manual transformation

Open the Data module

Change the name of the transform to “anatomical_languagefMRI_registrationTransform”

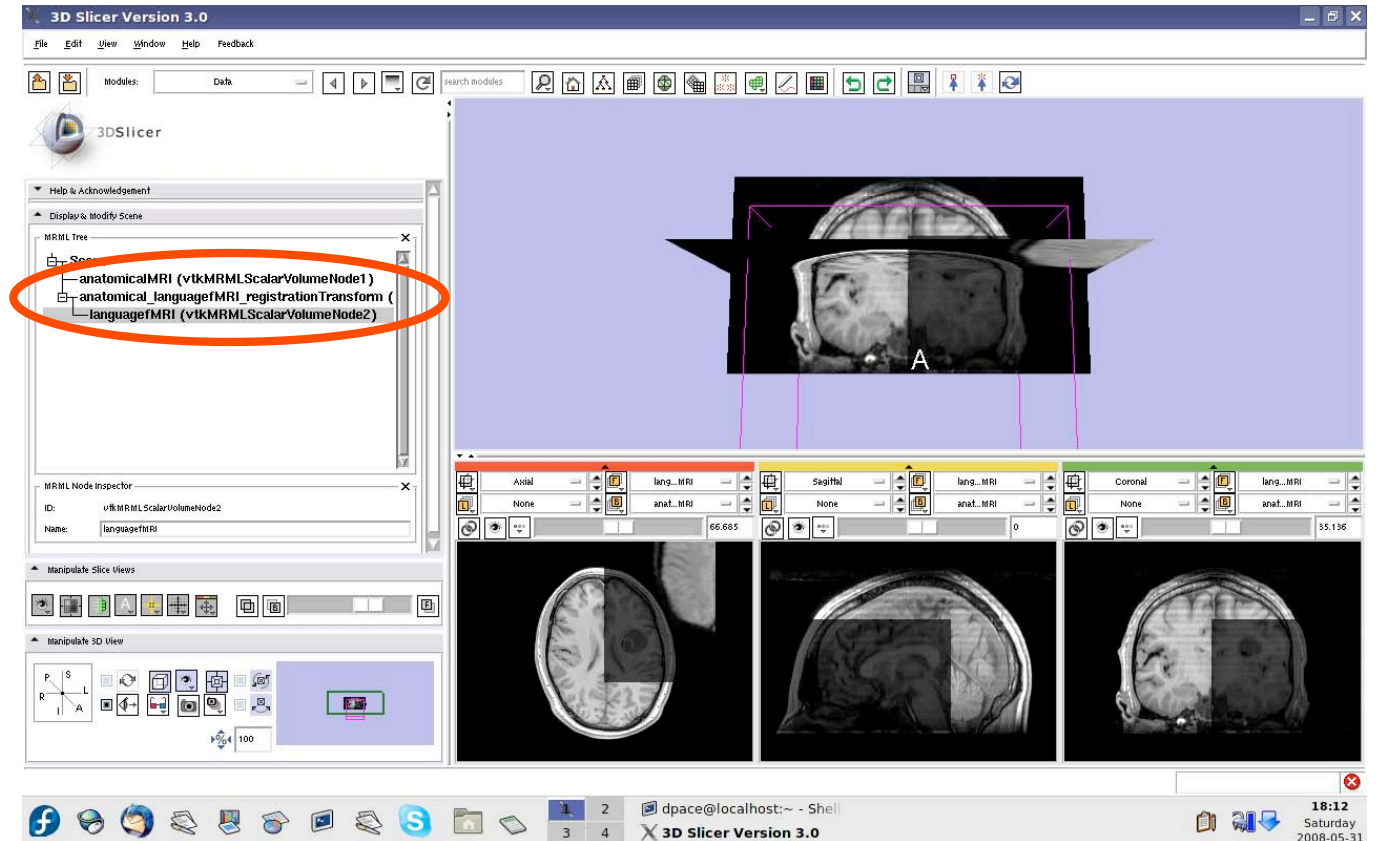




Initial manual transformation

Drag the languagefMRI node under the transform node

Now any changes to the transform node are applied to the language fMRI image volume

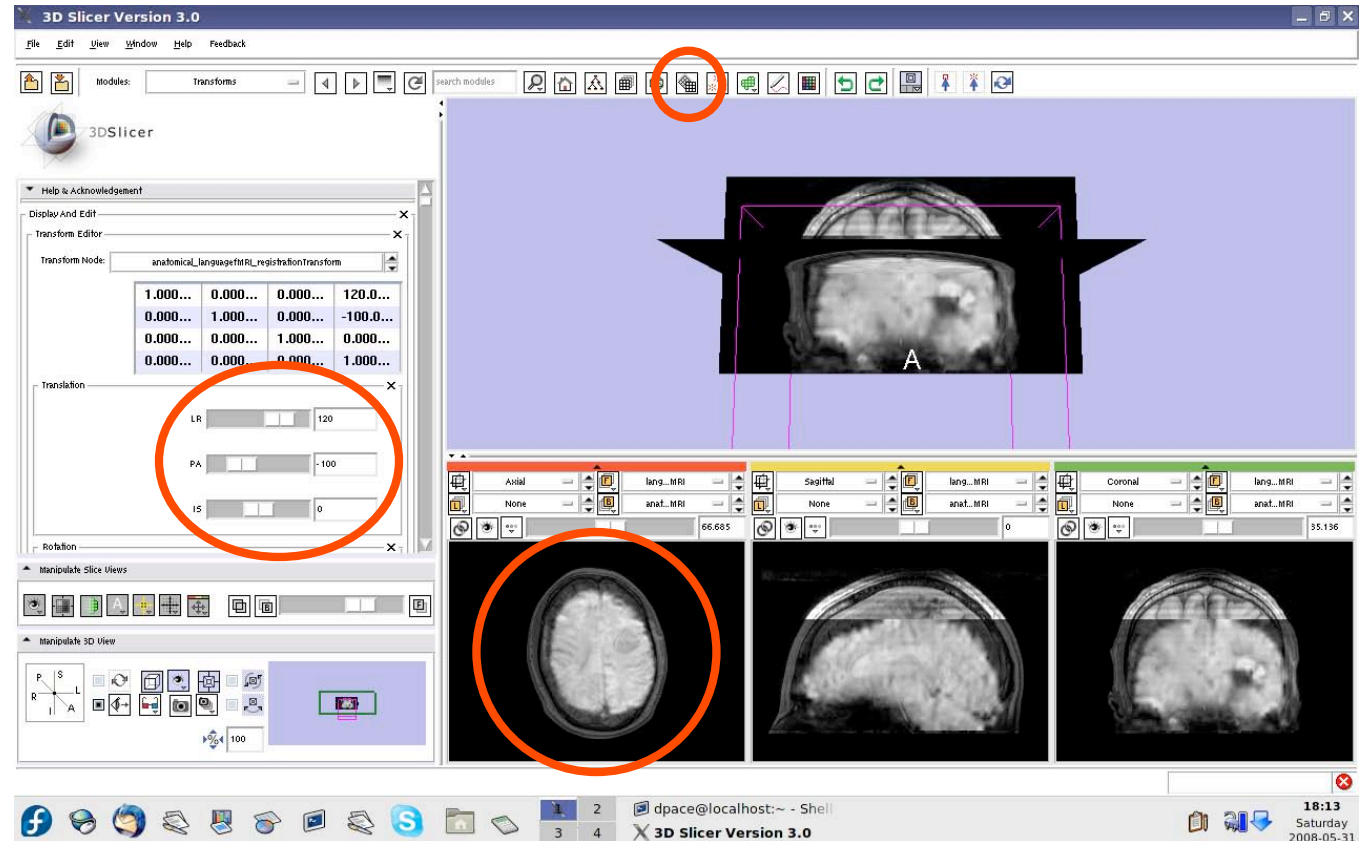




Initial manual transformation

Open the Transforms module

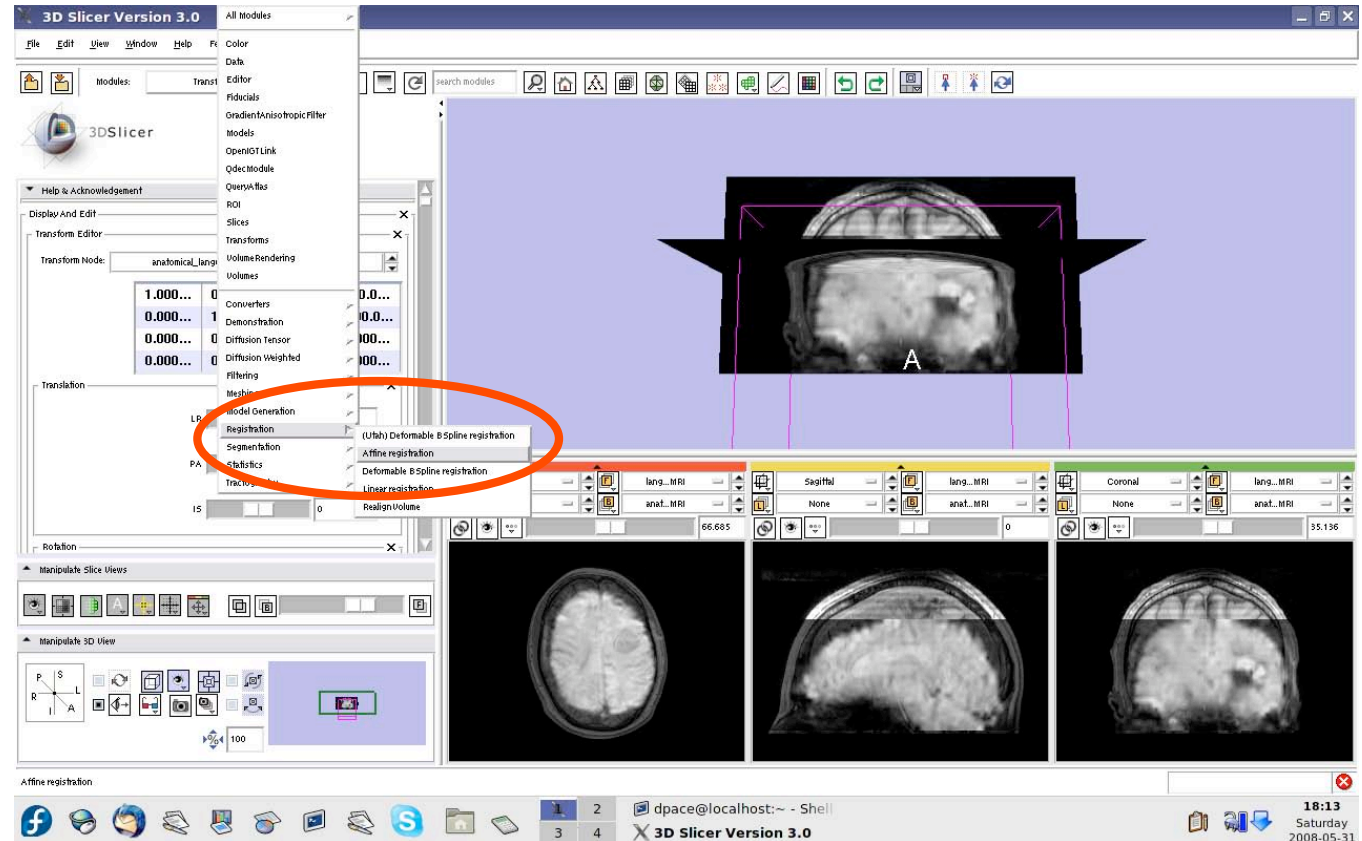
Adjust the translation components to roughly align the two image volumes in the axial plane





Automatic affine registration

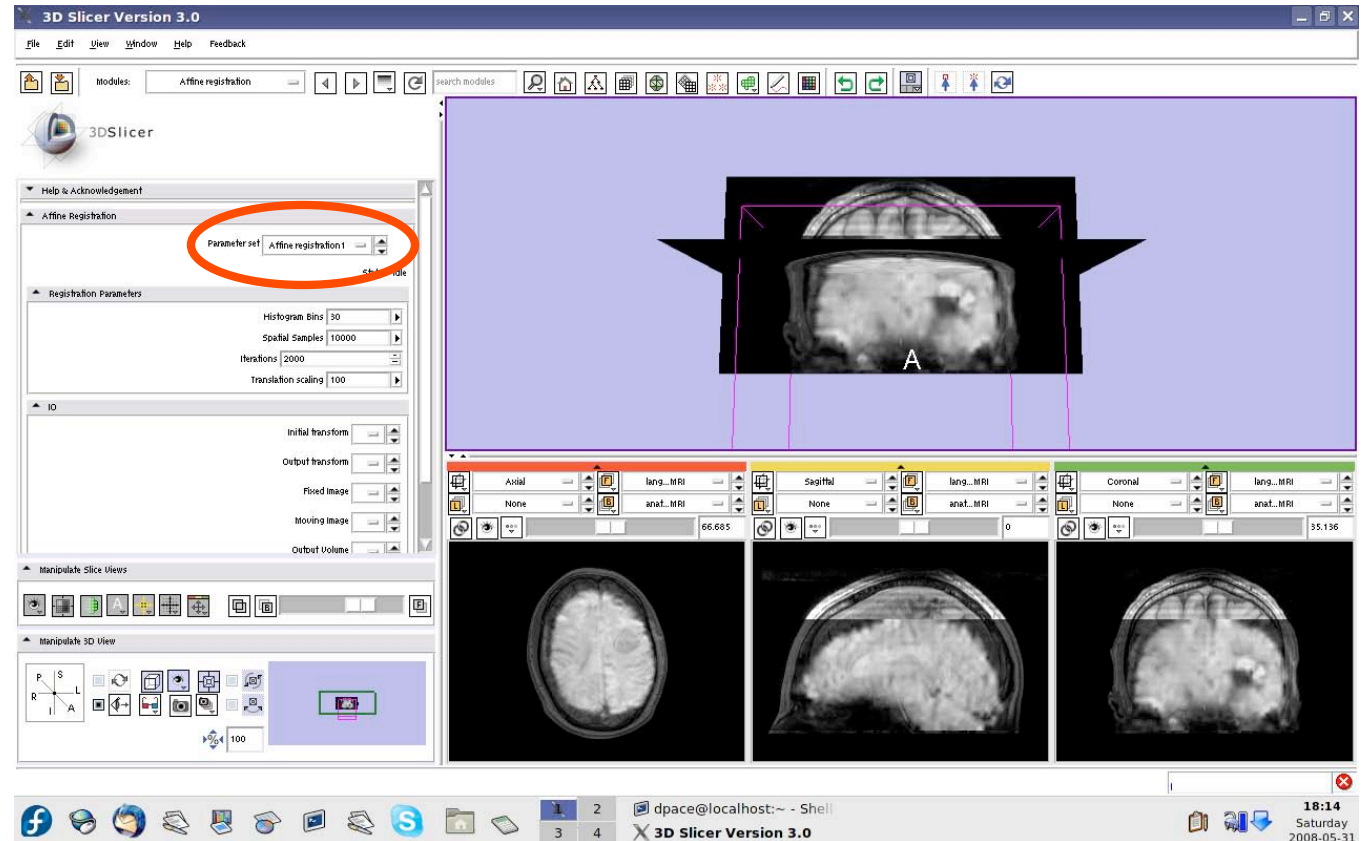
Open the
Affine
Registration
module





Automatic affine registration

Under
Parameter
Set, select
“Create new
CommandLine
Module”

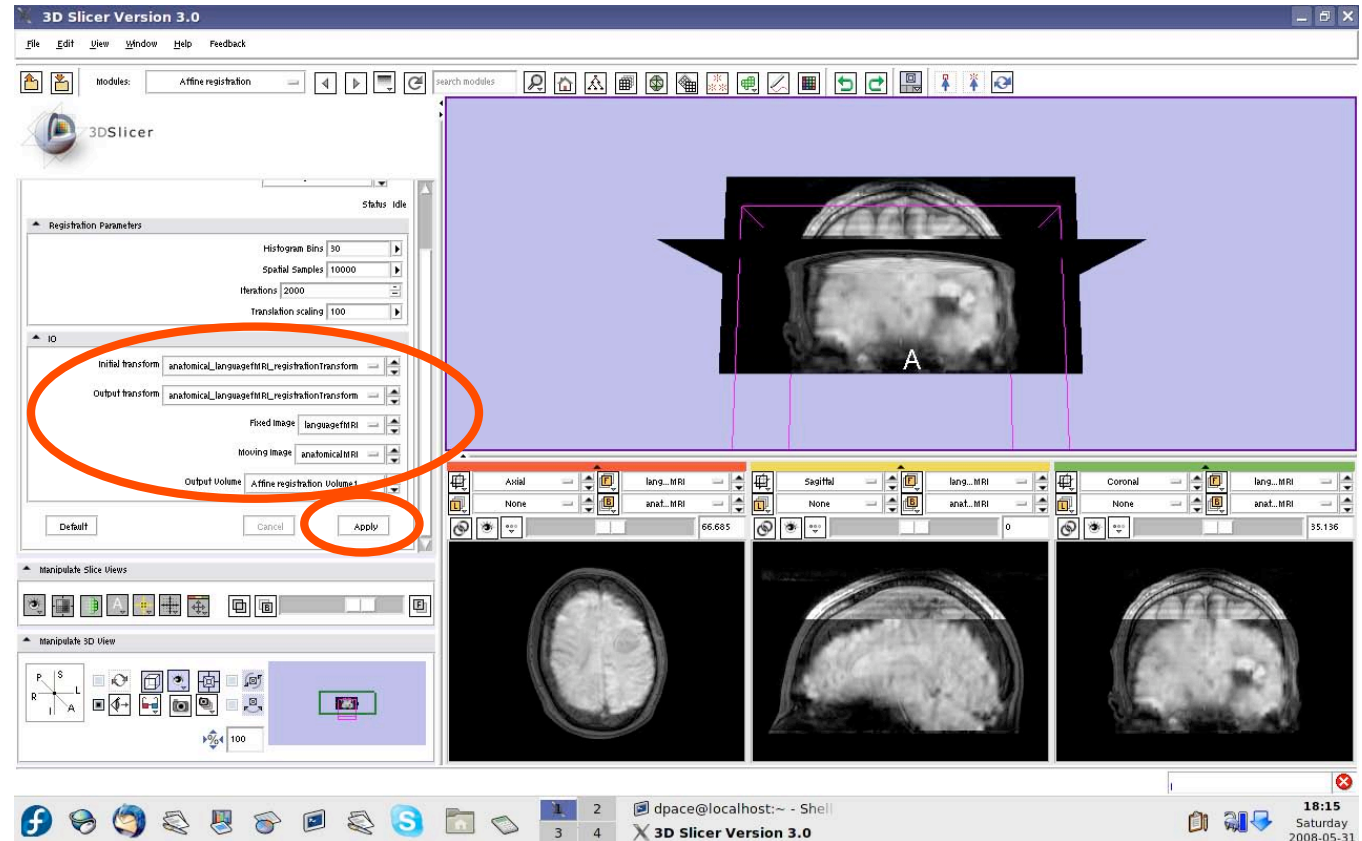




Automatic affine registration

- Initial transform = anatomical_language fMRI_registration Transform
- Output transform = anatomical_language fMRI_registration Transform
- Fixed Image = language fMRI
- Moving Image = anatomical MRI
- Output Volume = Create New Volume

Click “Apply”

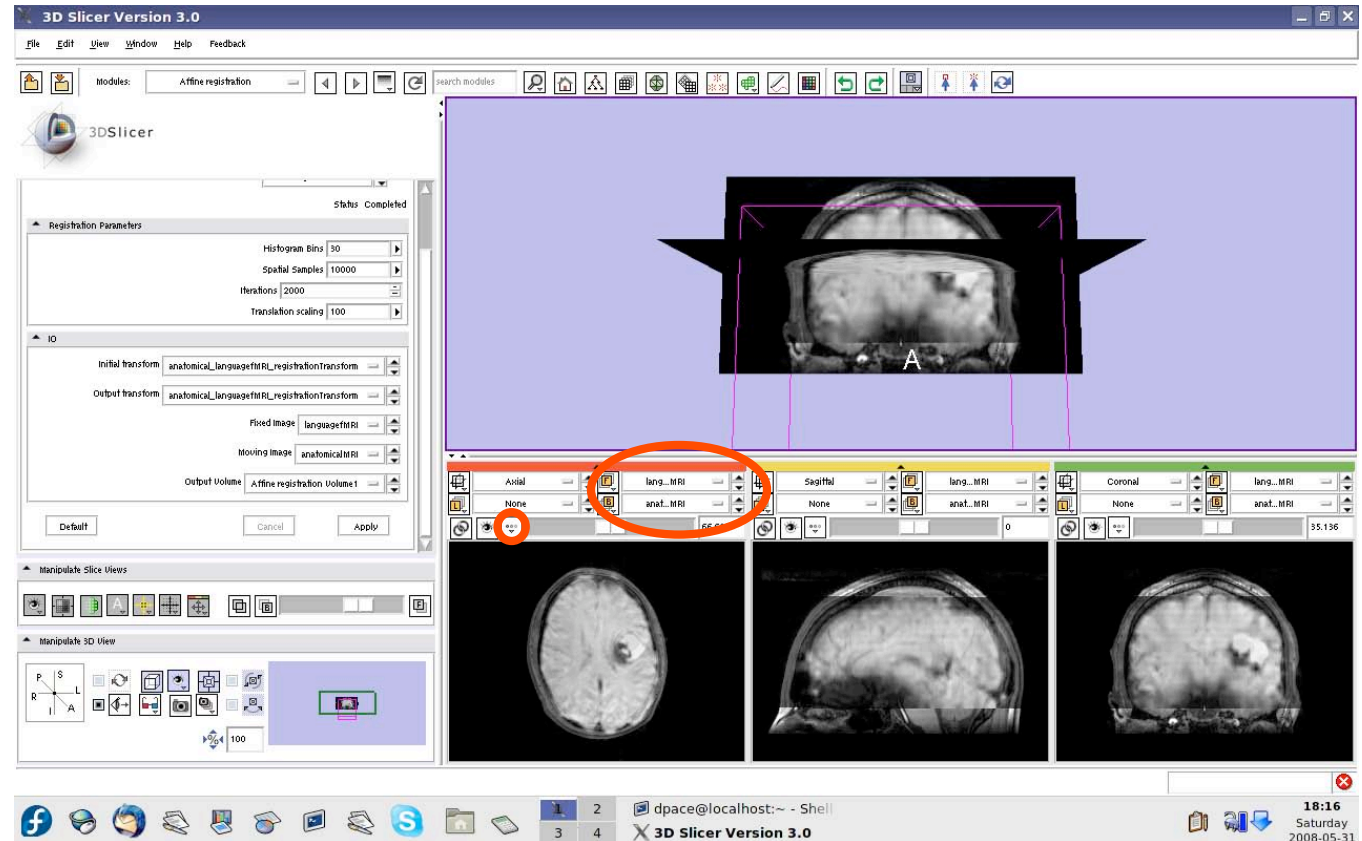




Automatic affine registration

Set the foreground to languagefMRI, and the background to anatomicalMRI

Click on the “fit to window” button

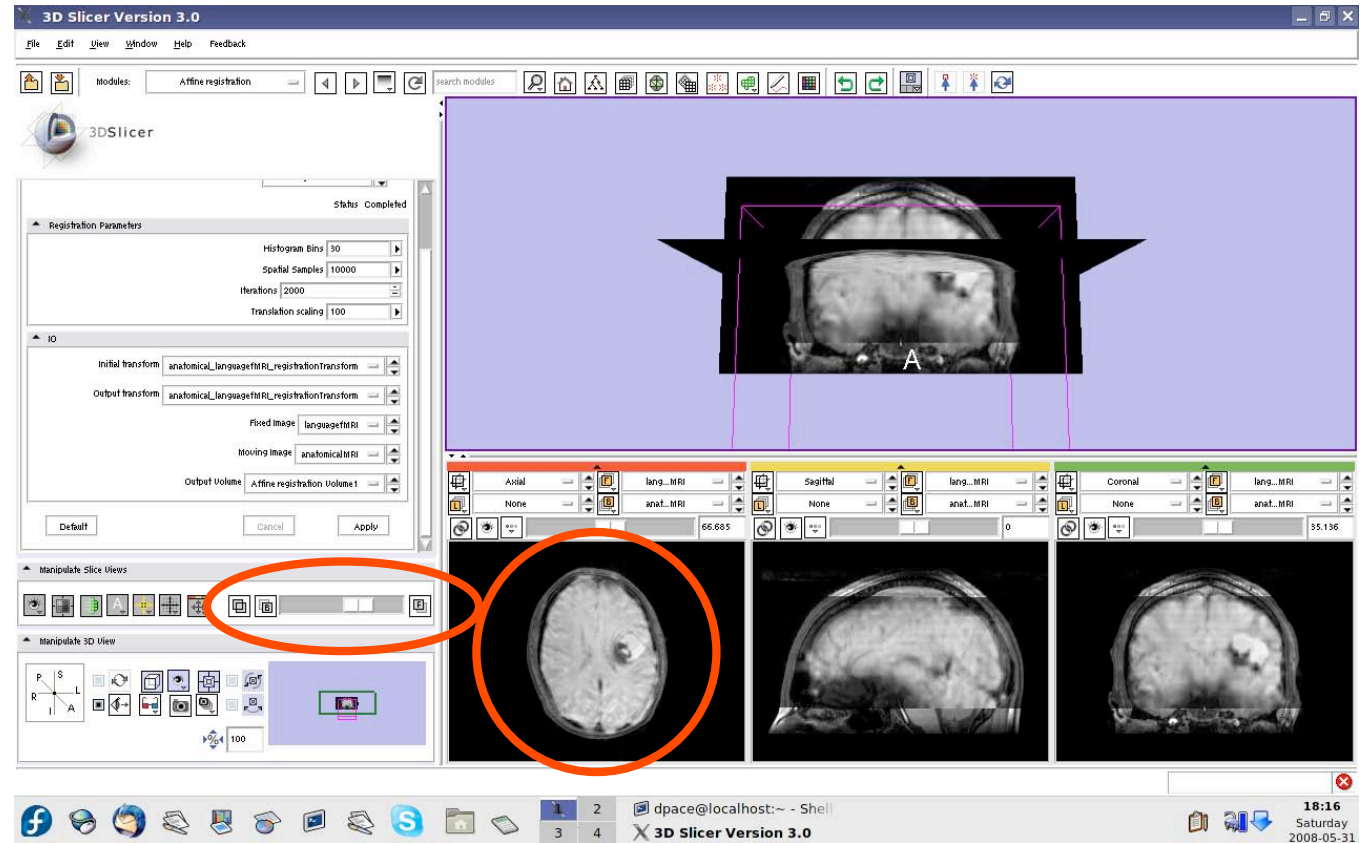




Automatic affine registration

Scale the opacities to see that the images are now aligned

The transform transforms the fixed image (language fMRI) to align with the moving image (anatomical MRI)

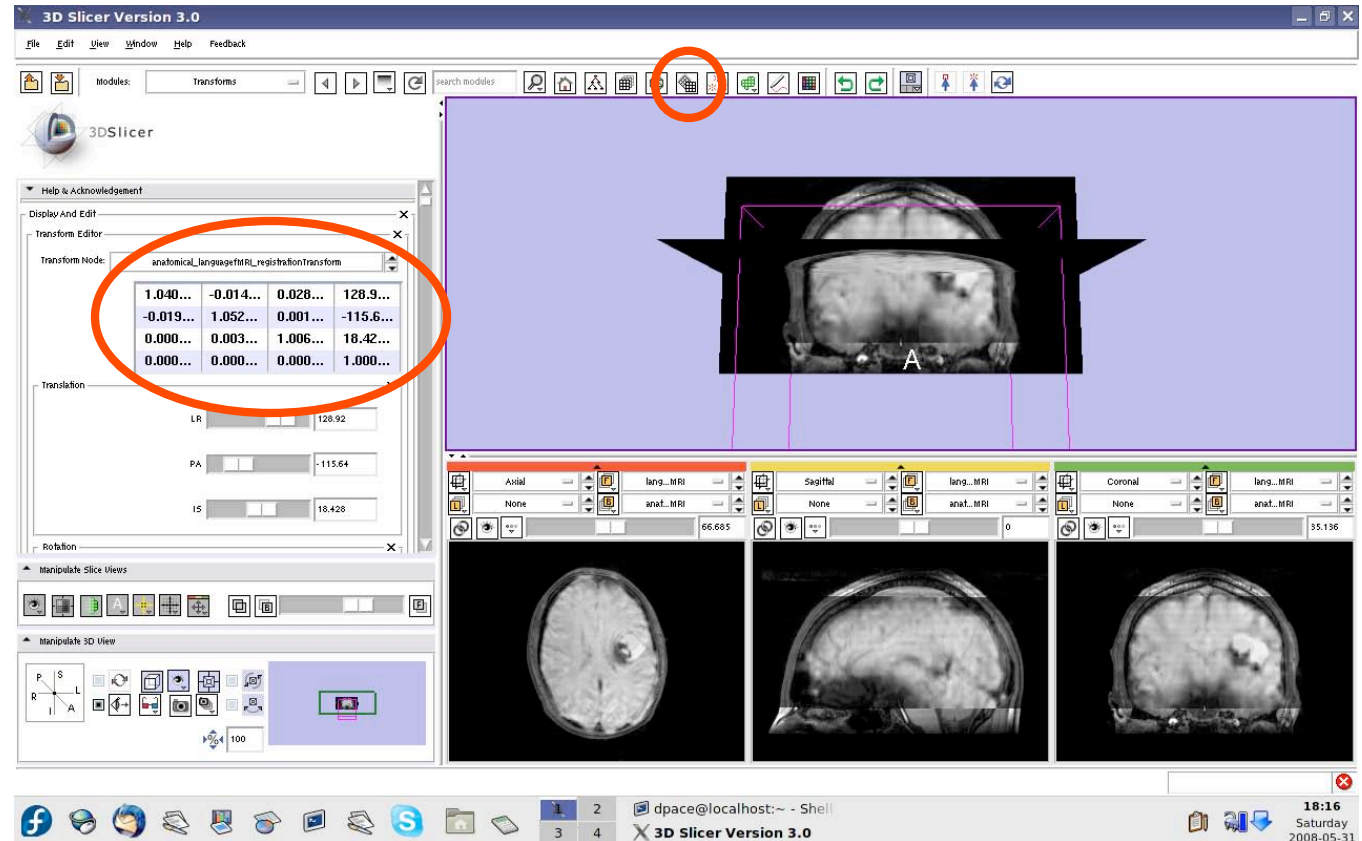




Automatic affine registration

Open the Transforms module

Click on the transform node to see that the matrix has changed

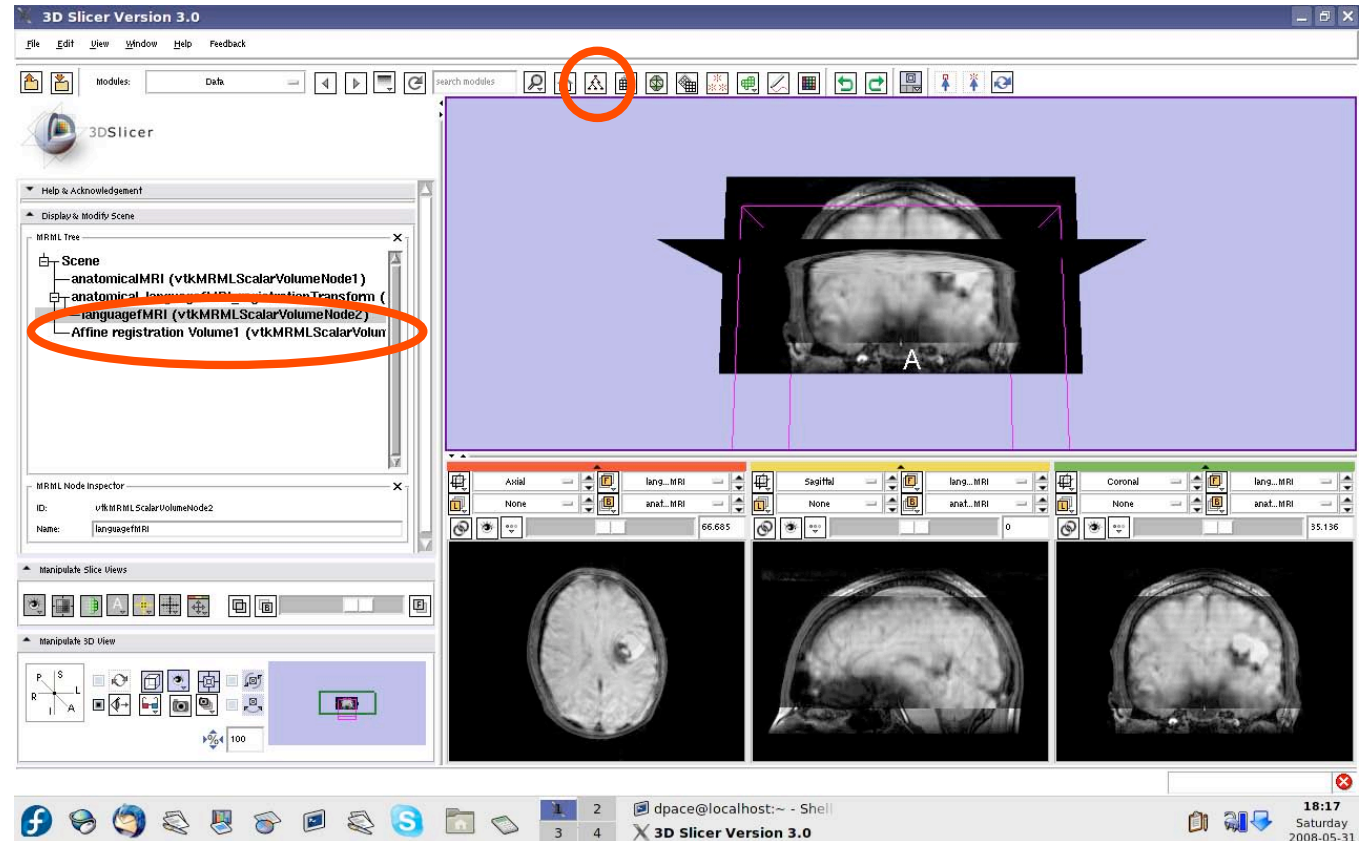




Automatic affine registration

Open the Data module

The new volume in the MRML scene is the resampled moving image (the anatomical MRI)

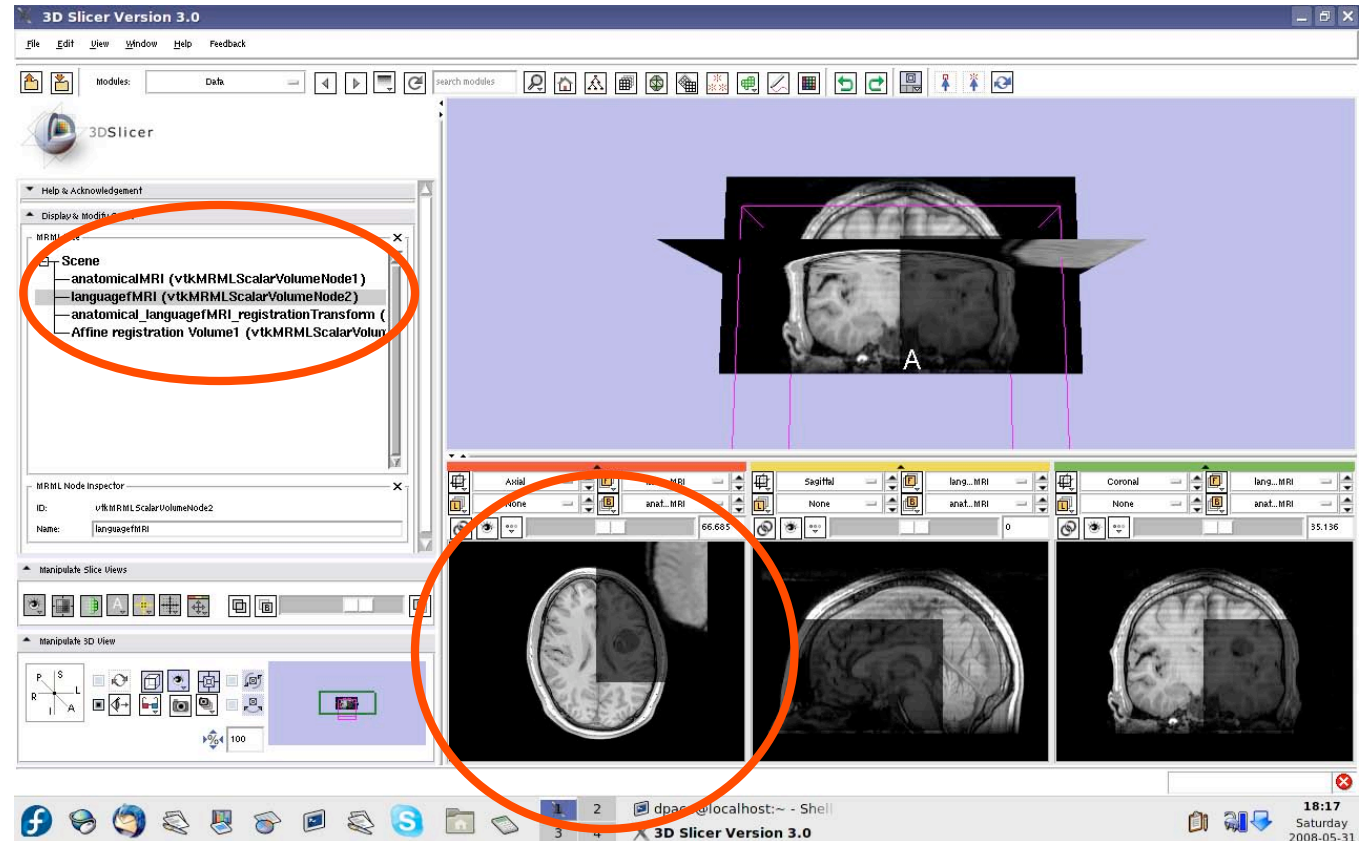




Automatic affine registration

Drag the languagefMRI node under the Scene node

Since the language fMRI image is no longer transformed, the images are not aligned again

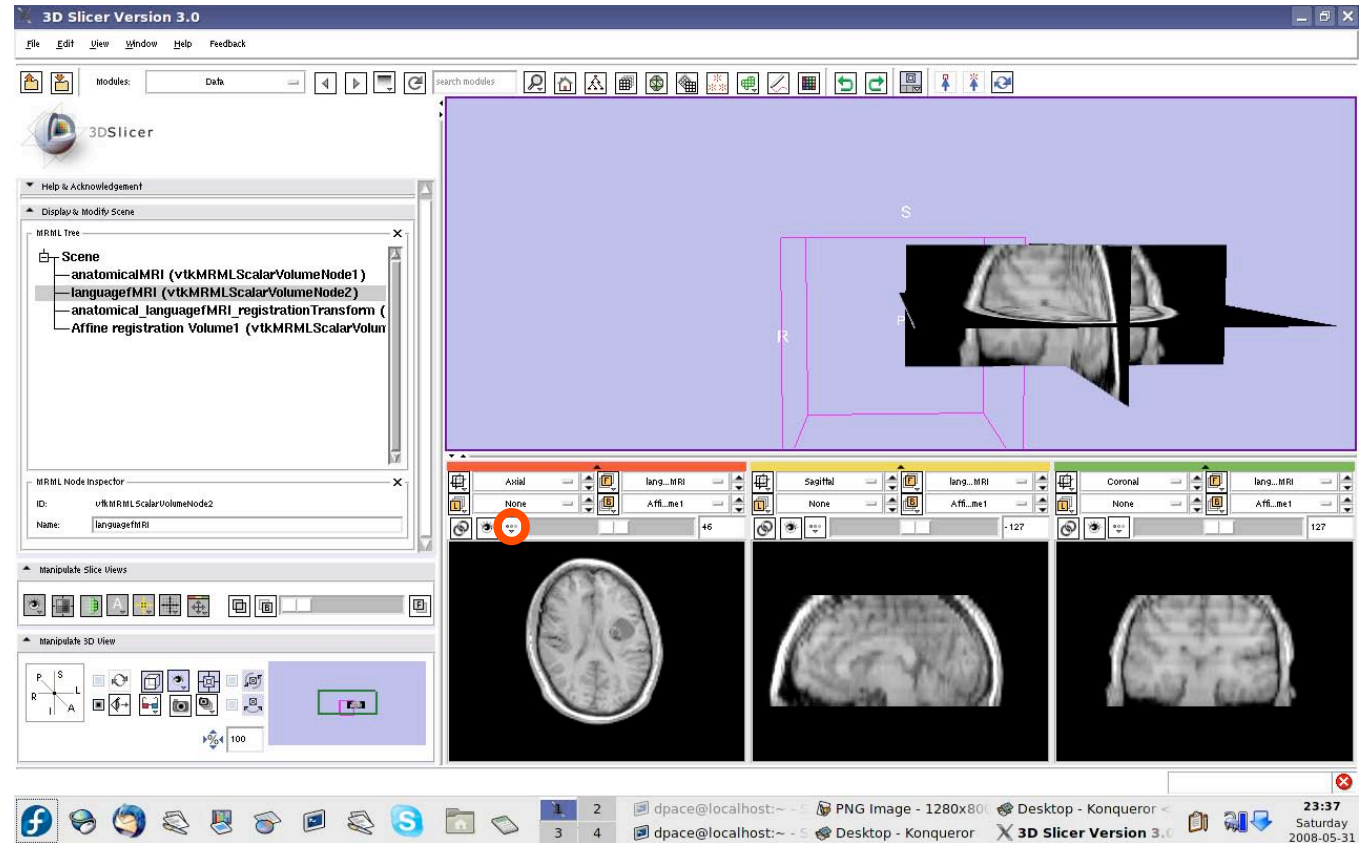




Automatic affine registration

Set the foreground to languagefMRI and the background to Affine registration Volume1

Click on the “fit to window” button

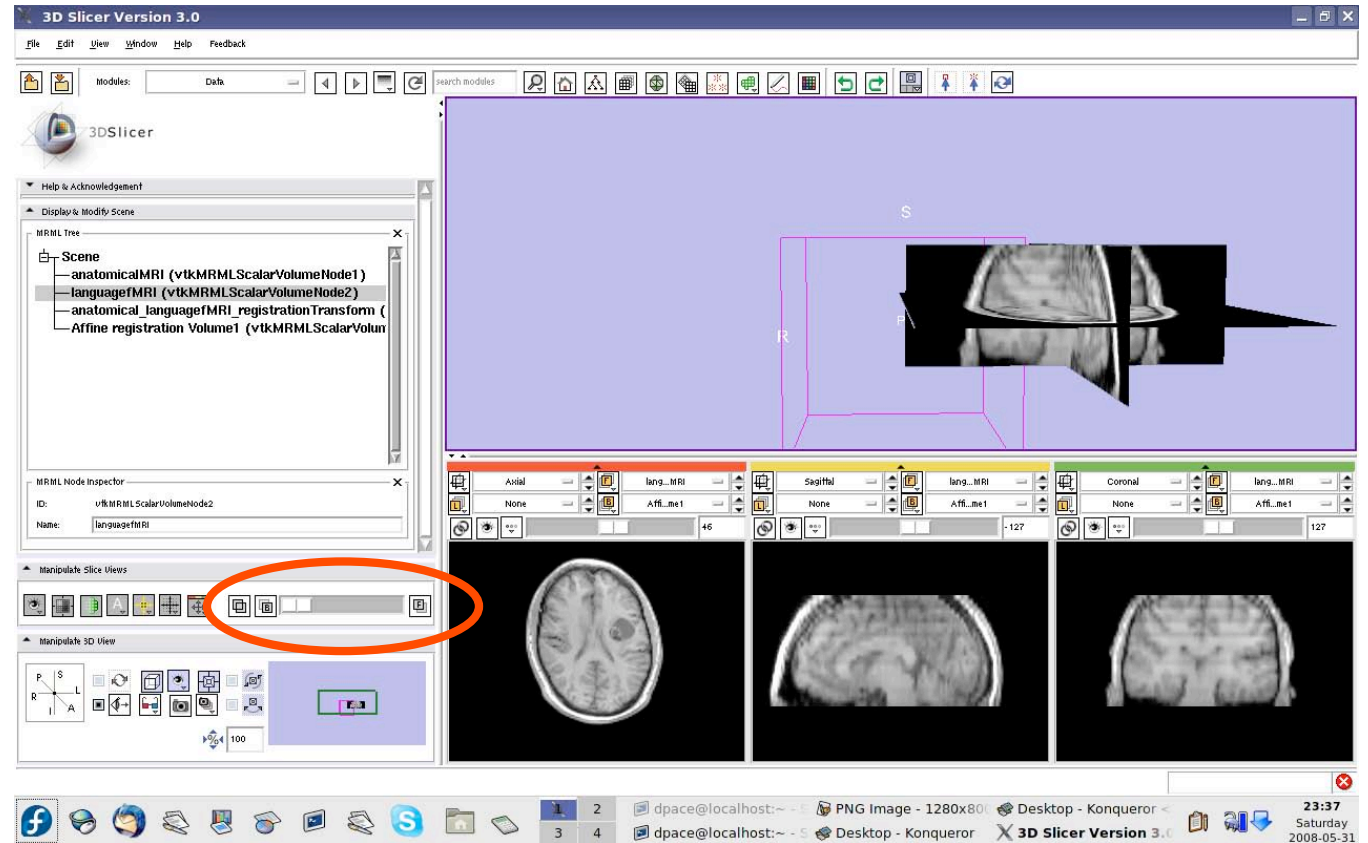




Automatic affine registration

Scale the opacities to see that the images are aligned

The new image is the moving image (anatomical MRI) transformed to align with the fixed image (language fMRI)

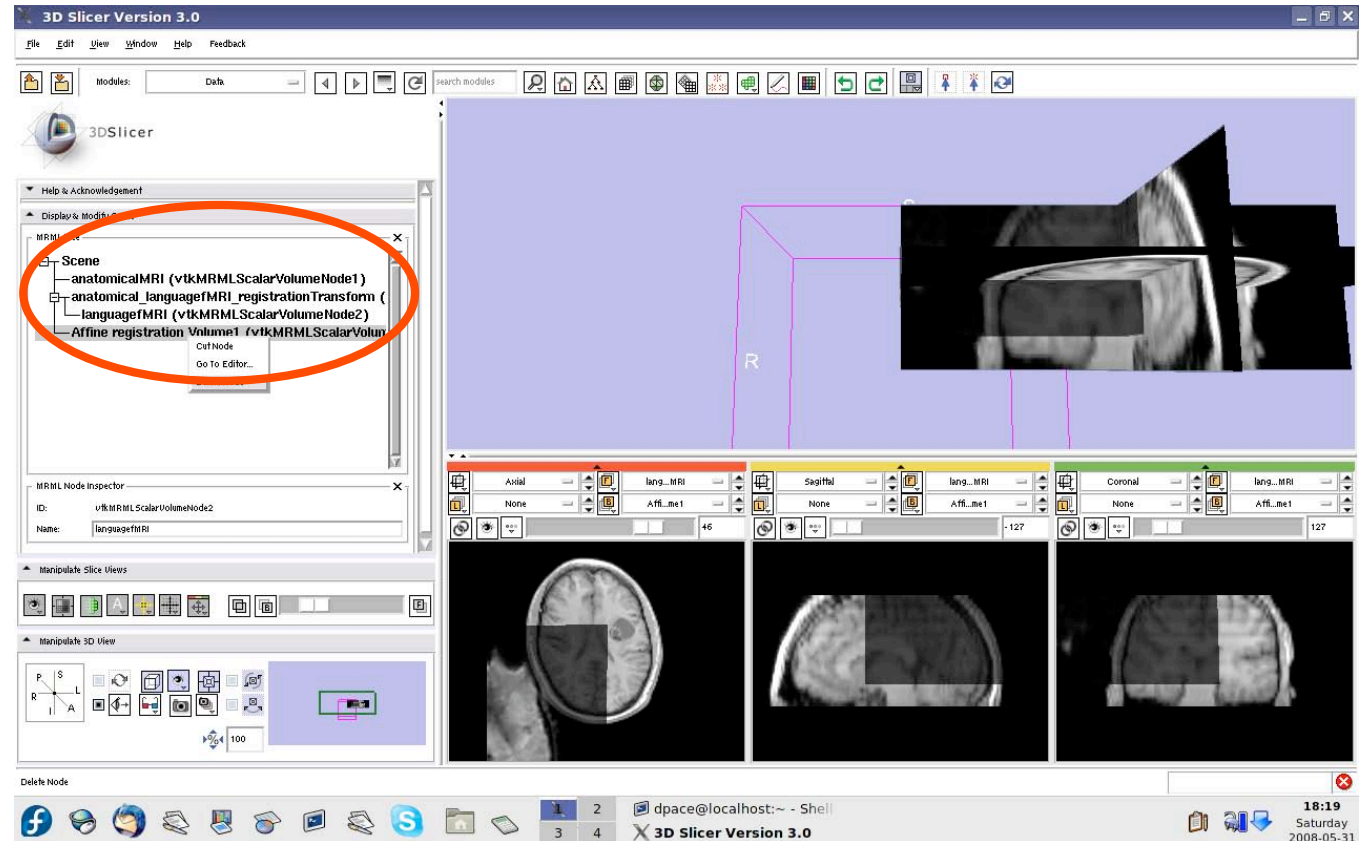




Automatic affine registration

Drag the languagefMRI node under the transform node

Right-click on the Affine registration Volume1 node and select "Delete node"





Threshold image intensity

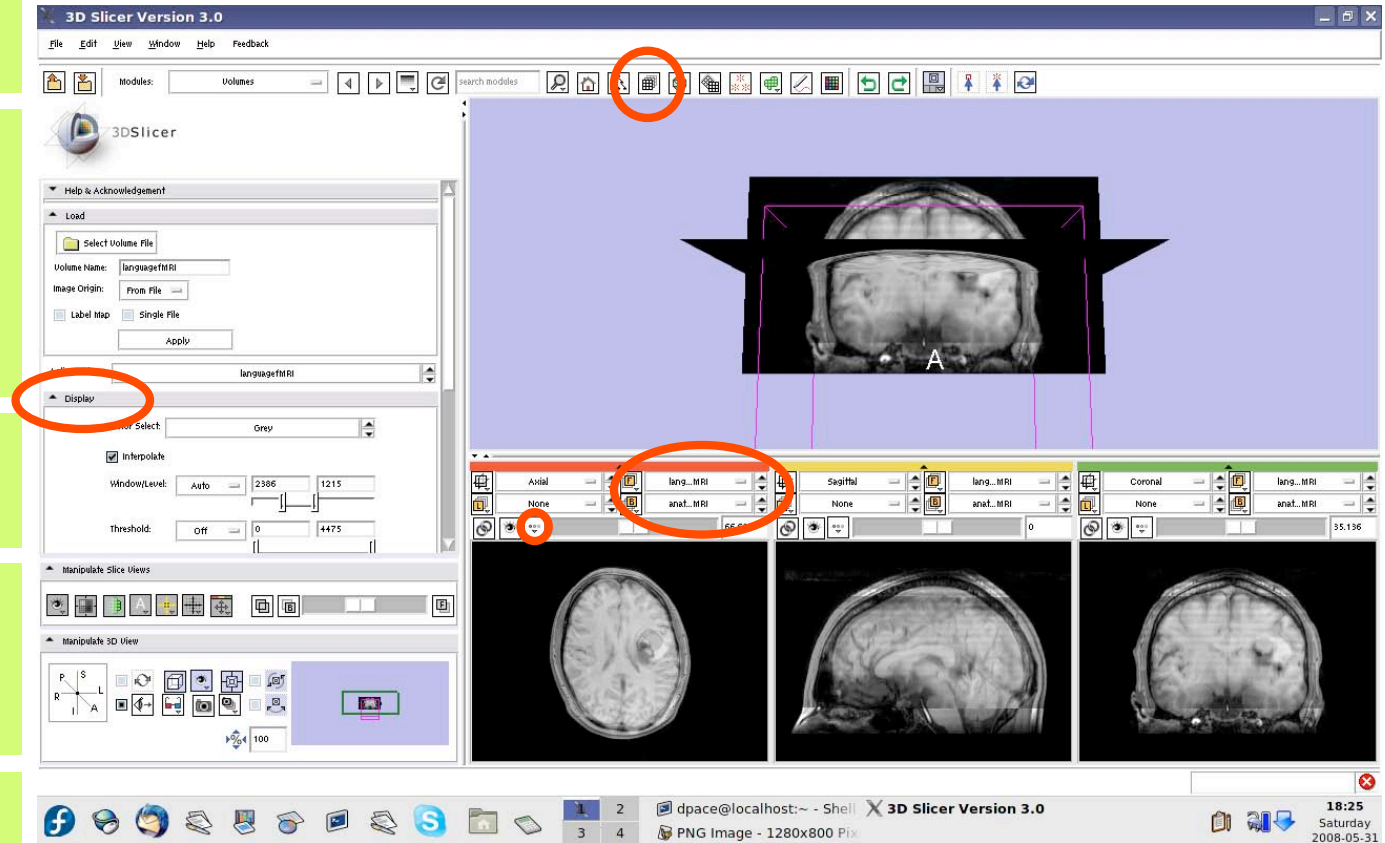
Open the Volumes module

Set the foreground to languagefMRI, and the background to anatomicalMRI

Click on the “fit to window” button

Set the active volume to languagefMRI

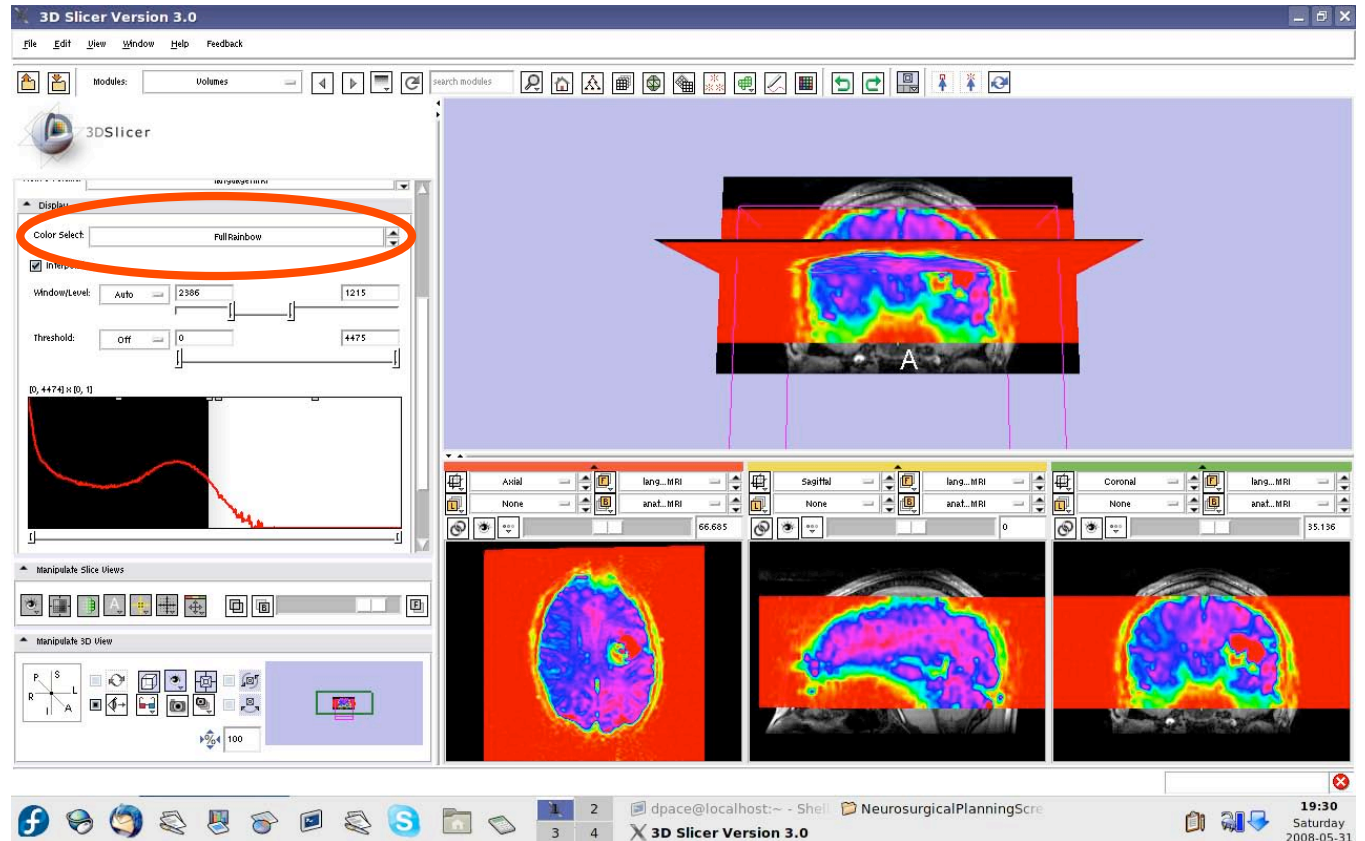
Expand the Display pane





Threshold image intensity

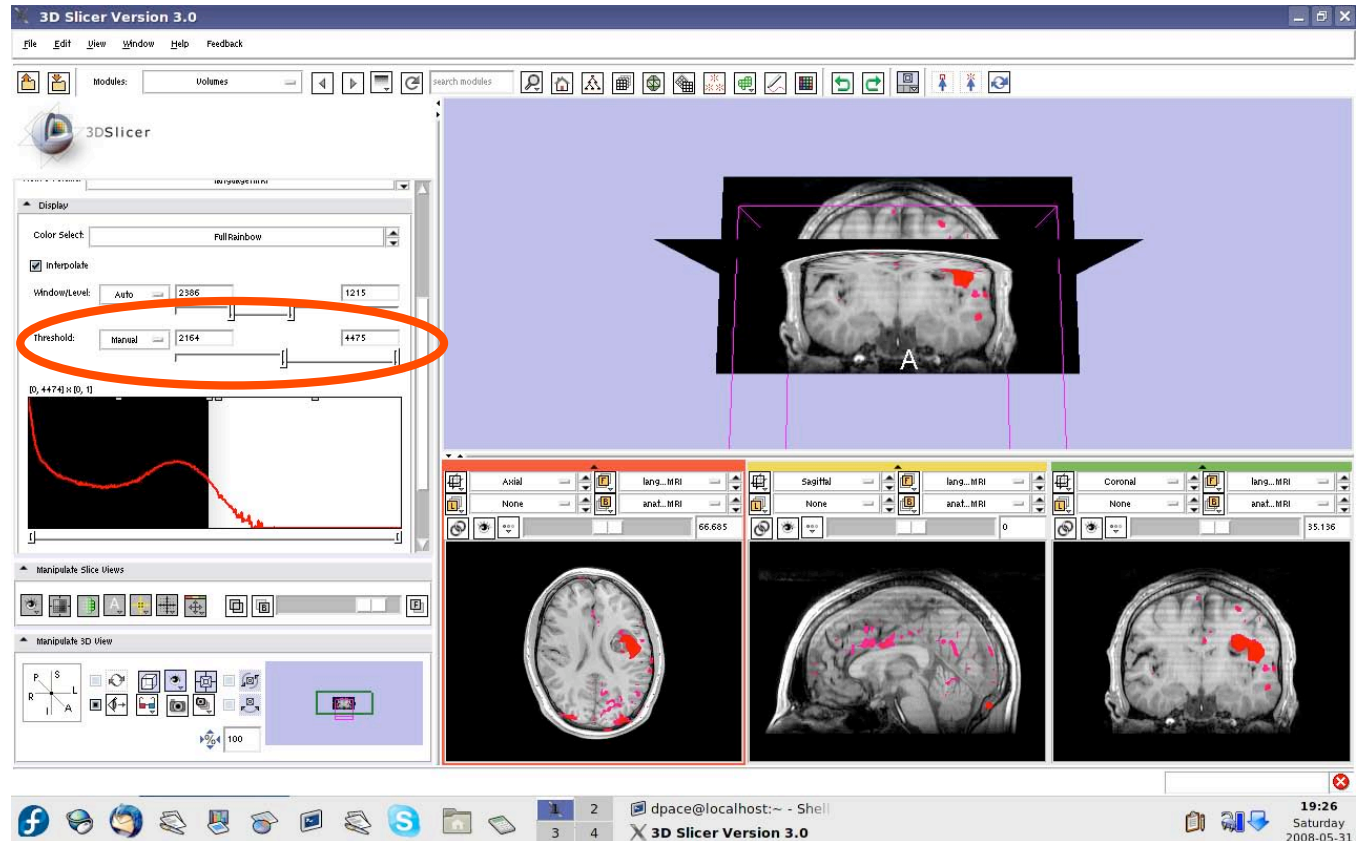
Set the Color to FullRainbow





Threshold image intensity

Set the threshold to Manual and adjust to highlight only high-intensity regions

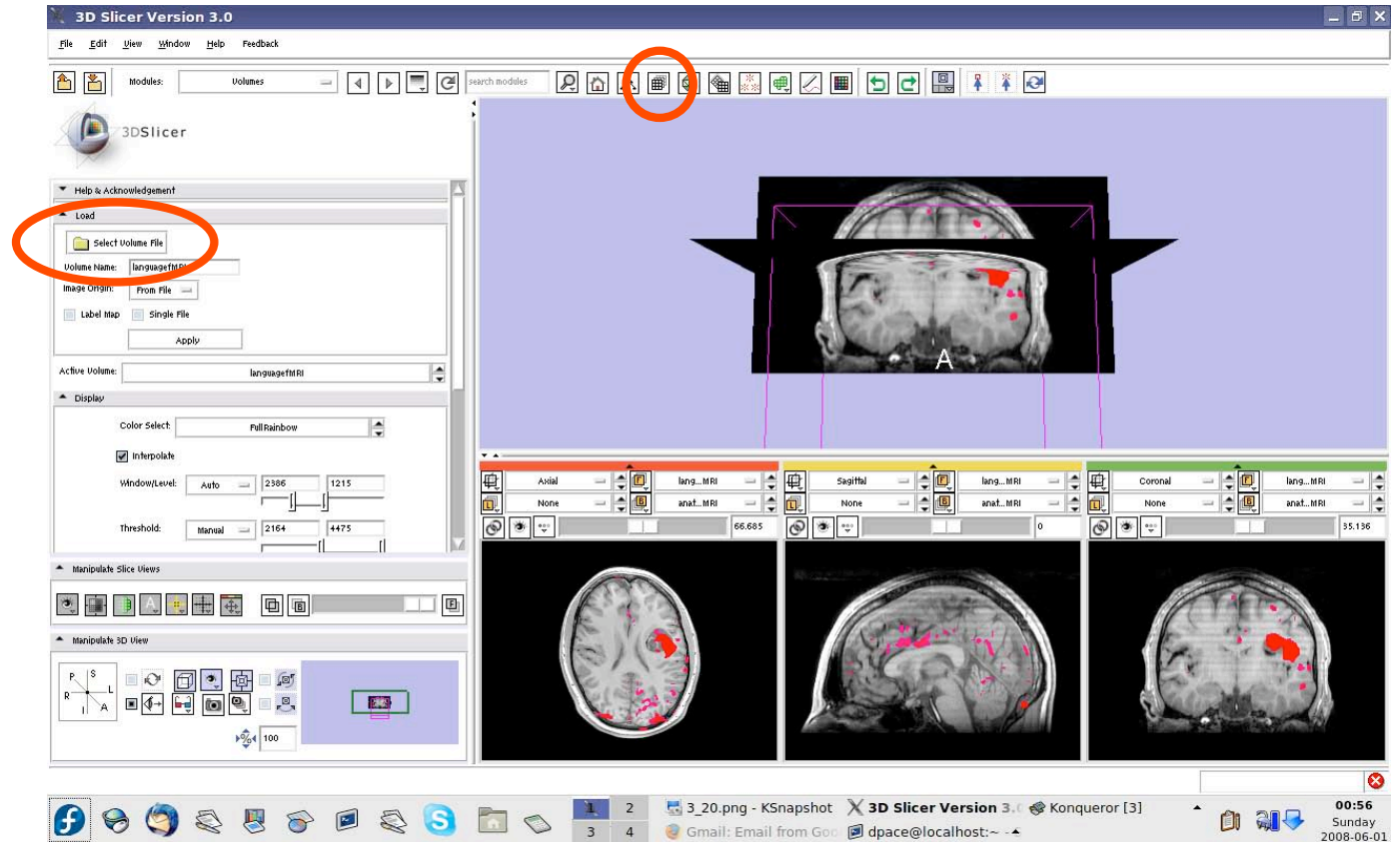




Load the motor fMRI data

Open the Volumes module

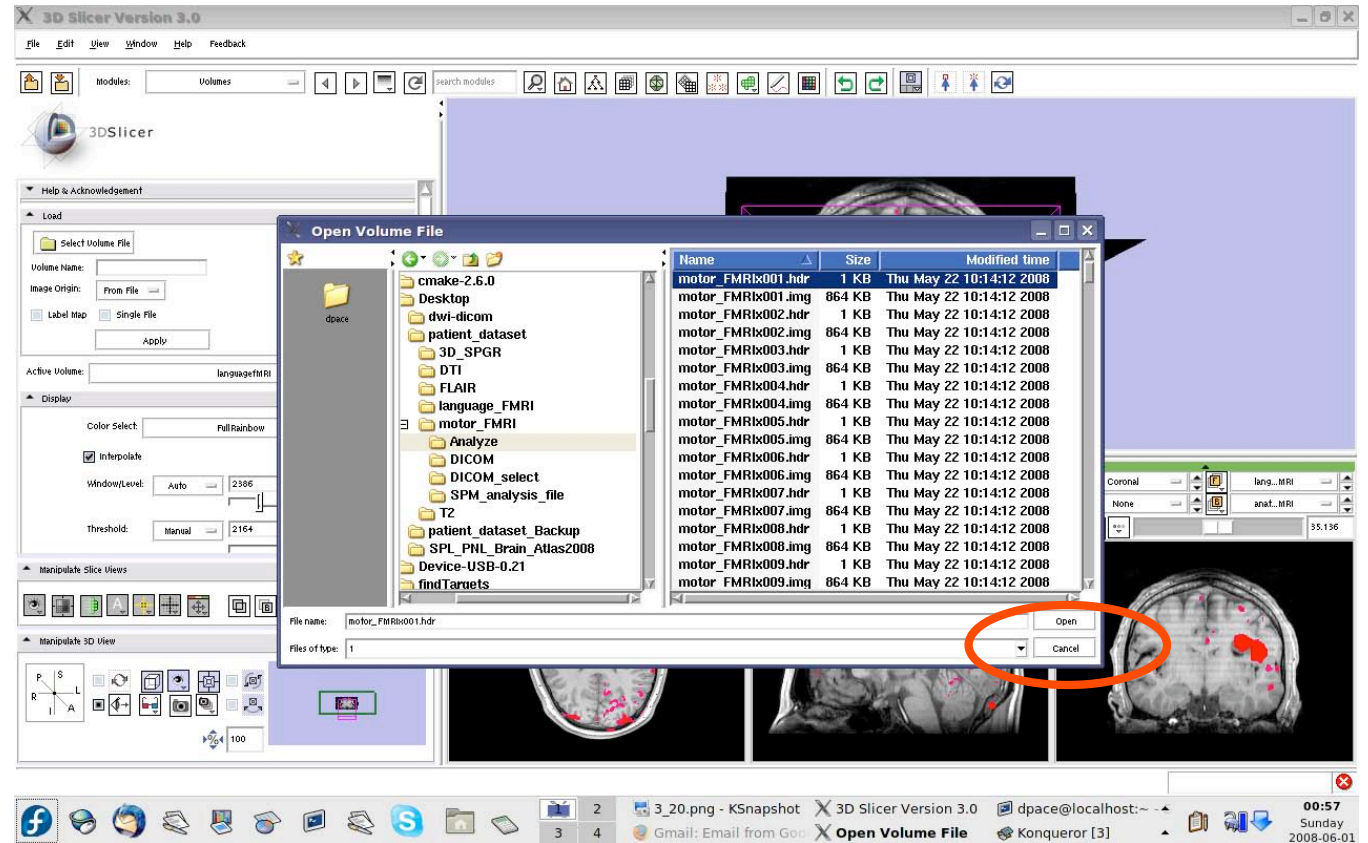
Click on “Select Volume File”





Load the motor fMRI data

Click on the first image in the Analyze folder within the motor_FMRI folder of the patient dataset, then click “Open”



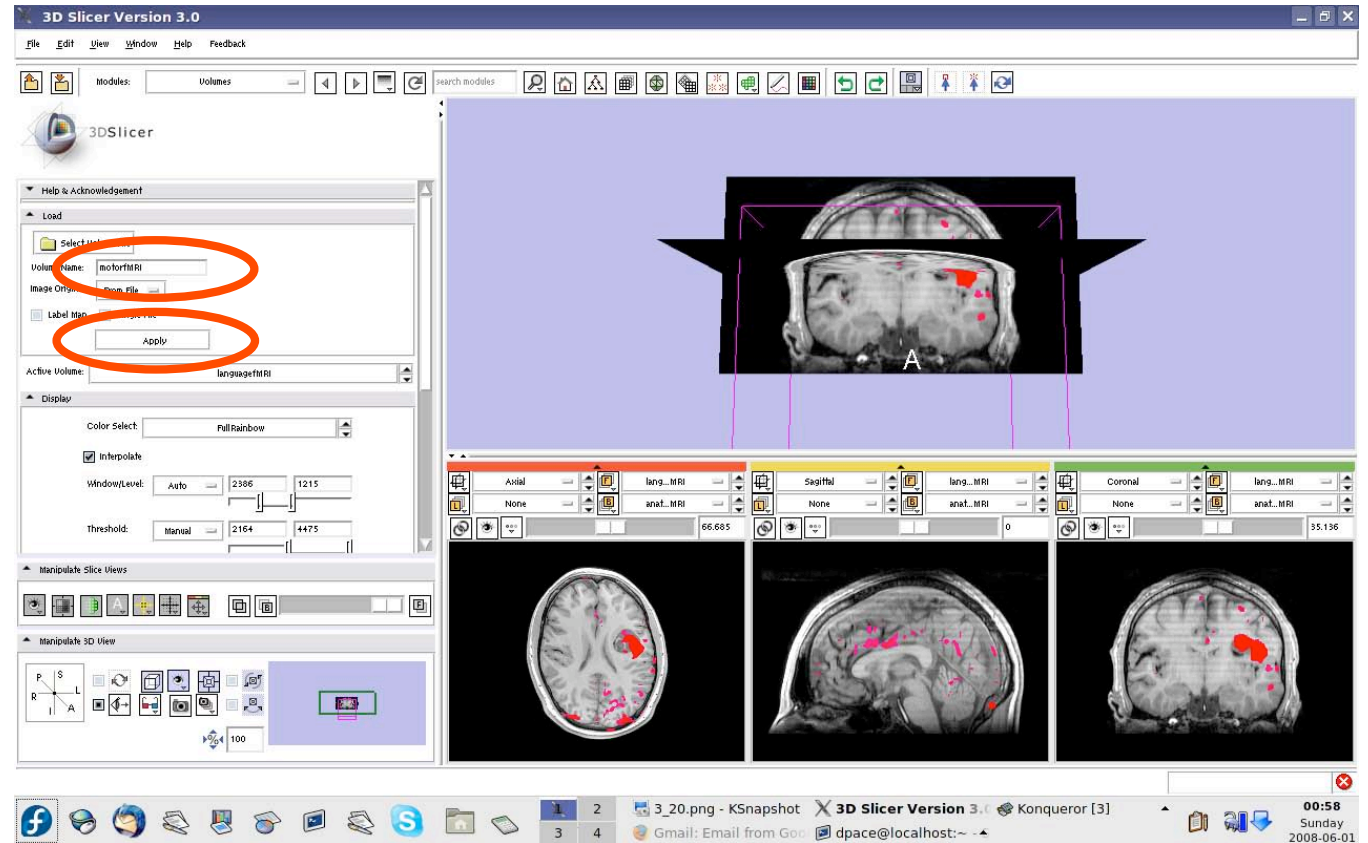


Load the motor fMRI data

Set the Volume Name to motorfMRI

Keep the image origin set to "From File"

Click on "Apply"



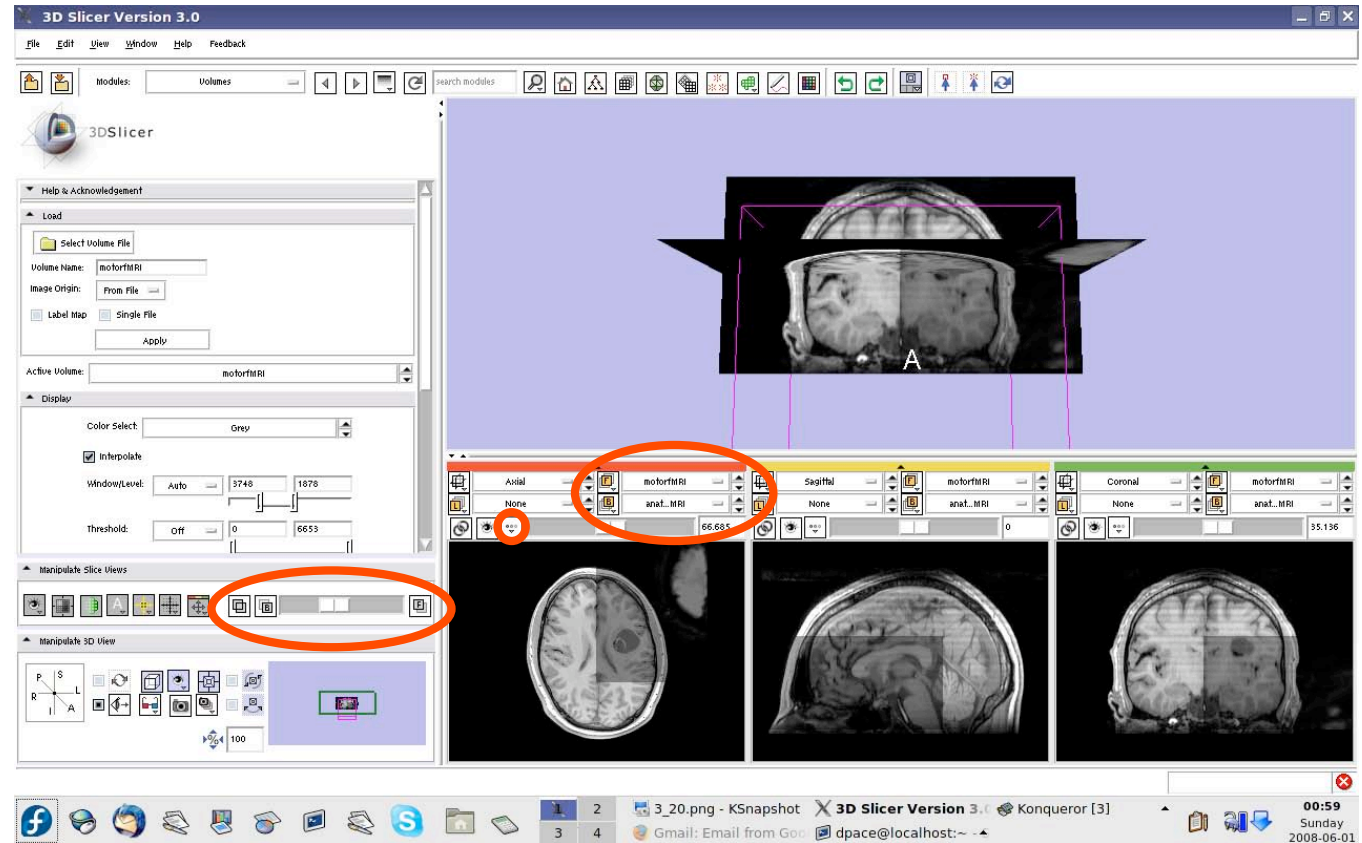


Load the motor fMRI data

Set the foreground to motorfMRI and the background to anatomicalMRI

Click on the “fit to window” button

Scale the opacities to see the foreground and background layers - the images are not aligned

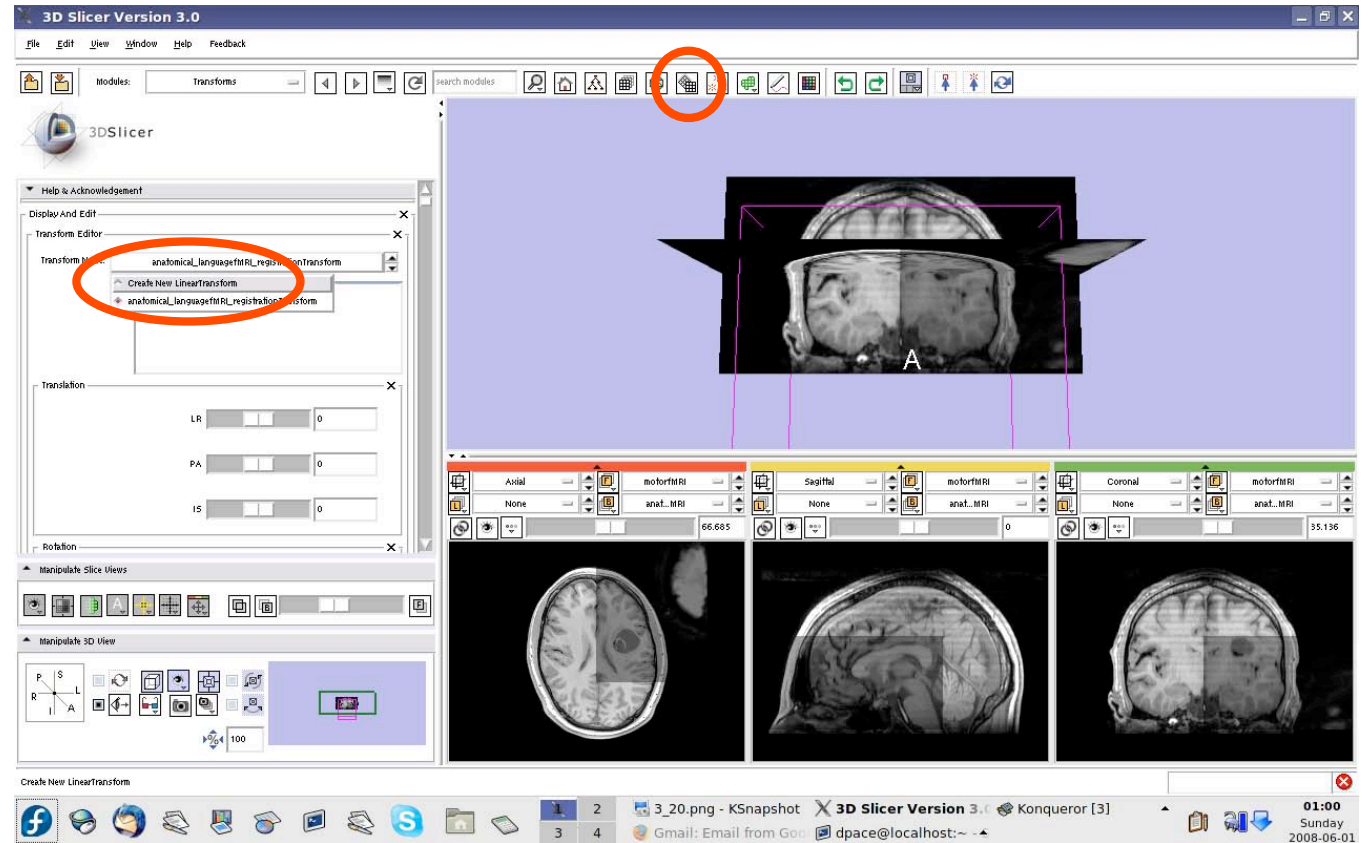




Initial manual transformation

Open the Transforms module

Create a new linear transform

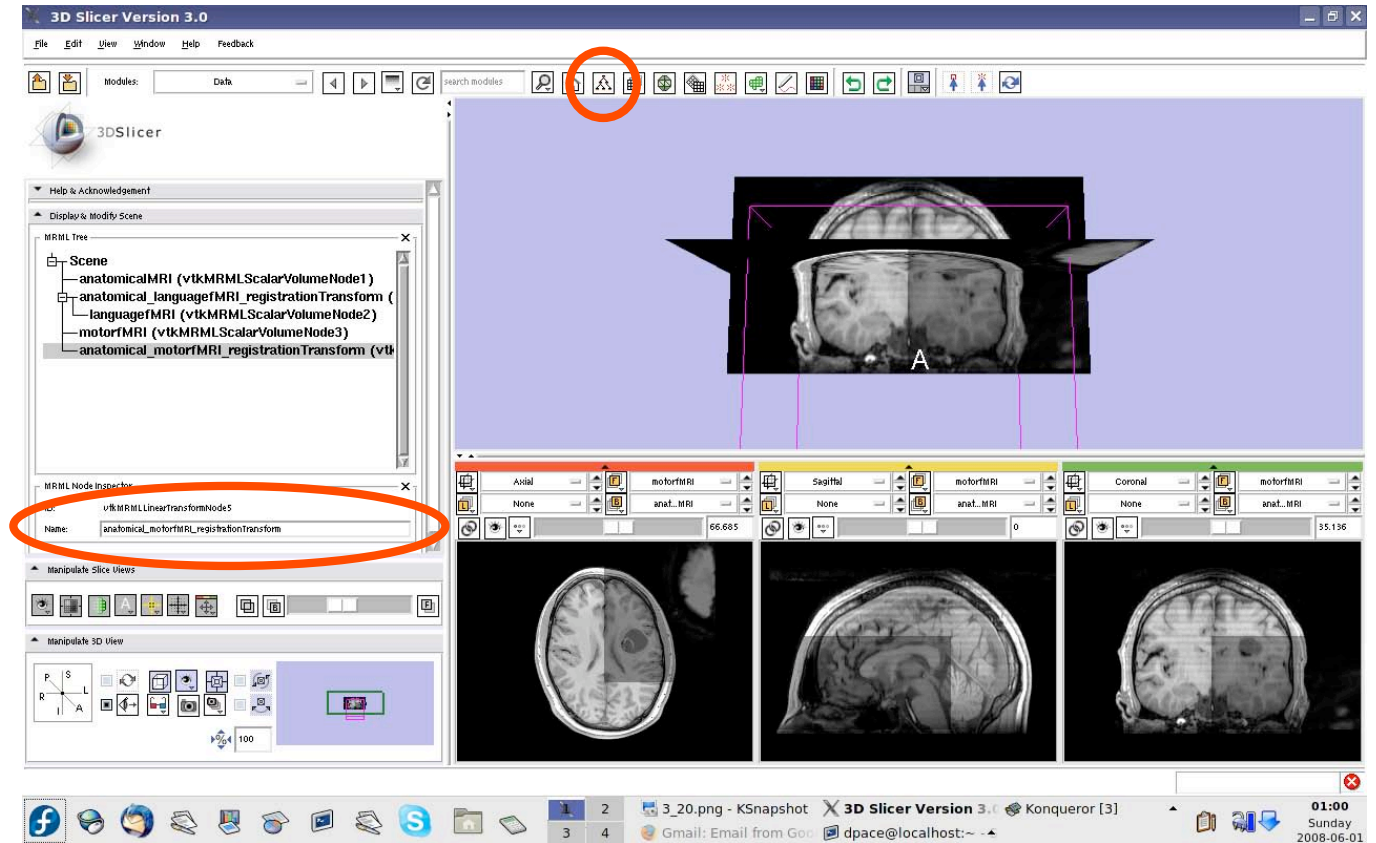




Initial manual transformation

Open the Data module

Change the name of the new transform to “anatomical_motorfMRI_registrationTransform”

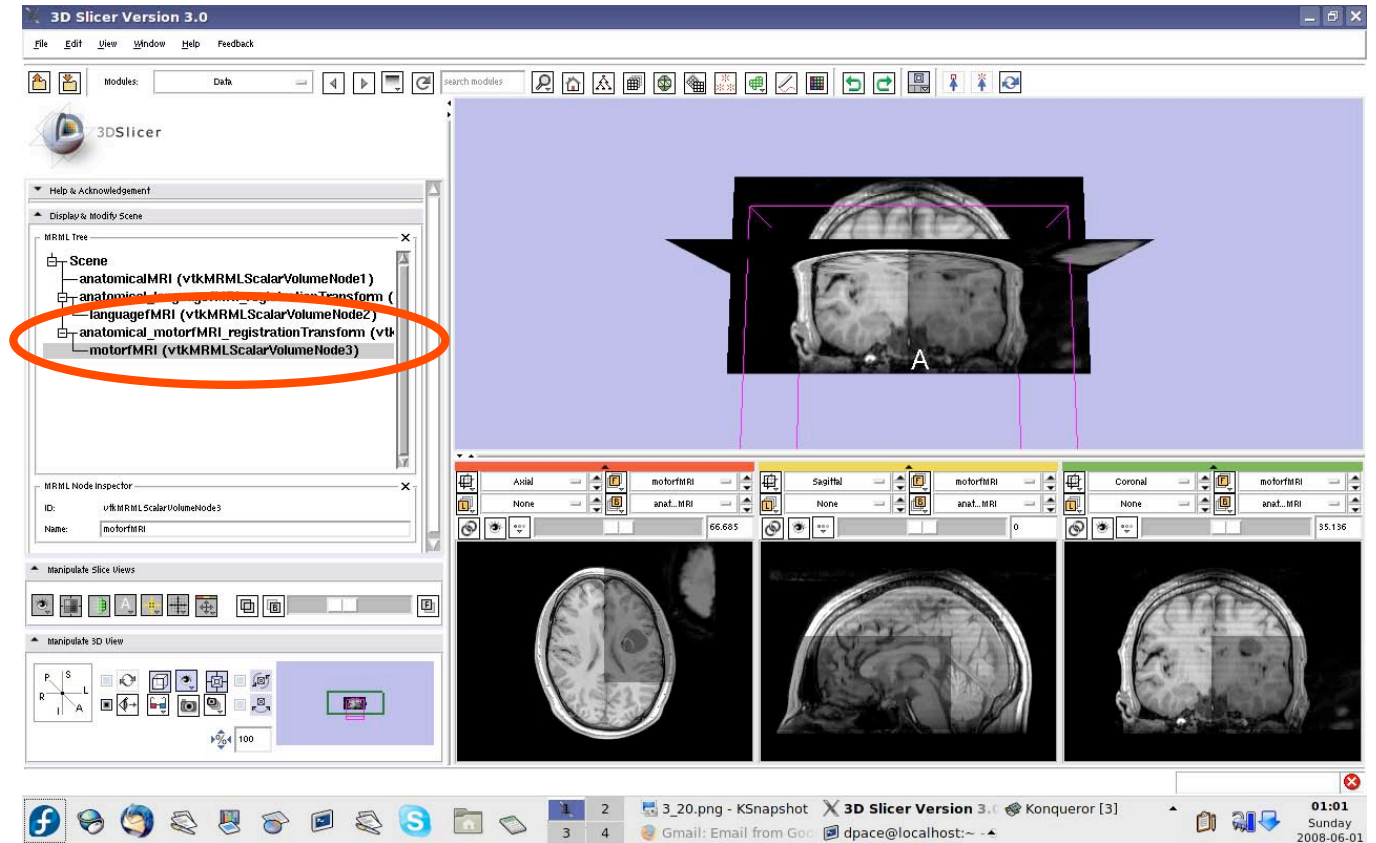




Initial manual transformation

Drag the motorfMRI node under the transform node

Now any changes to the transform node are applied to the motor fMRI image volume

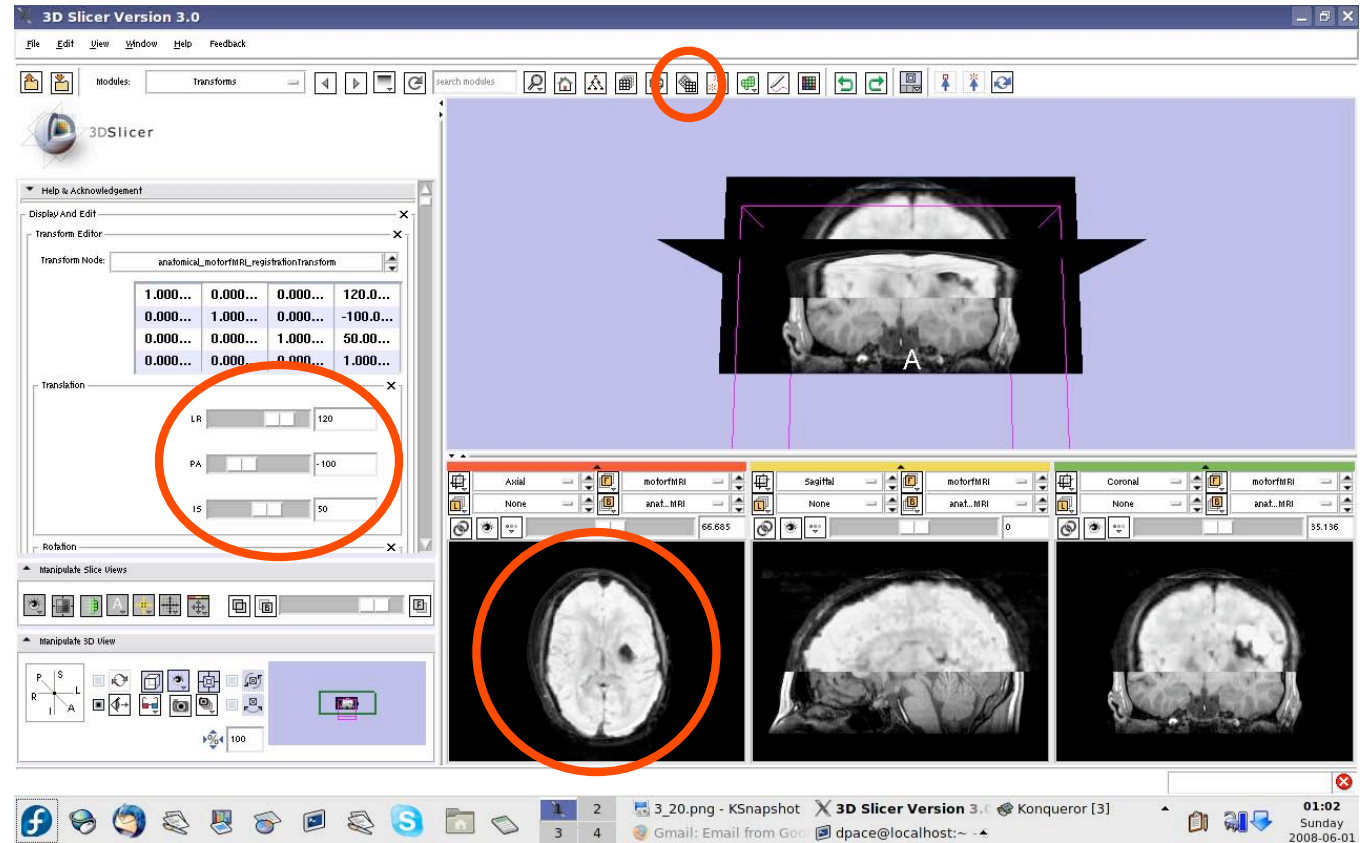




Initial manual transformation

Open the Transforms module

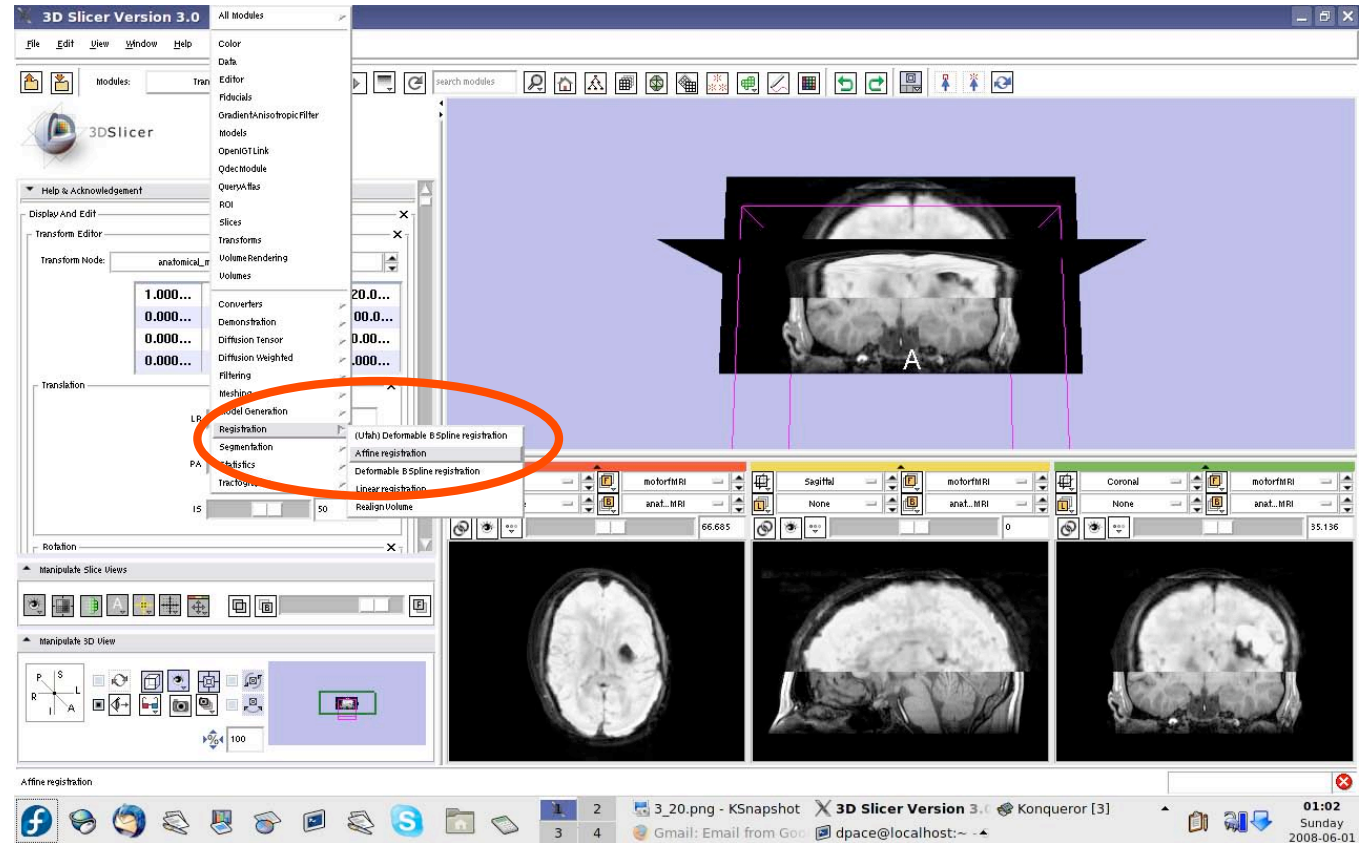
Adjust the translation components to roughly align the two image volumes in the axial plane





Automatic affine registration

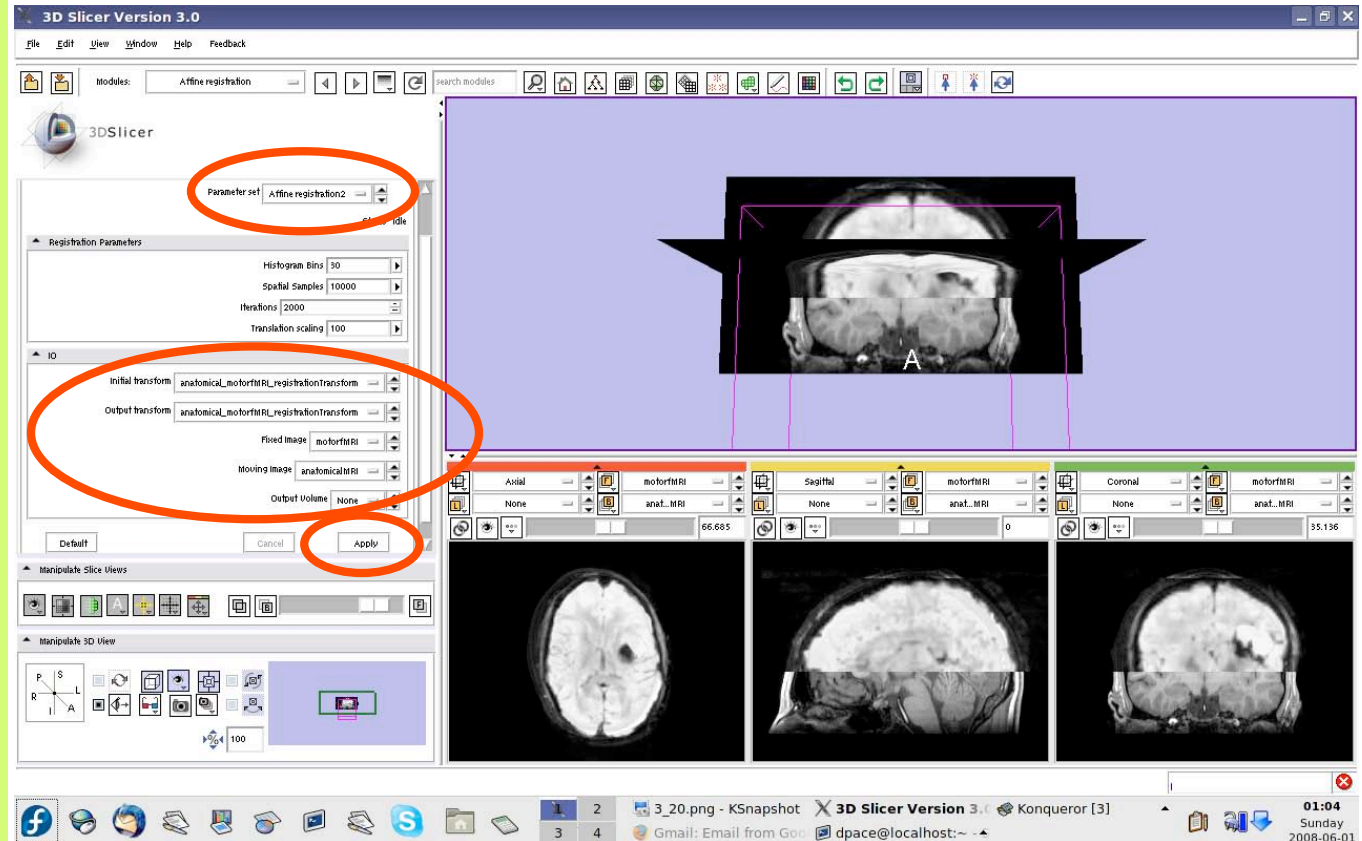
Open the
Affine
Registration
module





Automatic affine registration

- Parameter set = Create new CommandLine Module
- Initial transform = anatomical_motor fMRI_registration Transform
- Output transform = anatomical_motor fMRI_registration Transform
- Fixed Image = motor fMRI
- Moving Image = anatomical MRI
- Output Volume = None



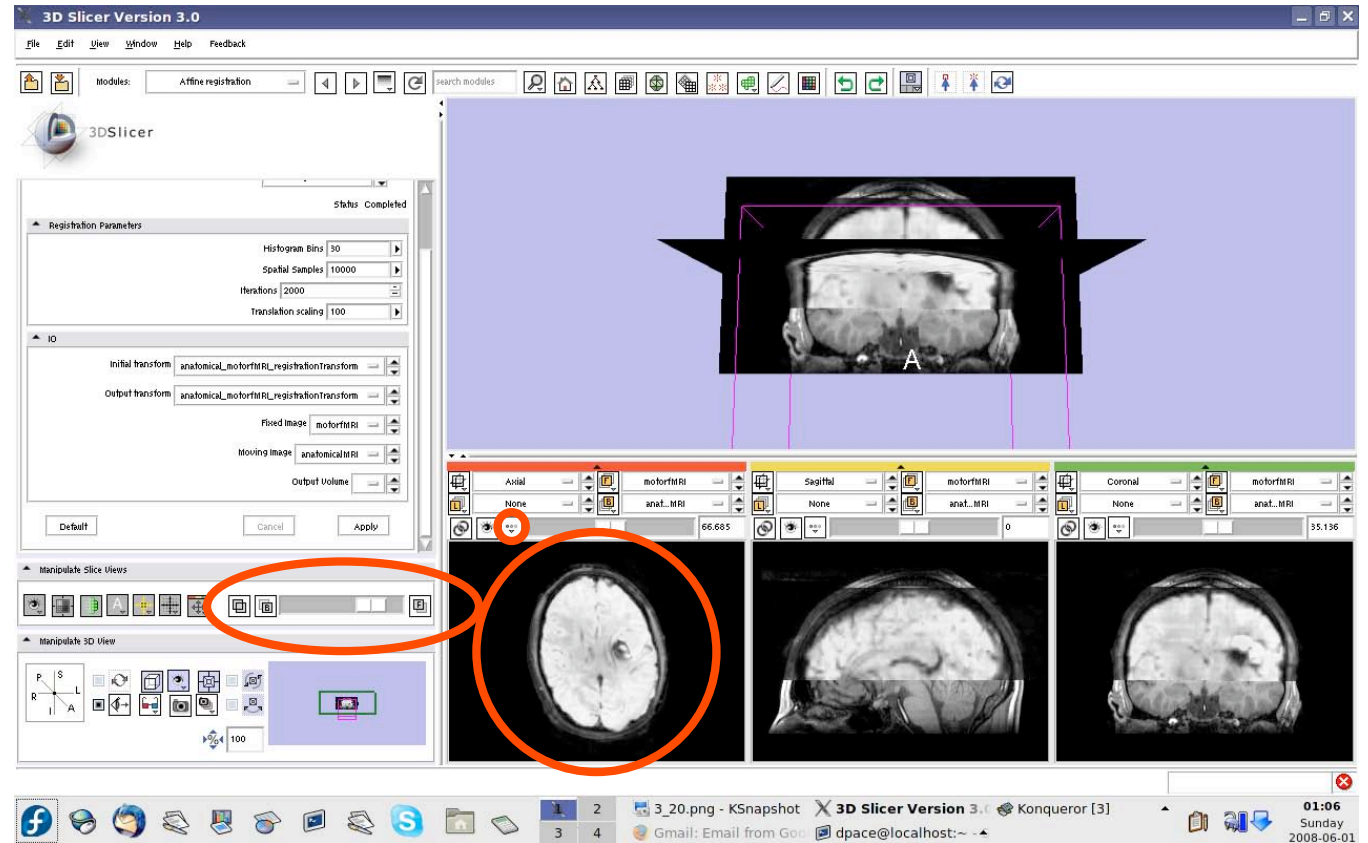
Click “Apply”



Automatic affine registration

Click on the “fit to window” button

Scale the opacities to see that the images are aligned





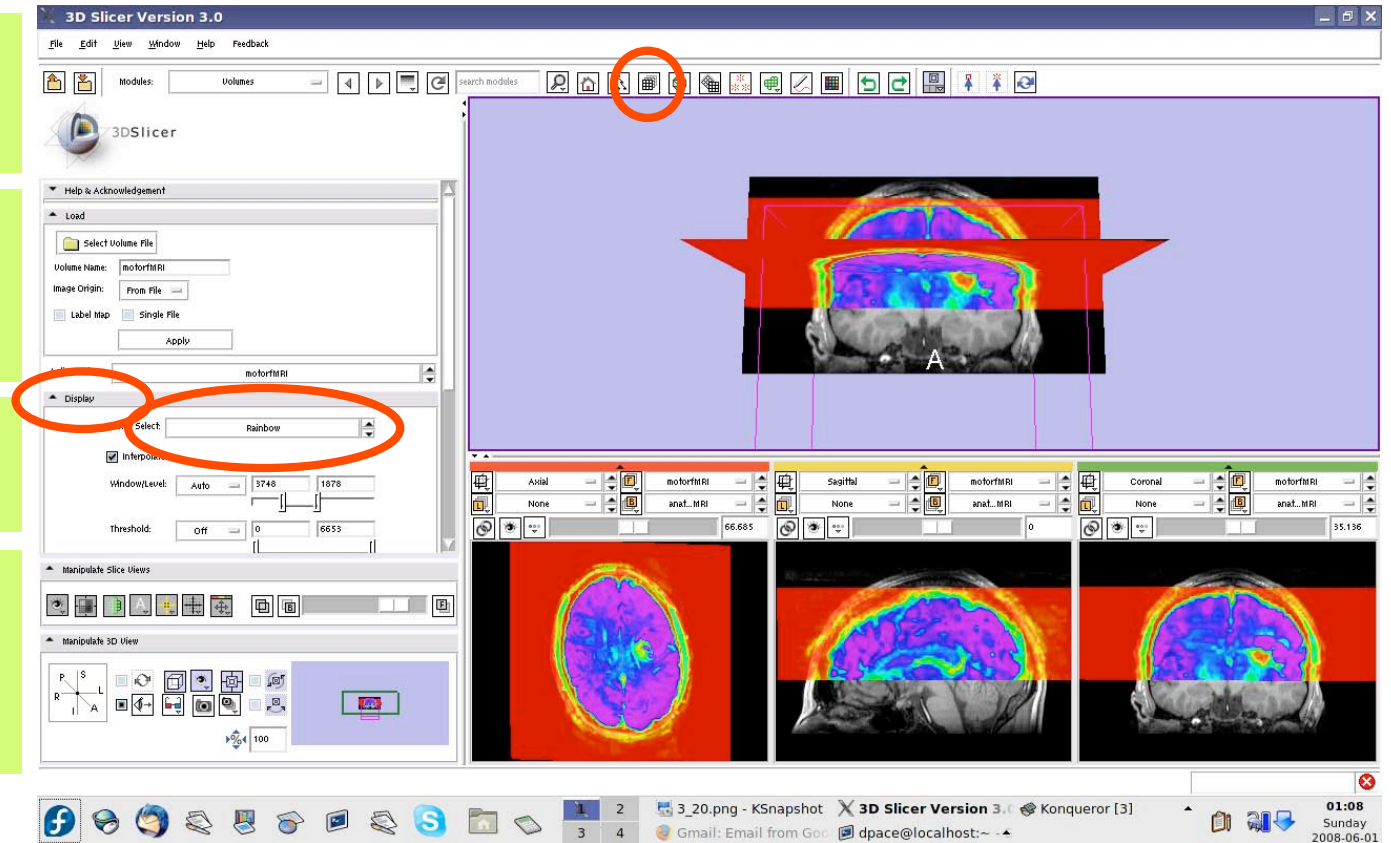
Threshold image intensity

Open the Volumes module

Set the active volume to motorfMRI

Expand the Display pane

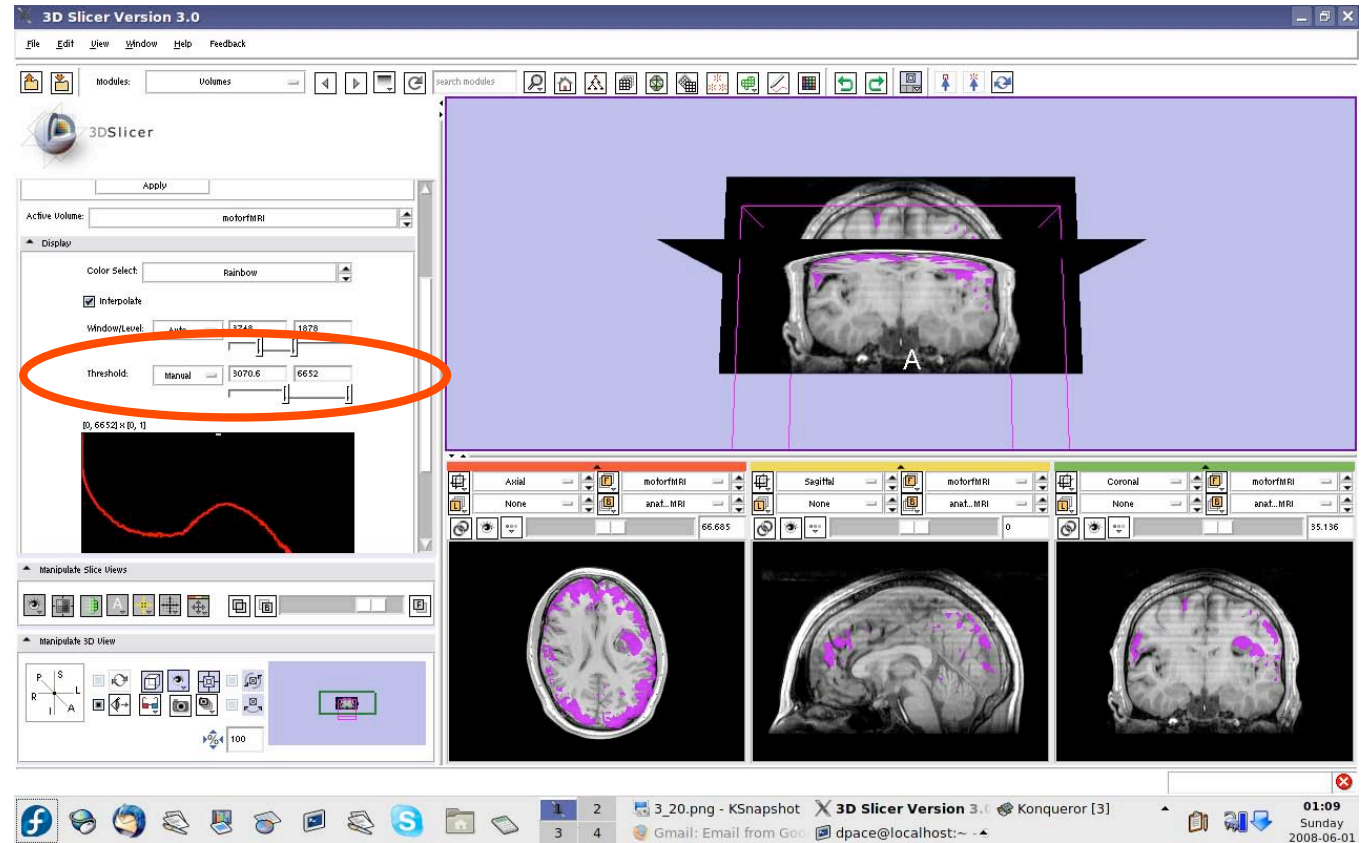
Set the Color to Rainbow





Threshold image intensity

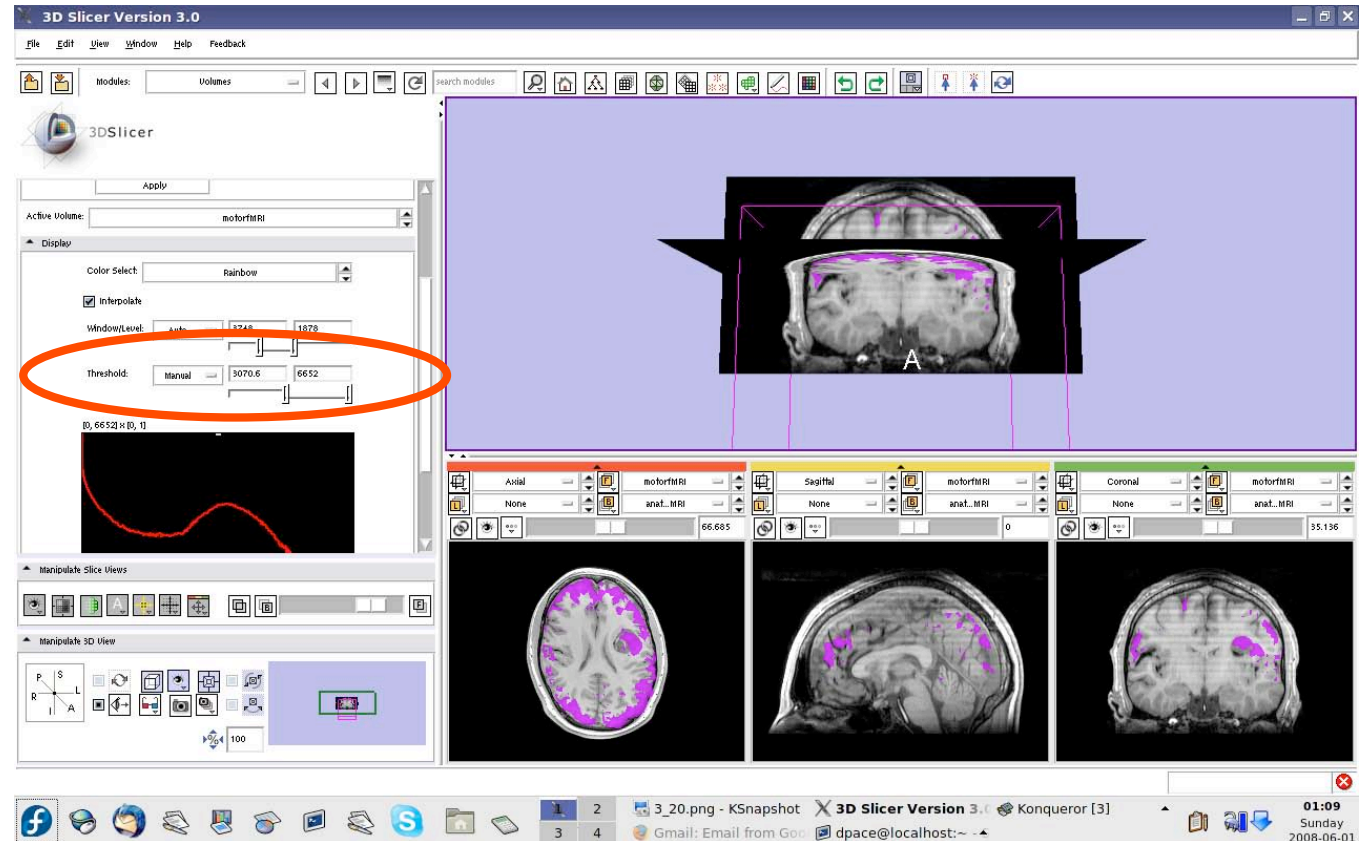
Set the threshold to Manual and adjust to highlight only high-intensity regions





Threshold image intensity

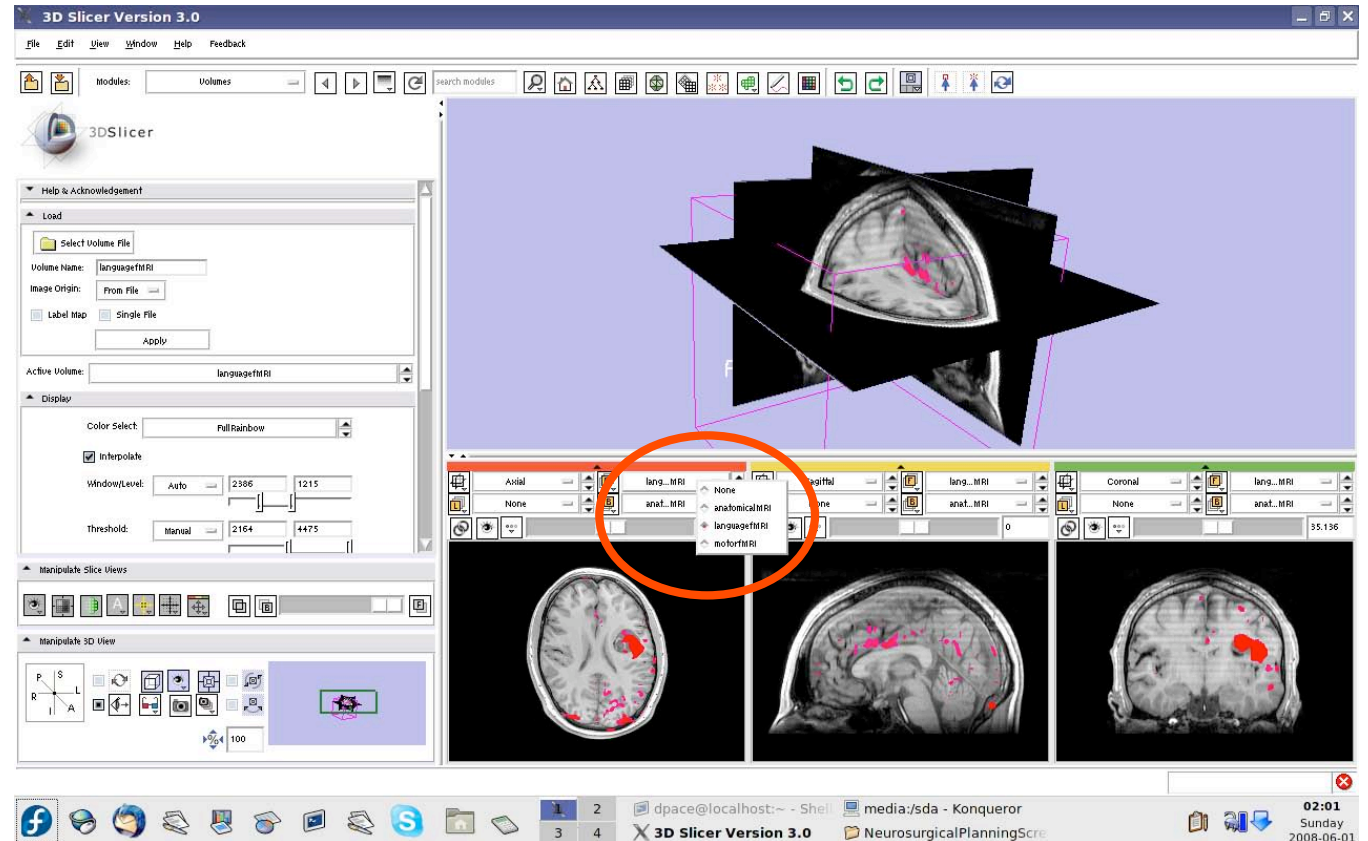
Set the threshold to Manual and adjust to highlight only high-intensity regions





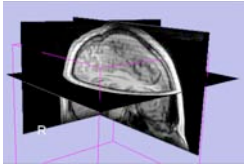
View both sets of fMRI data

Toggle between the language fMRI and motor fMRI datasets by changing the foreground image

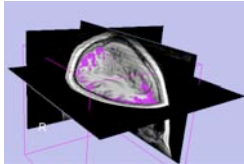




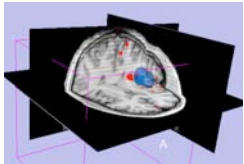
Overview



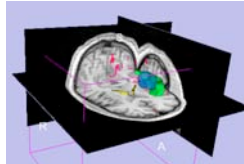
1. Loading and visualizing anatomical MRI data



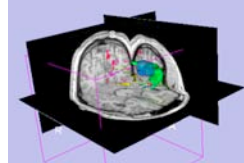
2. Incorporating fMRI data using image registration and thresholding



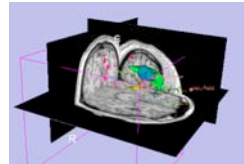
3. Creating a 3D model of the tumour volume



4. Predicting the locations of brain structures using image registration and a brain atlas



5. Incorporating brain fiber tractography from diffusion weighted images

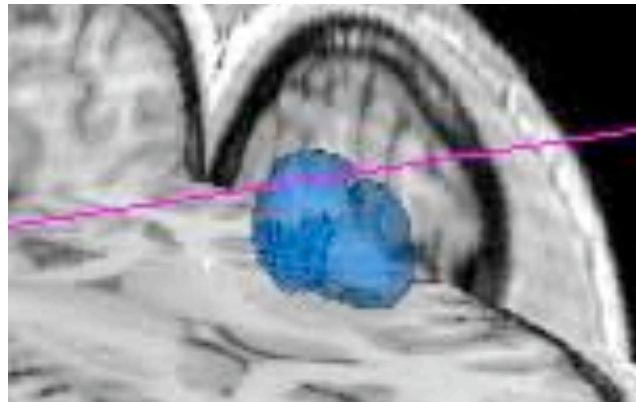


6. Annotating the preoperative plan and saving the scene



Model Making in Slicer3

- **Utility of model making in IGT:**
 - View the structure as a complete unit (instead of slice by slice)
 - Perform measurements, such as volume measurements, that can be difficult to perform on the image volume itself





Model Making in Slicer3

- **Steps involved in this section:**

Place a seed point on the tumour in the anatomical MRI

Segment the tumour volume in the anatomical MRI

Create the tumour model using Slicer3's ModelMaker

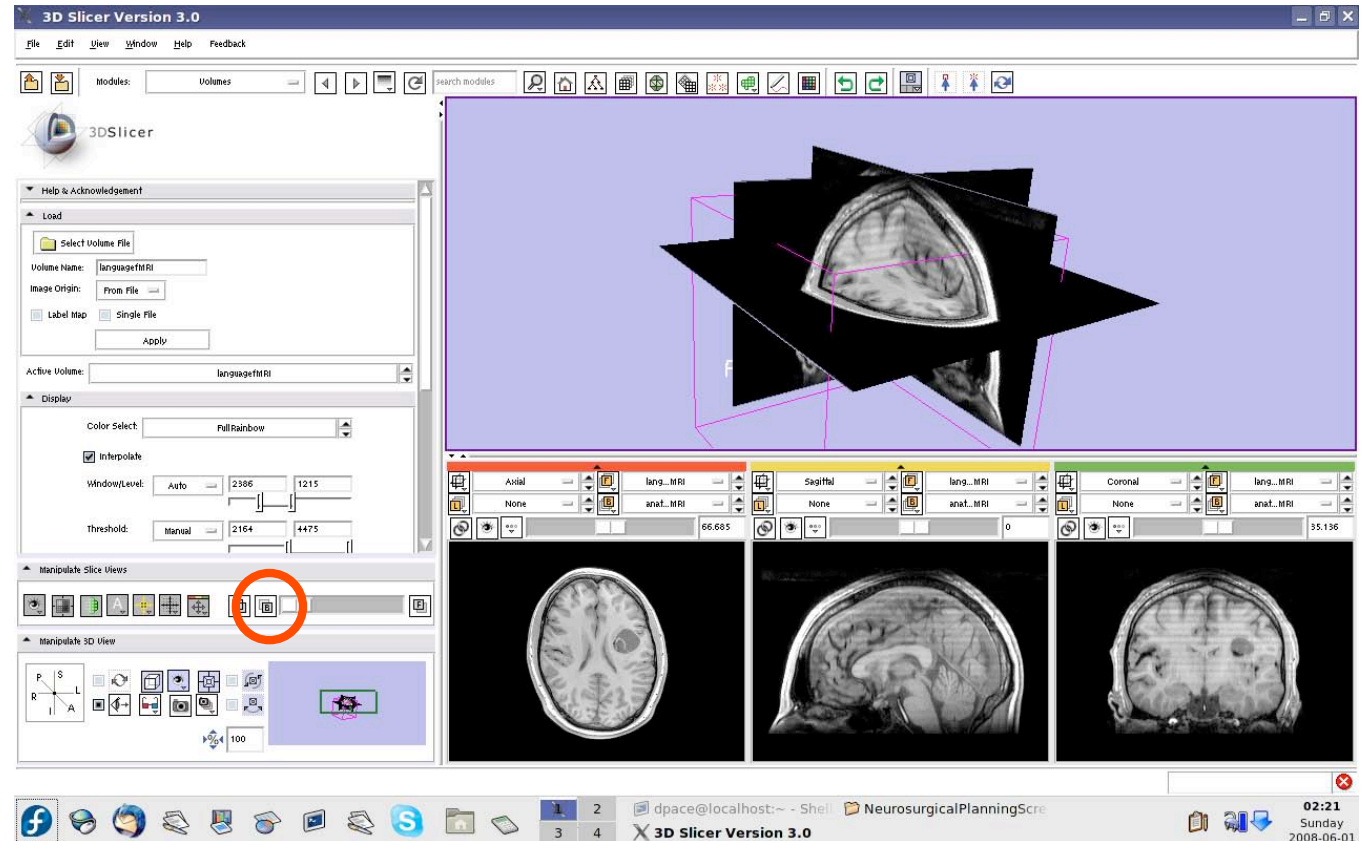
Change the tumour model's appearance

Save the tumour model



Place the seed point

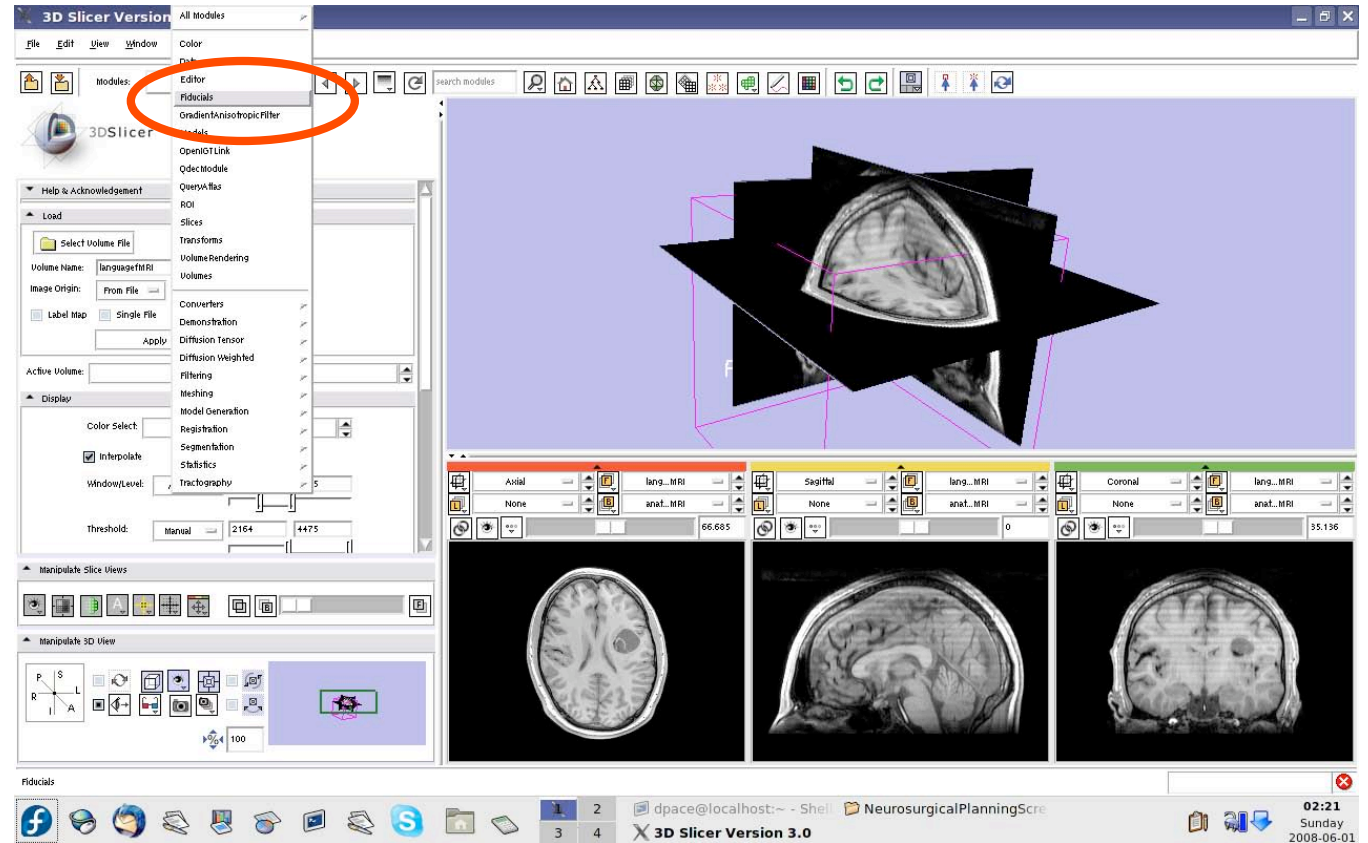
Click on the Background layer button to show the anatomical MRI alone





Place the seed point

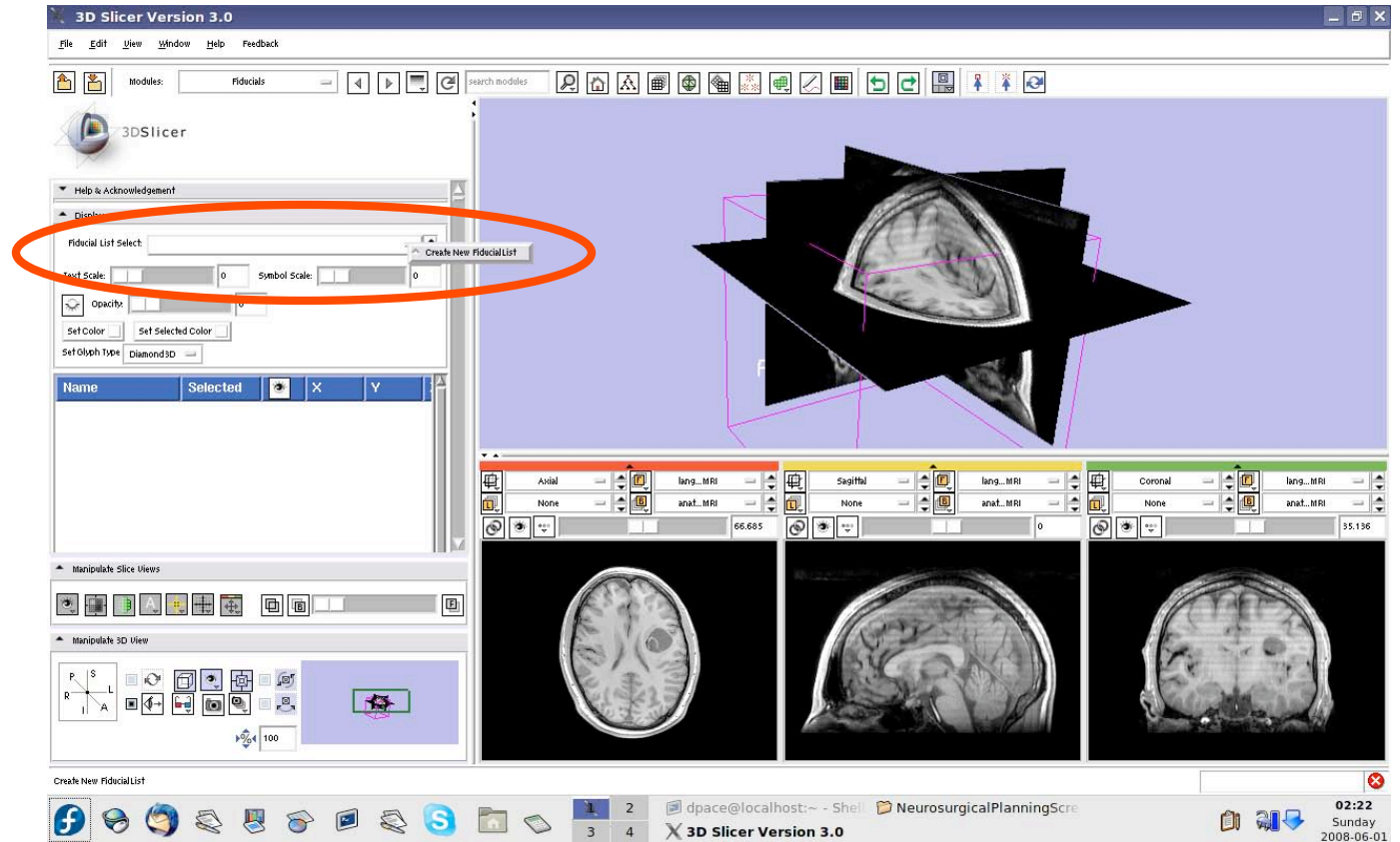
Open the
Fiducials
module





Place the seed point

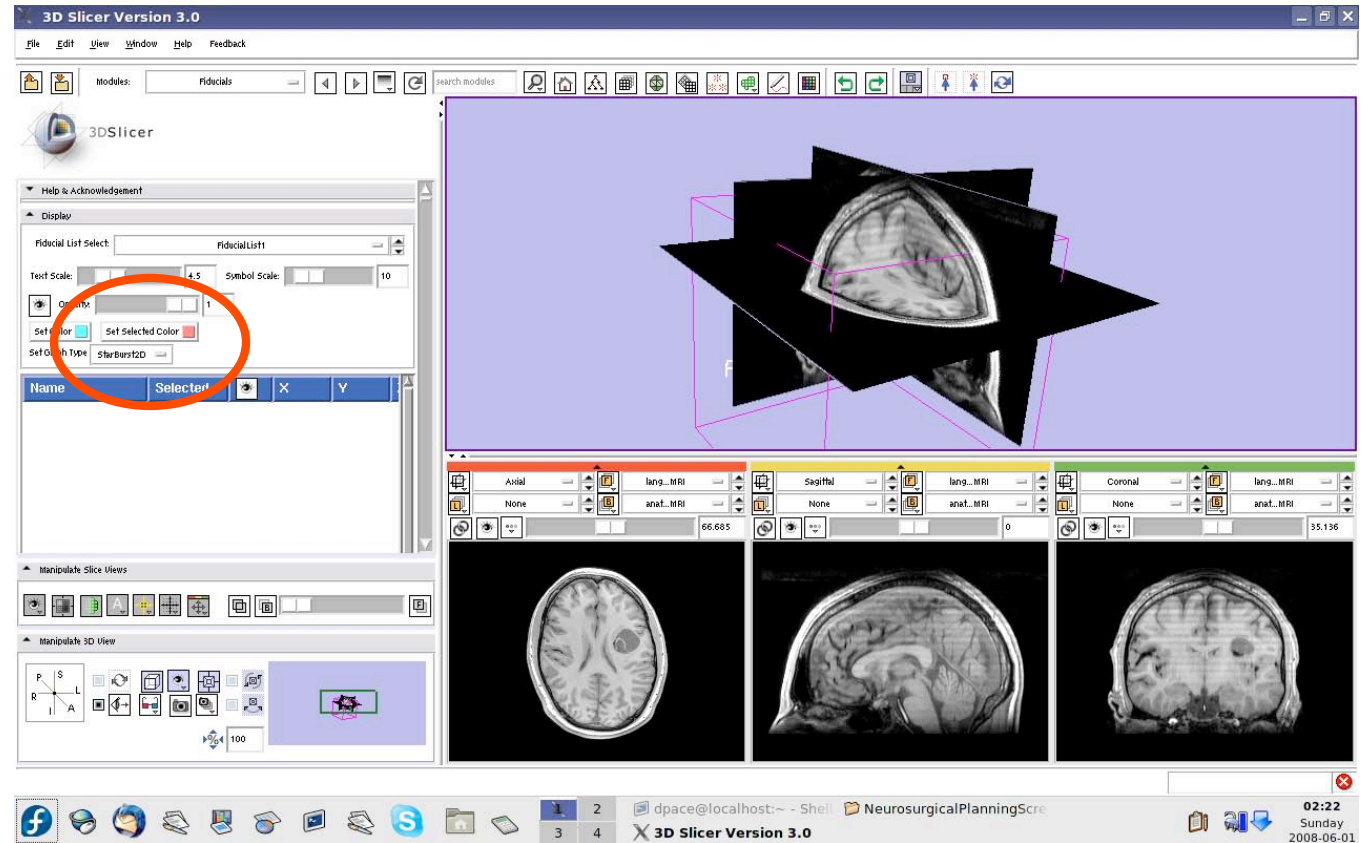
Create a new Fiducial List





Place the seed point

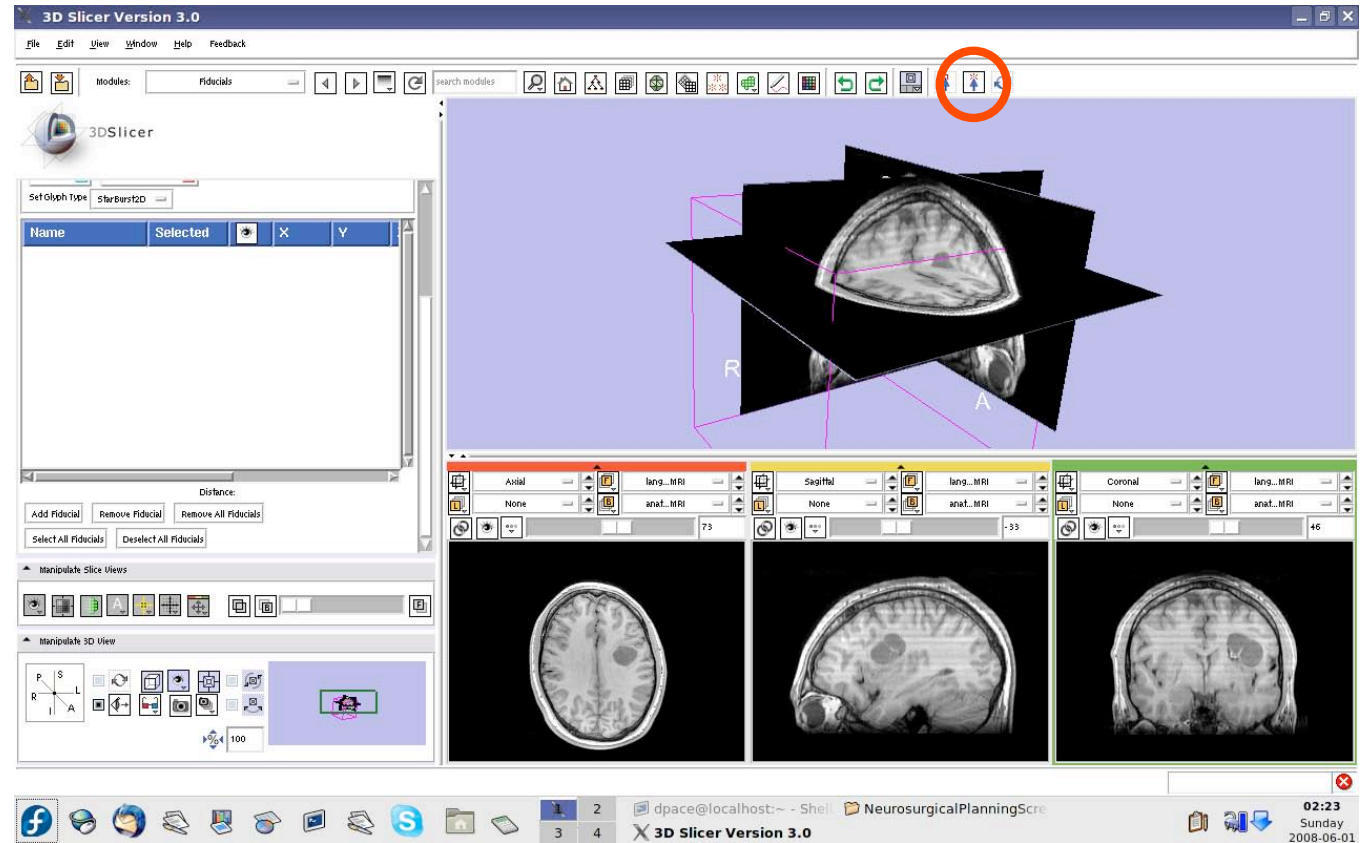
The fiducial will show up as a pink starburst





Place the seed point

Set the mouse mode to “place items”

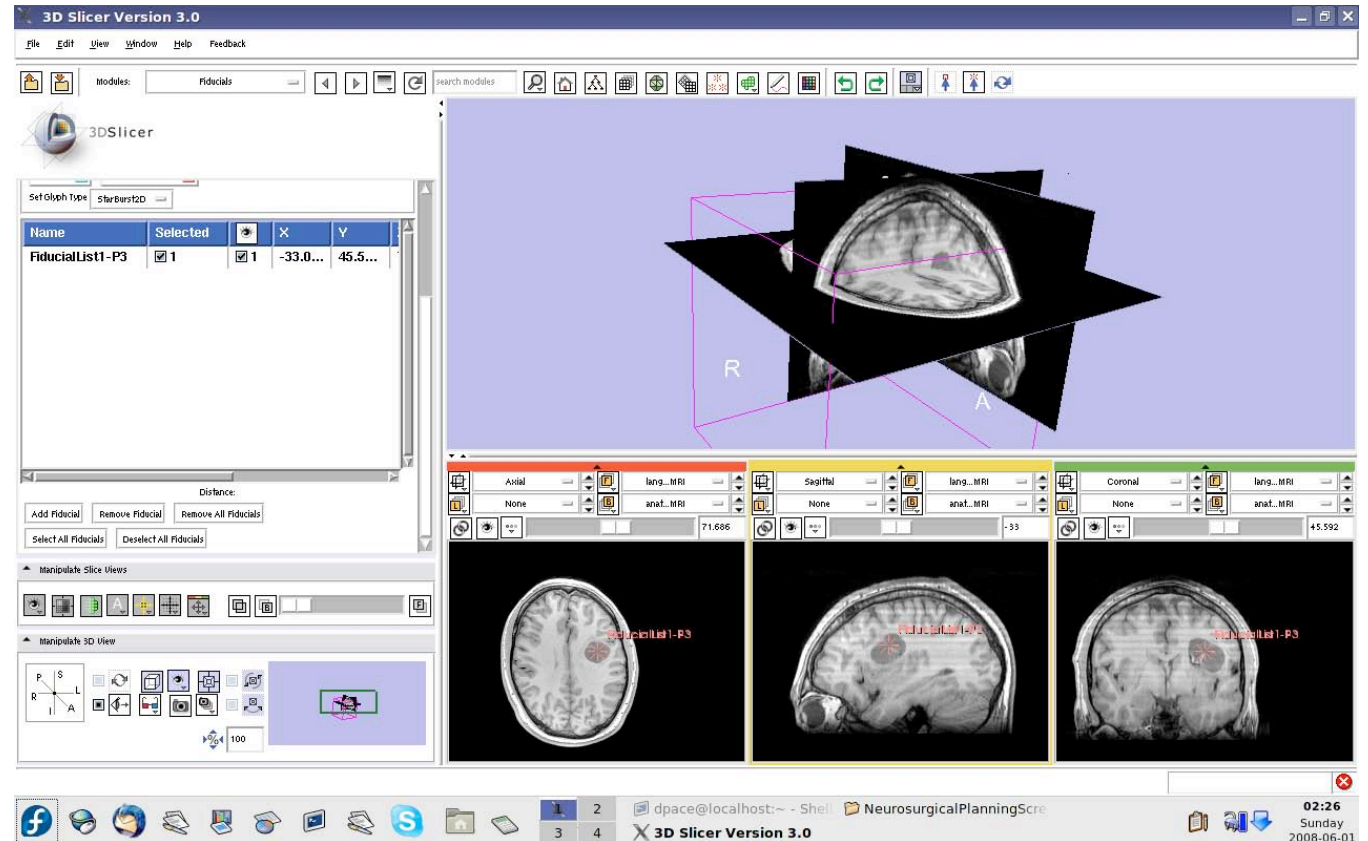




Place the seed point

Slice through the image volume until you see the tumour in all three views

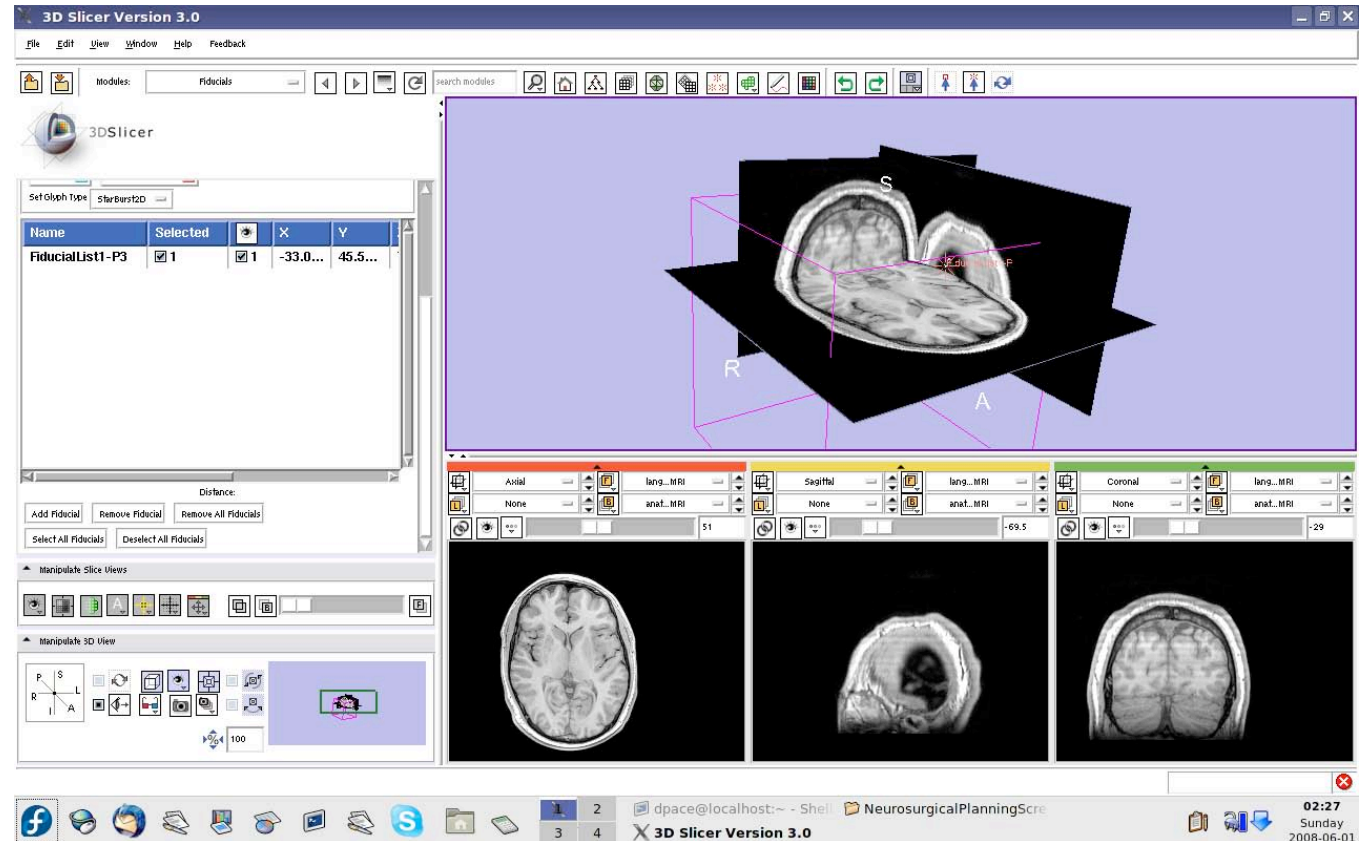
Click once to place the seed





Place the seed point

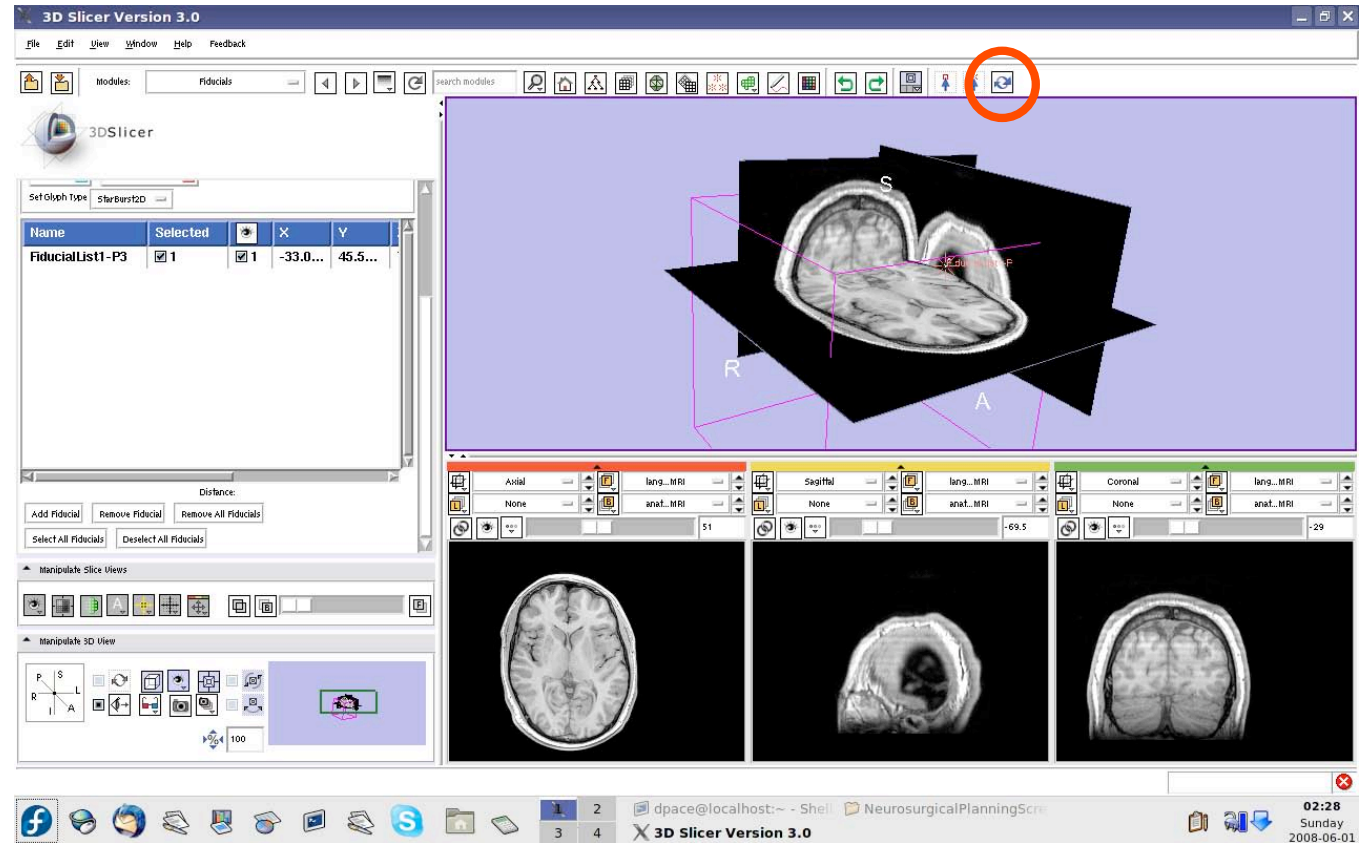
The fiducial can also be seen in the 3D Viewer





Place the seed point

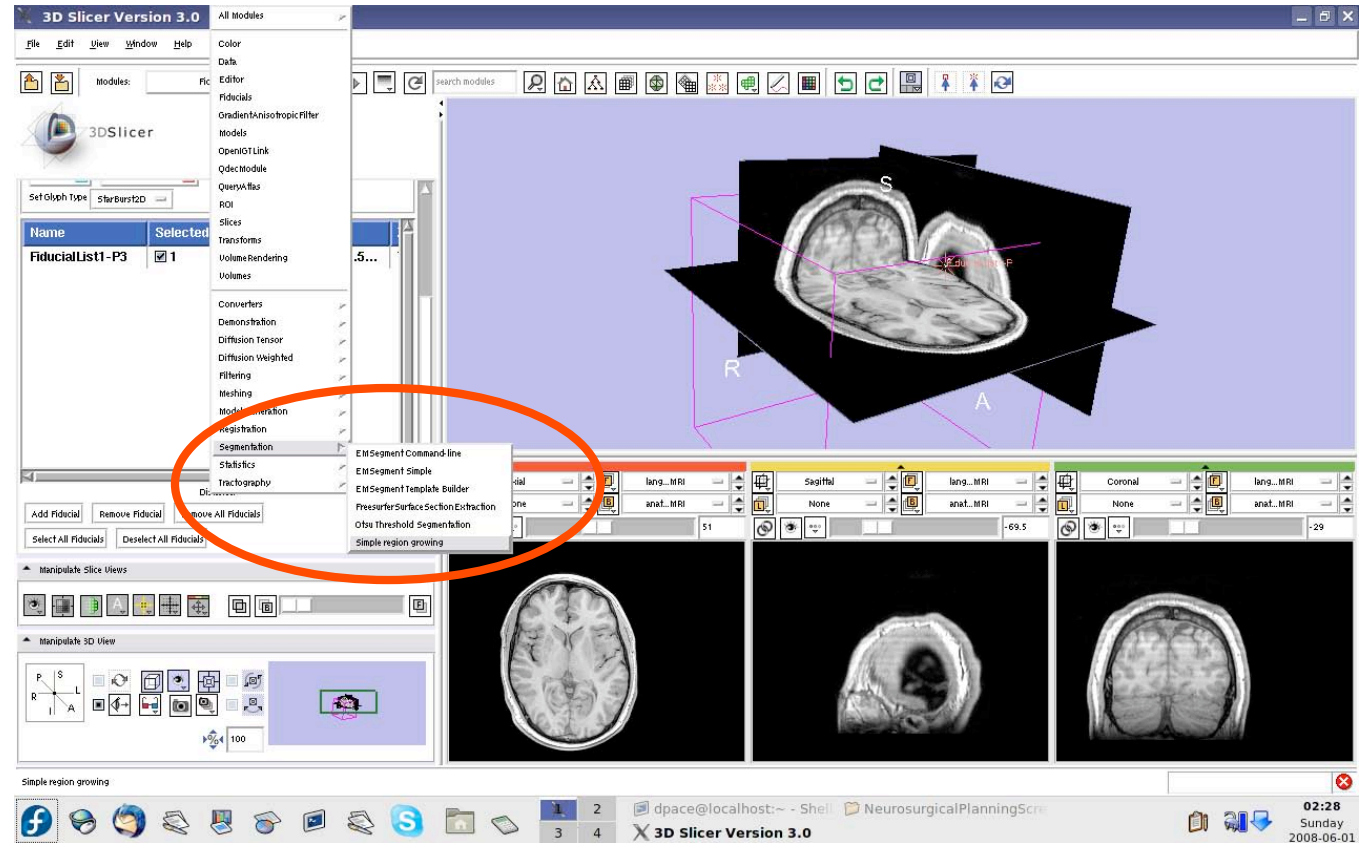
Set the mouse mode to “transform view”





Segment the tumour volume

Open the Simple Region Growing module

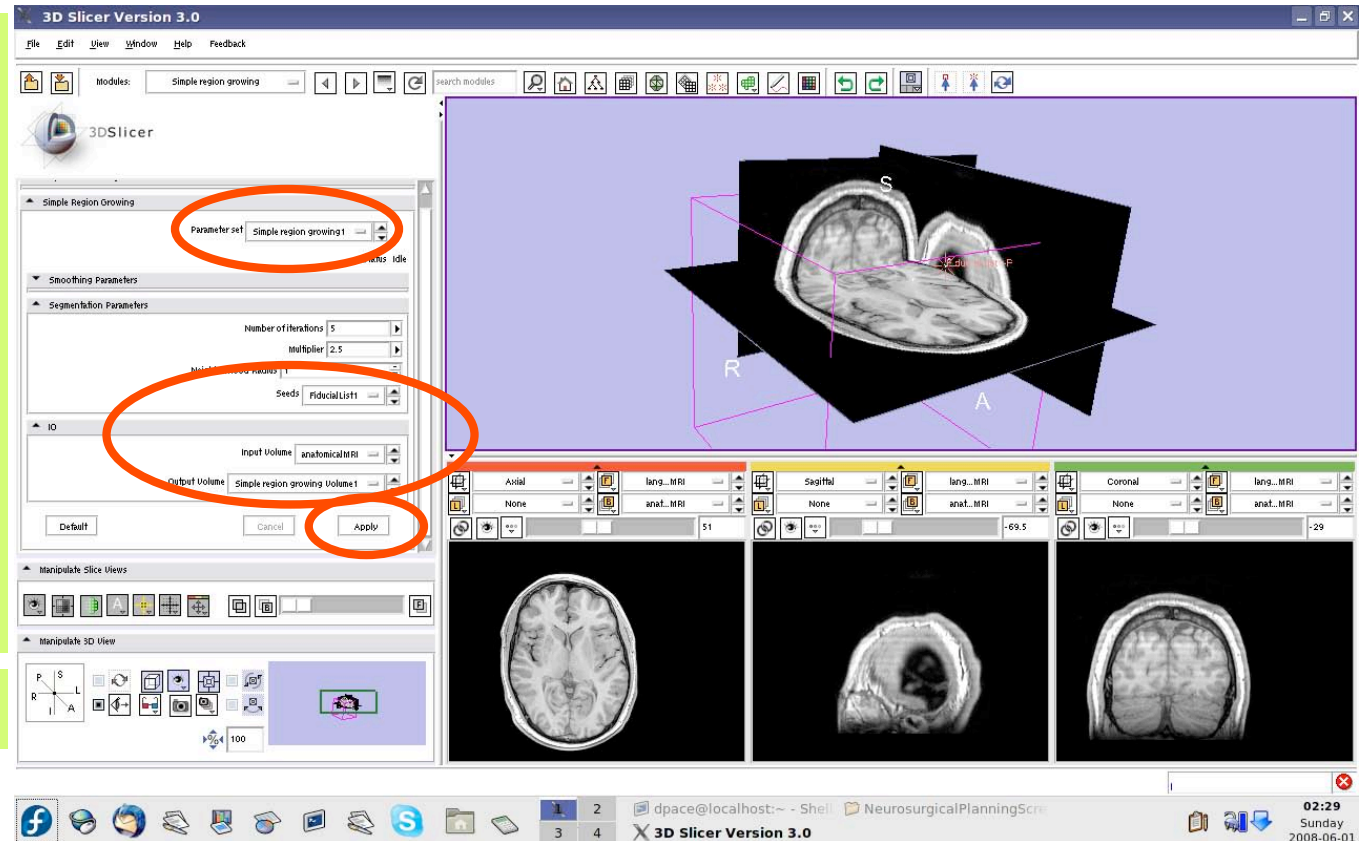




Segment the tumour volume

- Parameter set = Create new CommandLine Module
- Seeds = FiducialList1
- Input Volume = anatomicalMRI
- Output Volume = Simple region growing Volume1
- Create New Volume

Click "Apply"



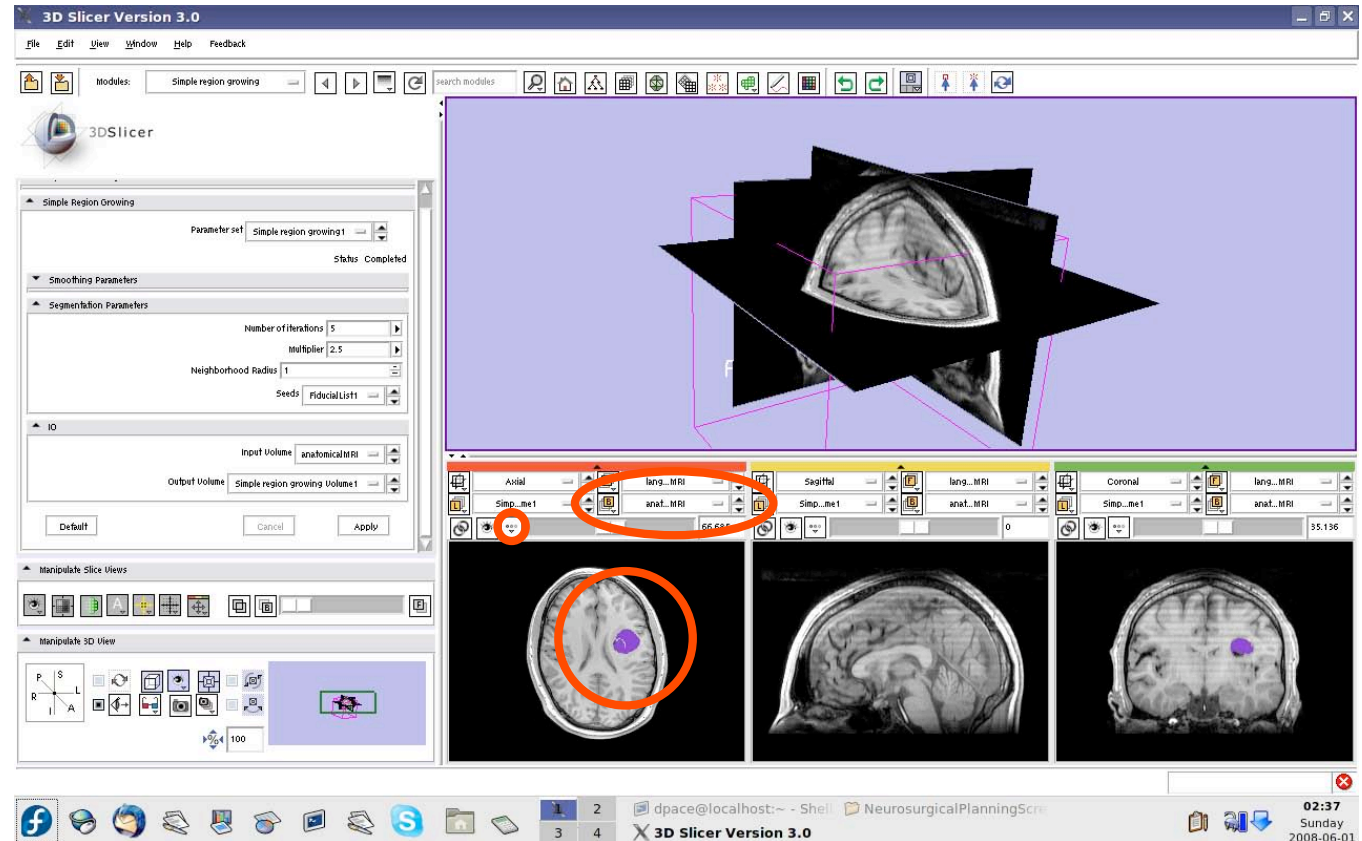


Segment the tumour volume

Set the background to anatomicalMRI

Click on the “fit to window” button

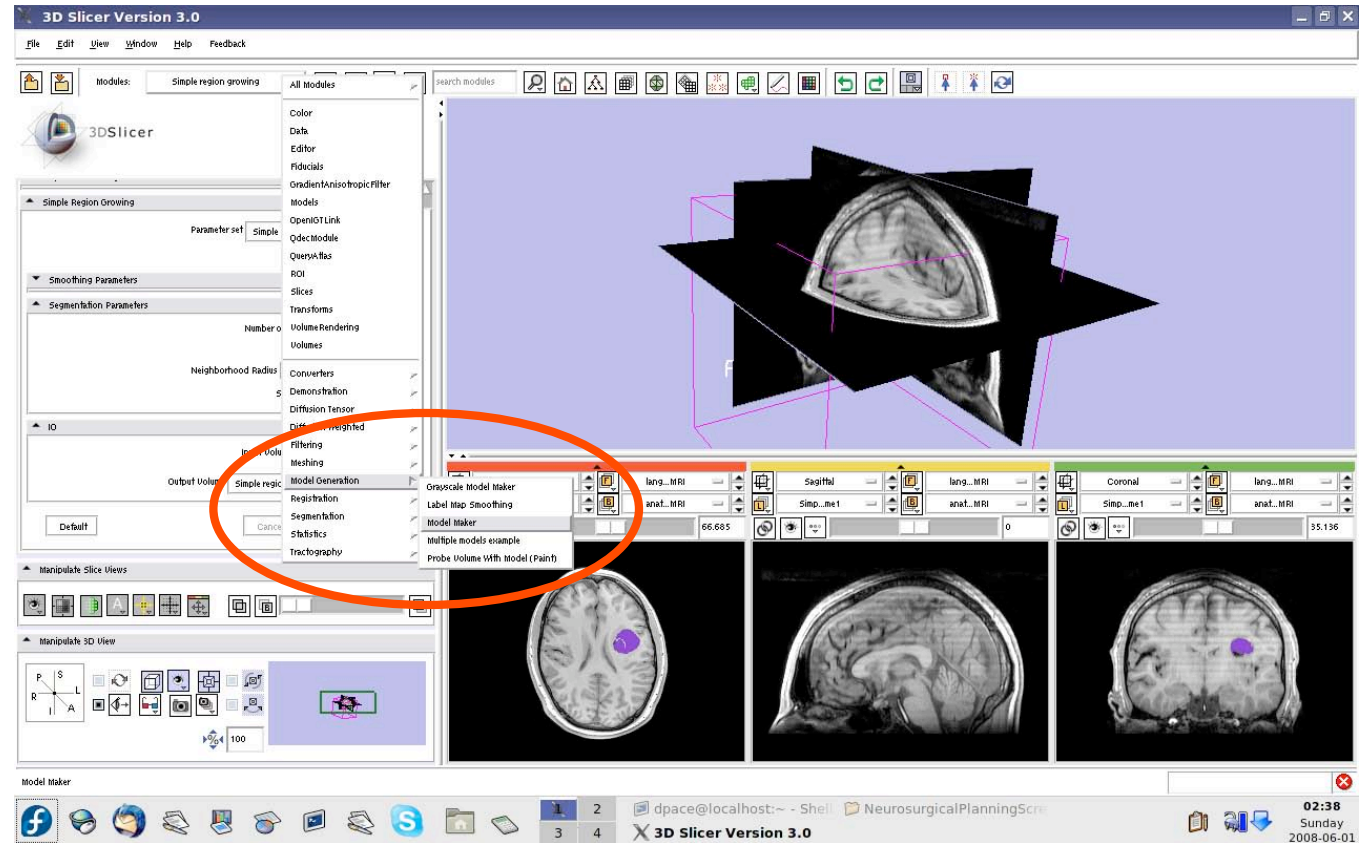
The tumour is segmented by the label layer called “Simple Region growing Volume1” (shown in purple)





Create the tumour model

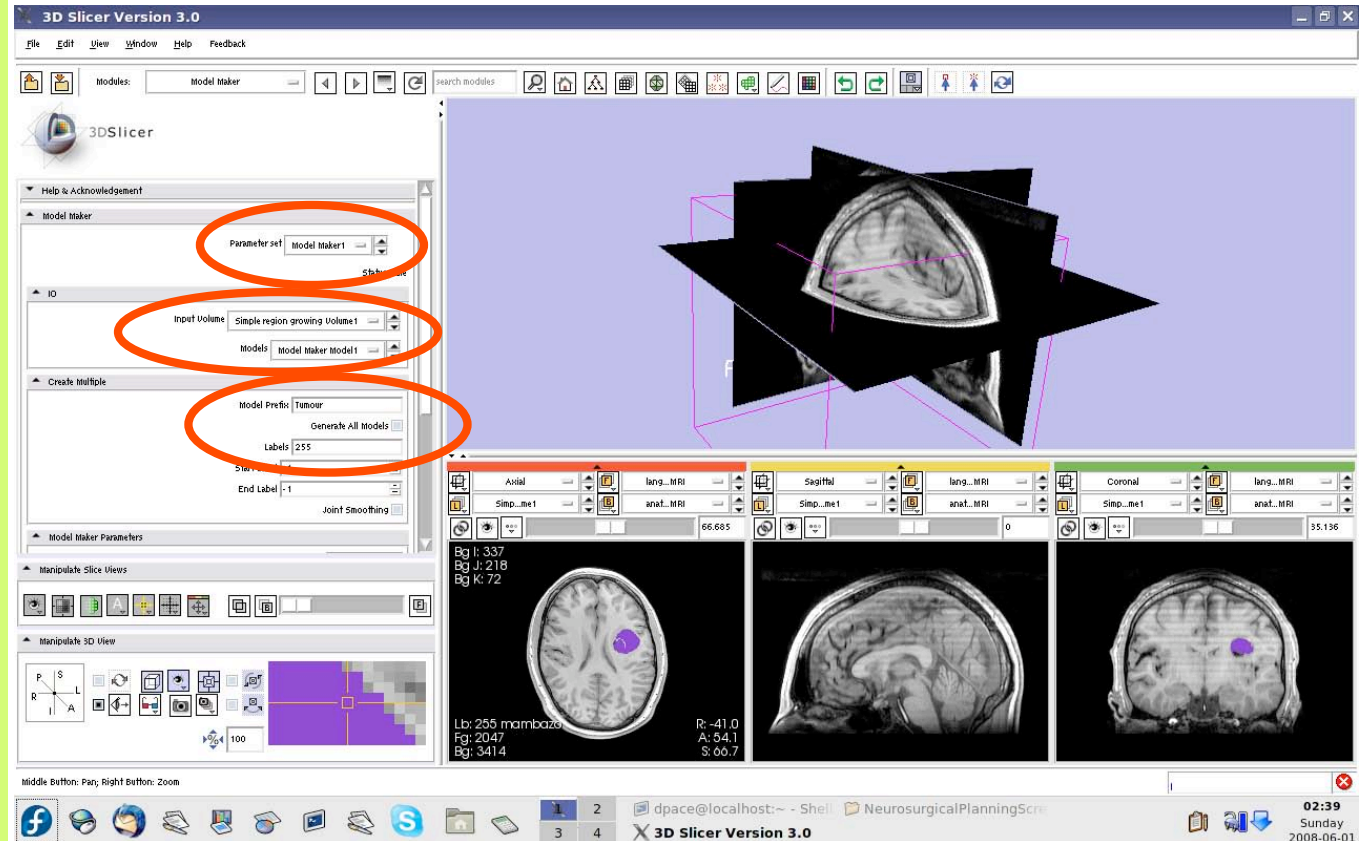
Open the Model Maker module





Create the tumour model

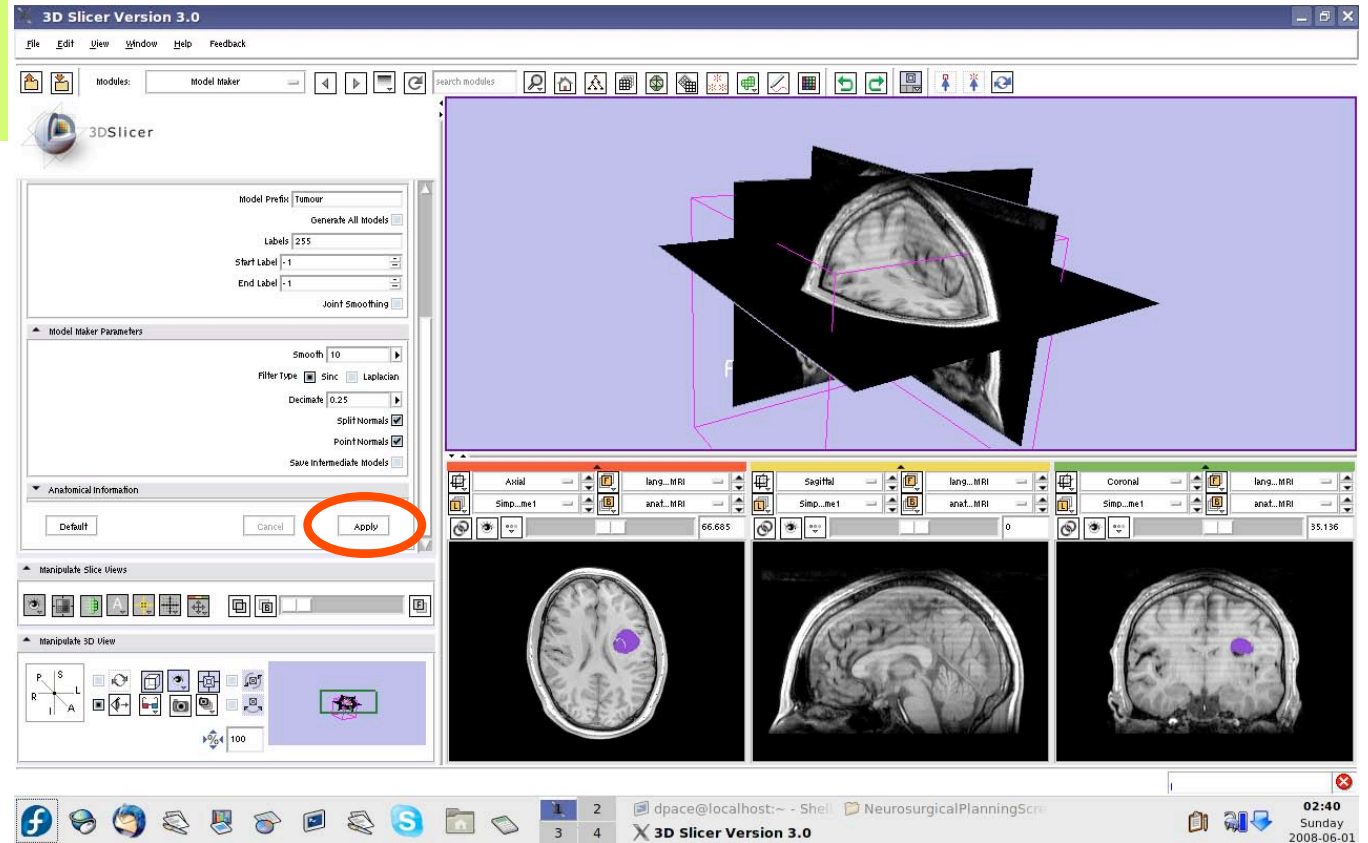
- Parameter set = Create new CommandLine Module
- Input Volume = Simple region growing Volume1
- Models = Create New ModelHierarchy
- Model Prefix = Tumour
- Labels = 255 (scroll over the purple tumour and note the “Lb” value)





Create the tumour model

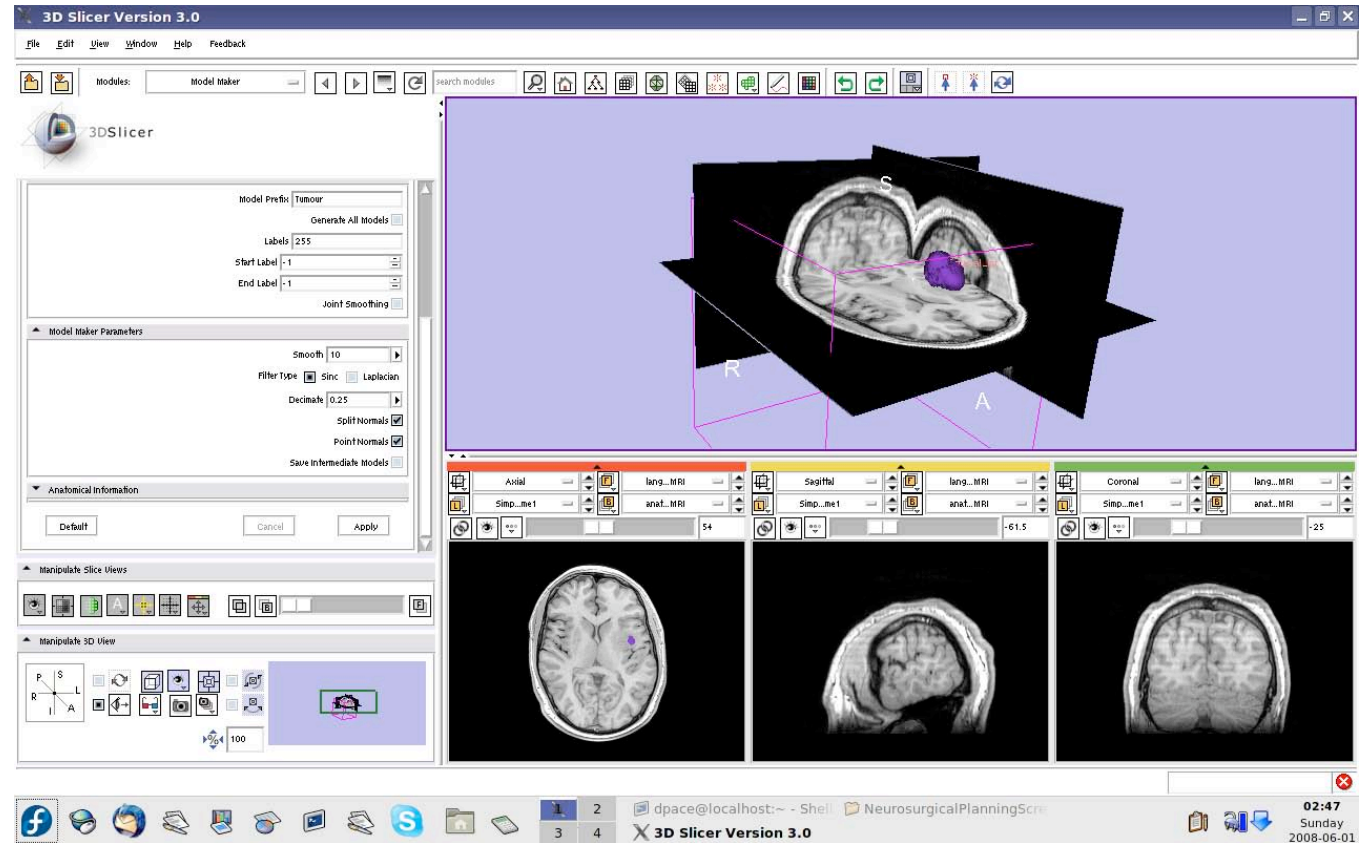
Click "Apply"





Create the tumour model

Slice through the image volume to expose the tumour model in the 3D Viewer

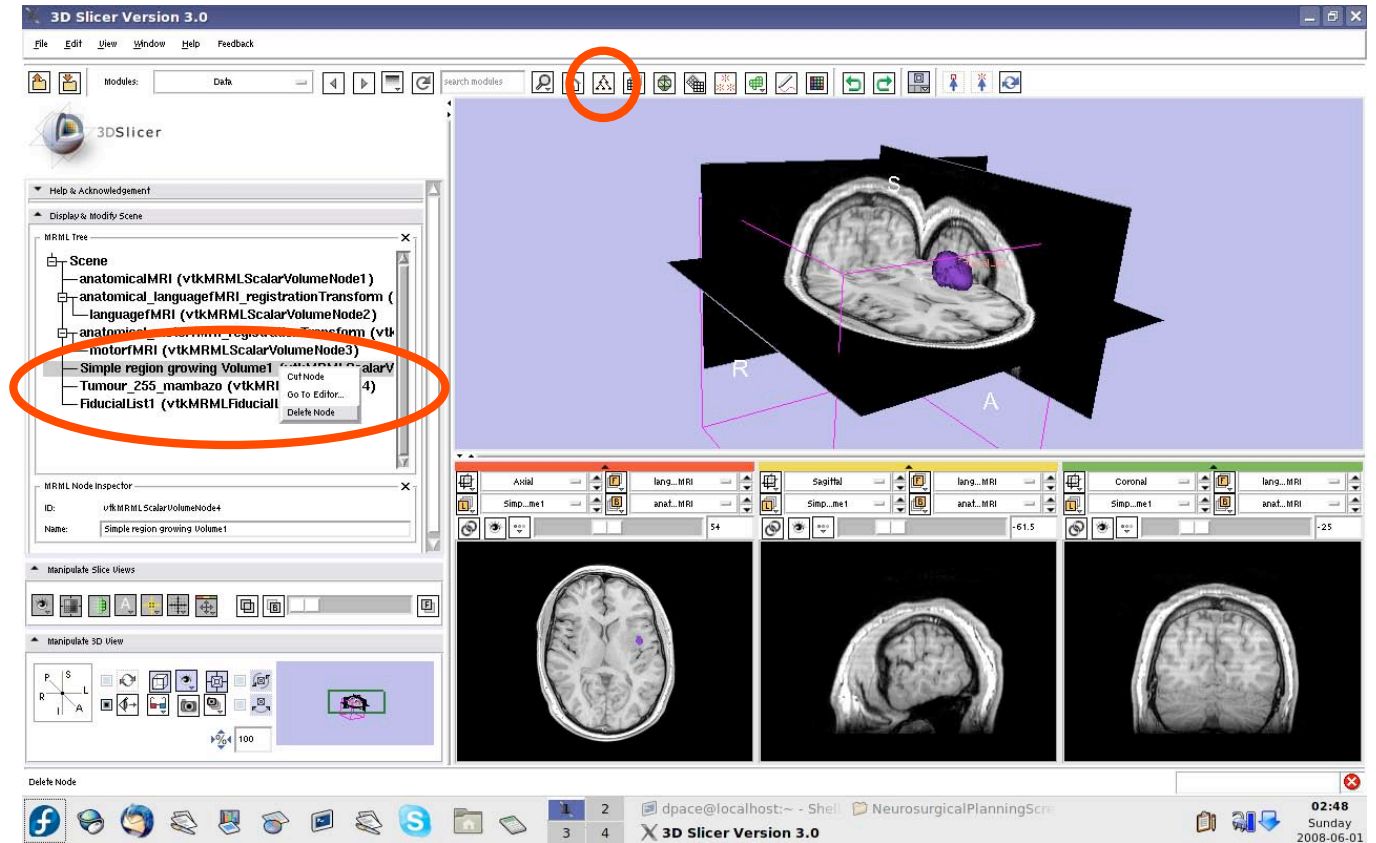




Create the tumour model

Open the Data module

Delete the FiducialList and Simple region growing Volume by right-clicking and selecting "Delete Node"

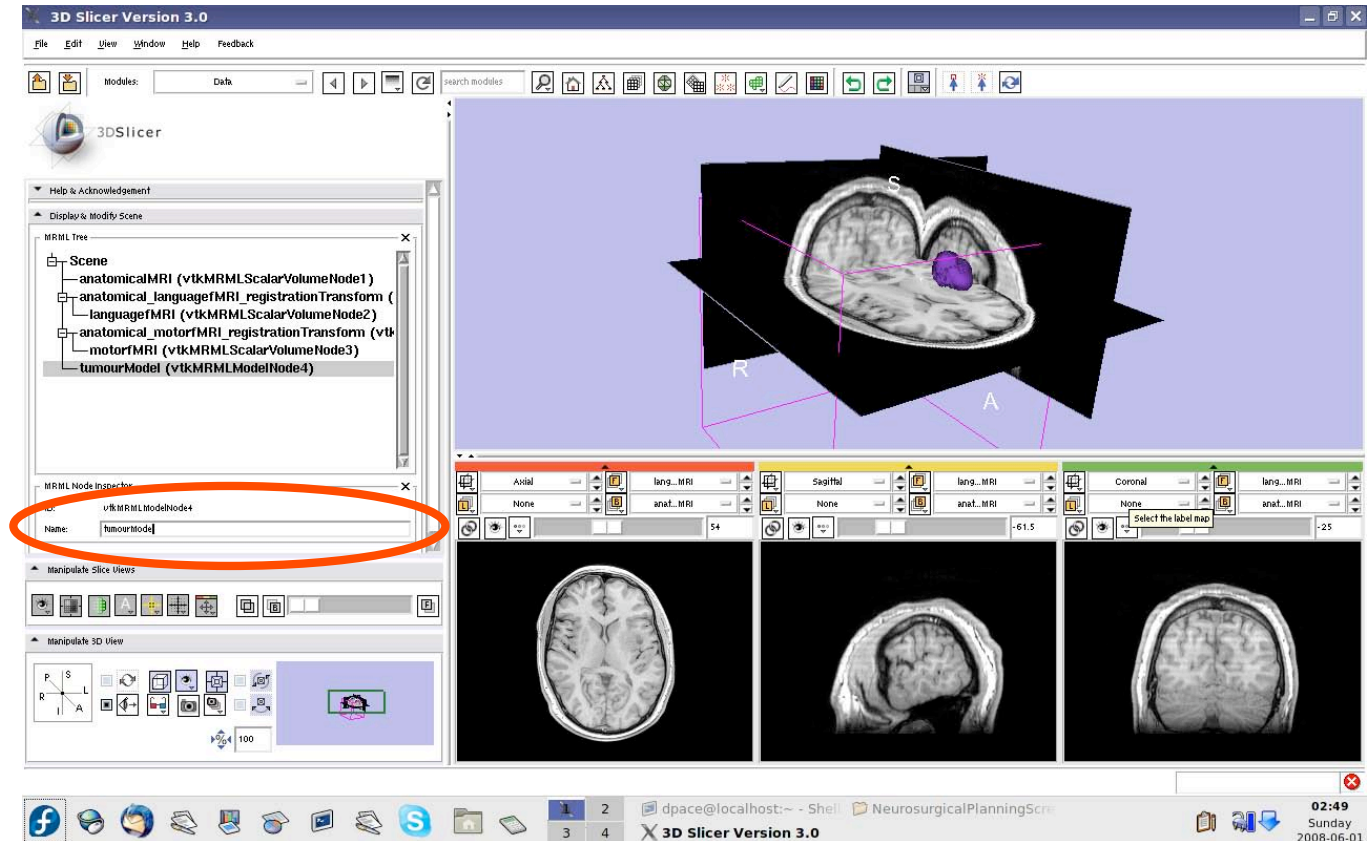




Create the tumour model

Note that the model now appears in the MRML tree

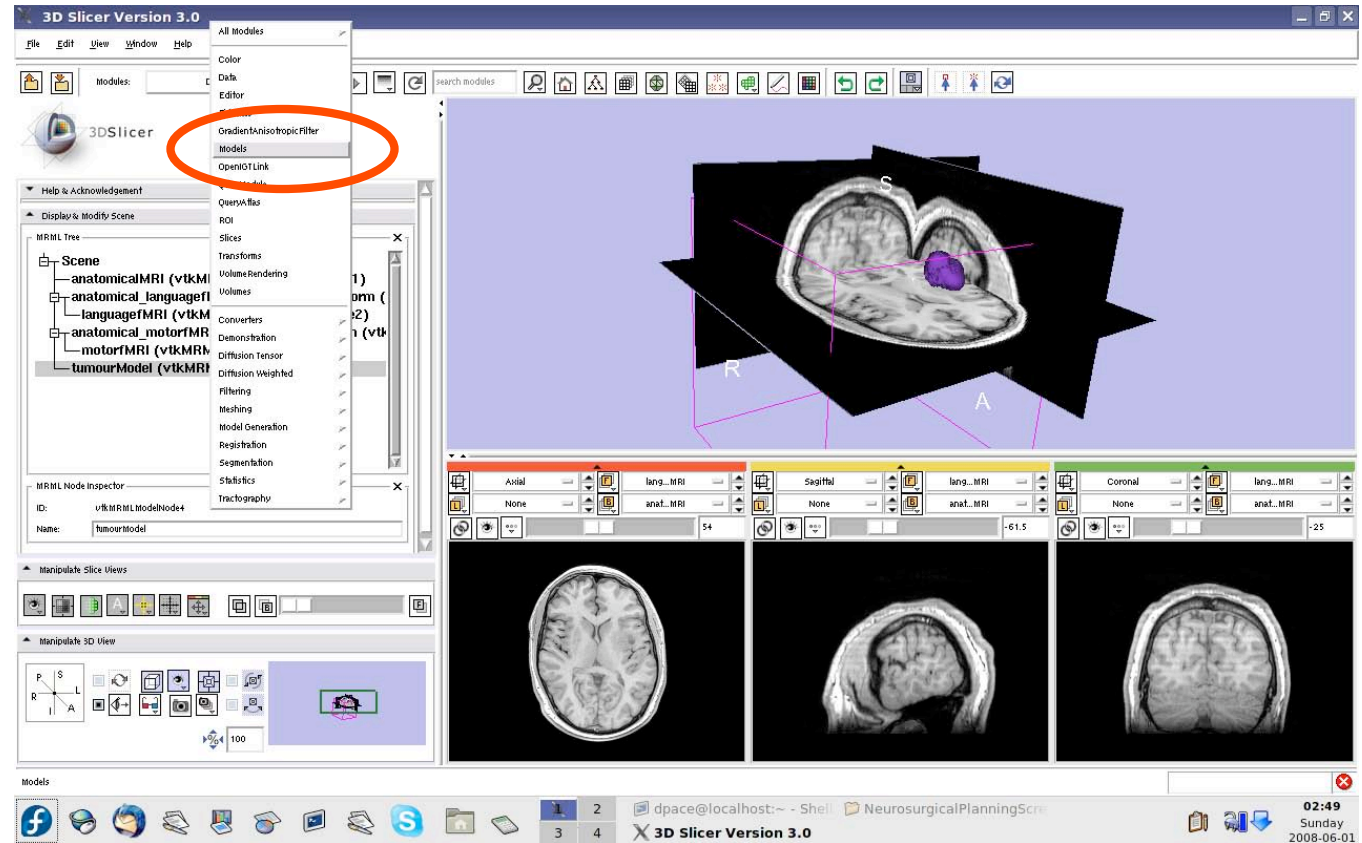
Change the name of the model to "tumourModel"





Change the model's appearance

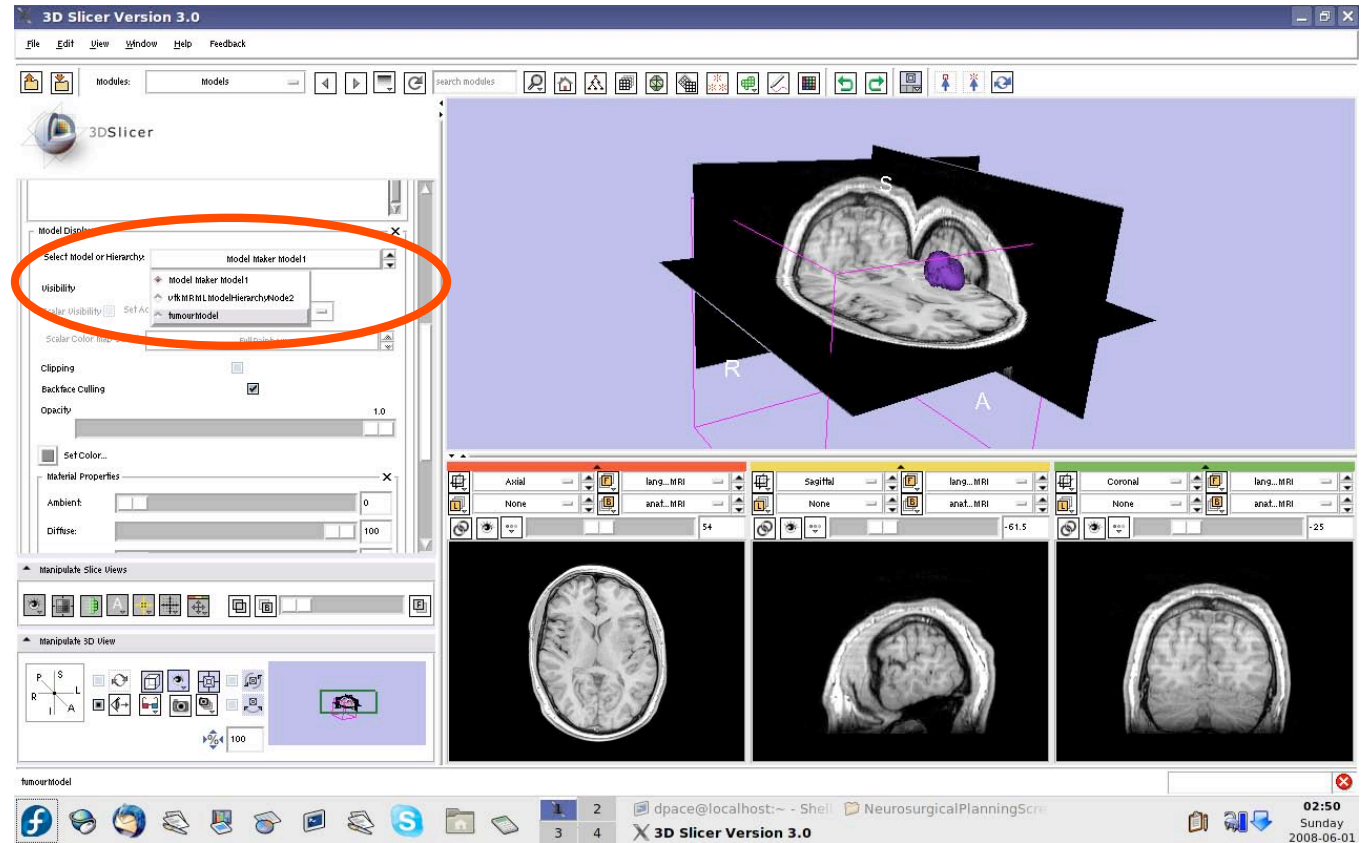
Open the Models module





Change the model's appearance

Select the
tumour
model

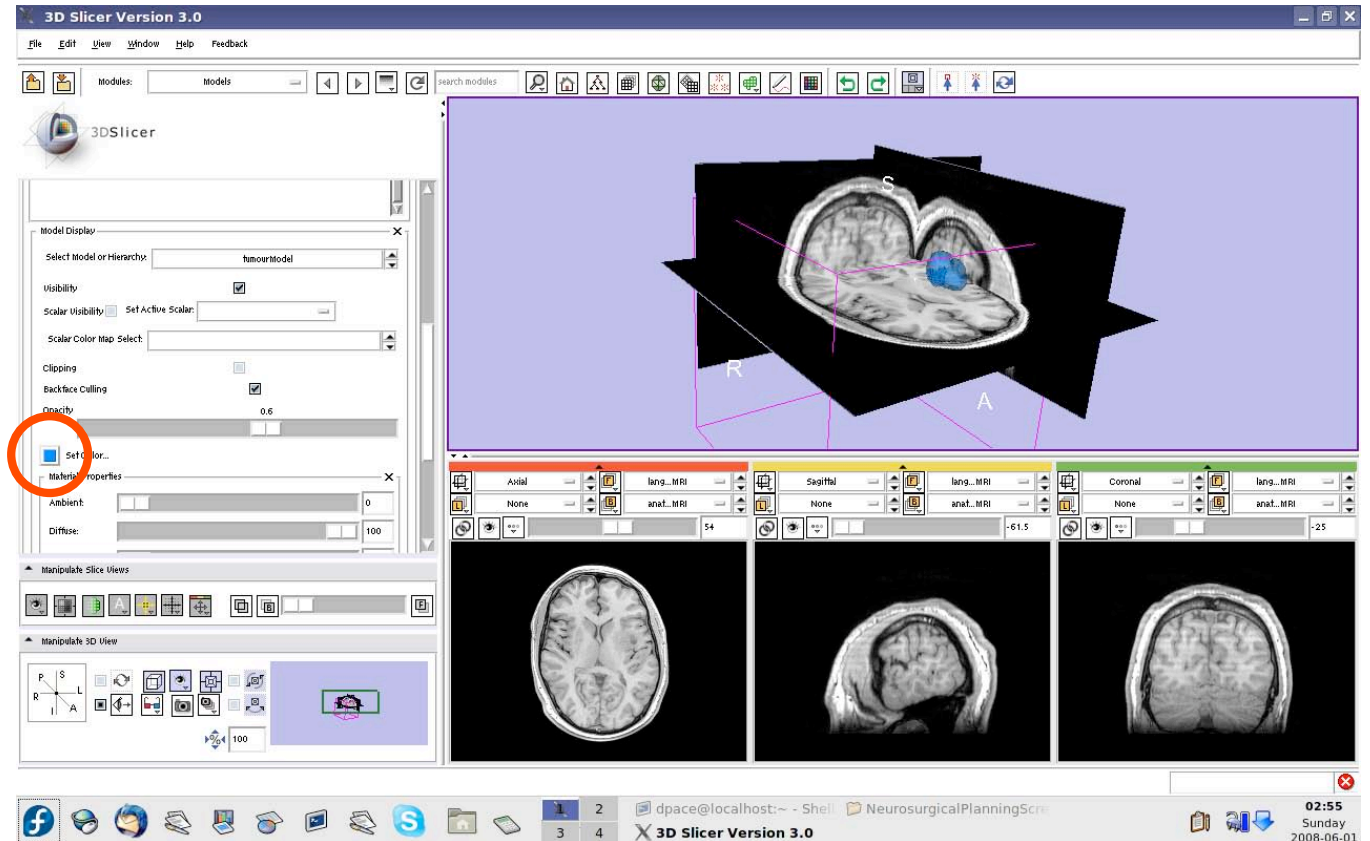




Change the model's appearance

Set the model's opacity to 0.6

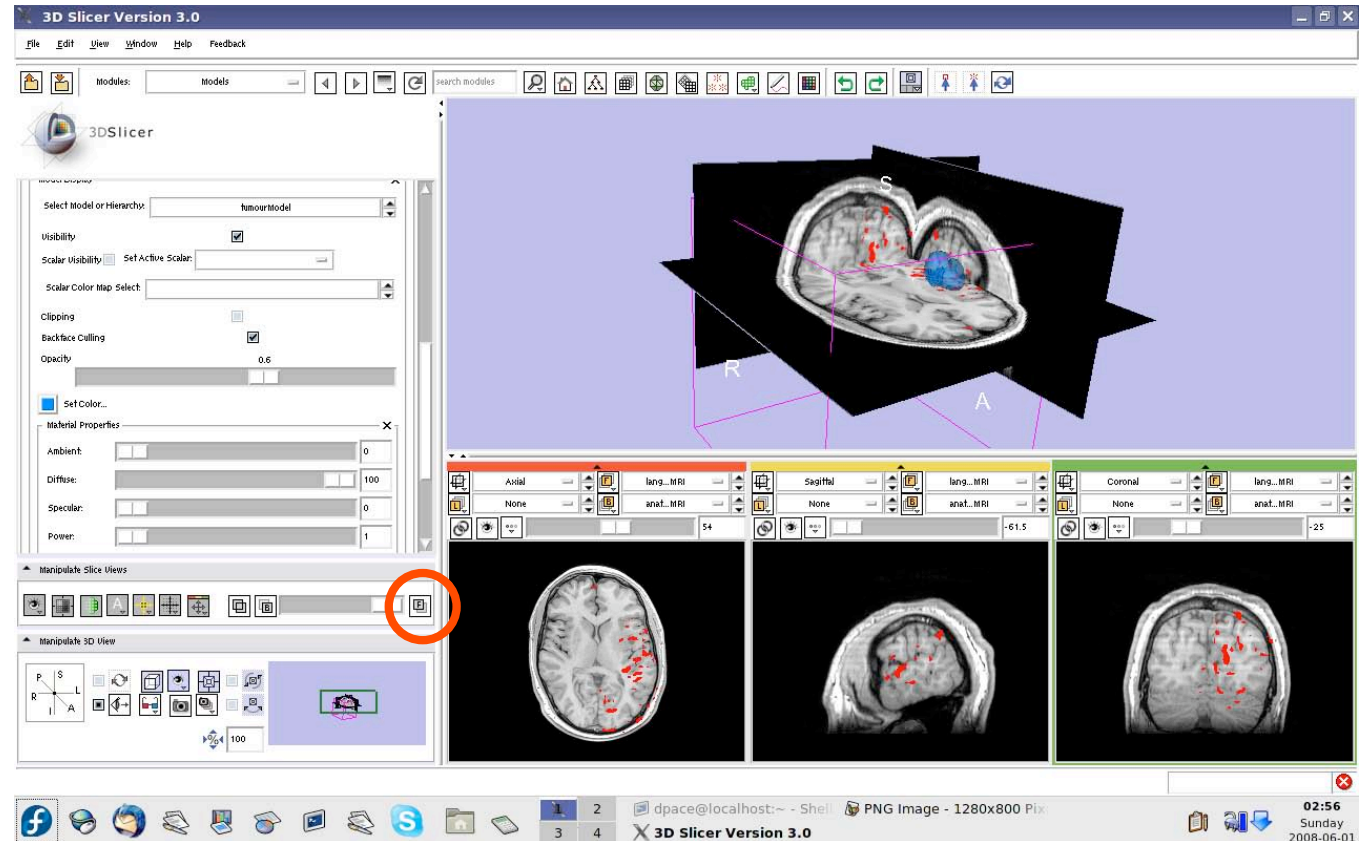
Click on the box next to "Set Color" to change the colour of the model to blue





View the anatomical MRI, fMRI and tumour model

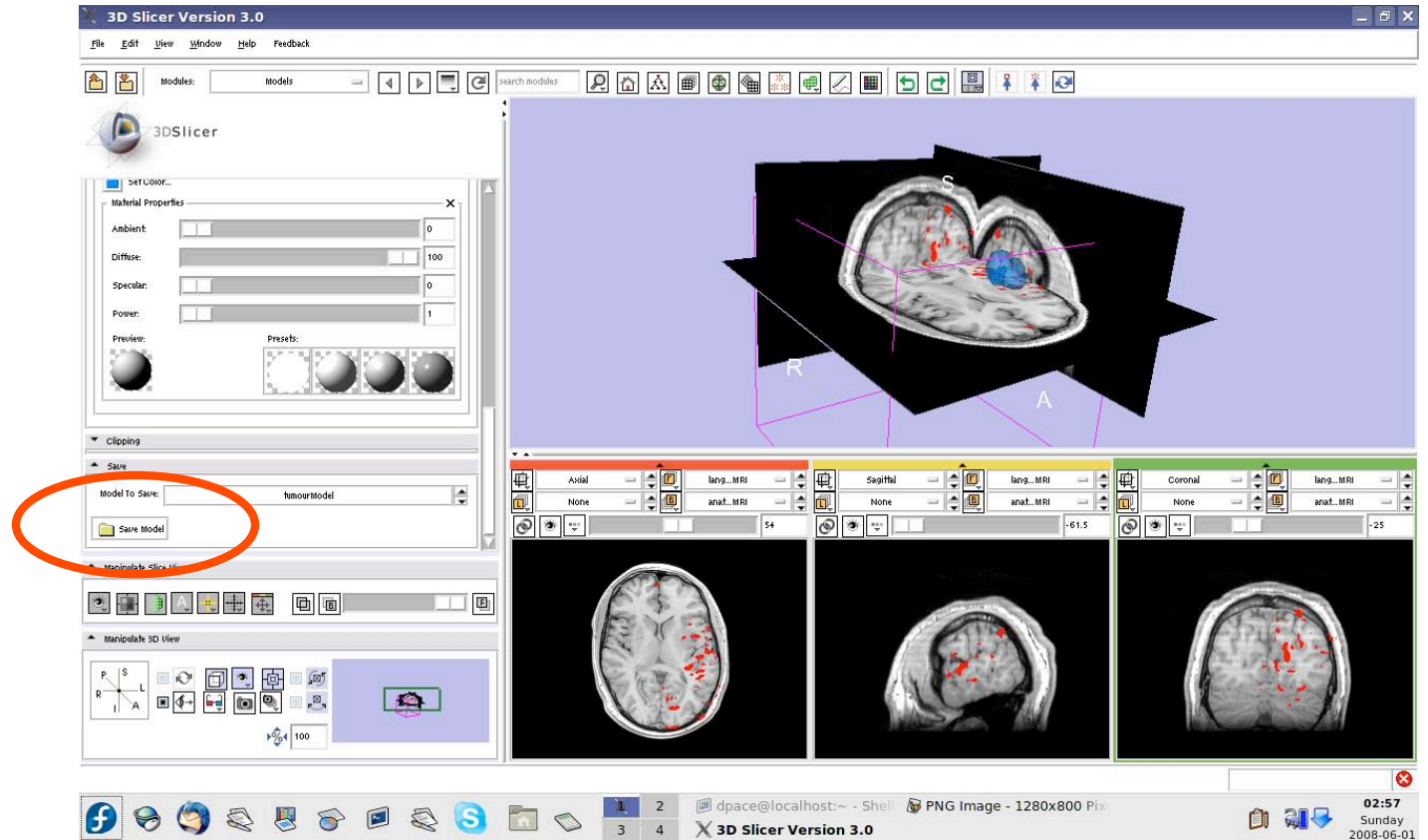
Click on the Foreground layer button to show the language fMRI data





Save the tumour model

In the
“Save”
pane, click
“Save
Model”

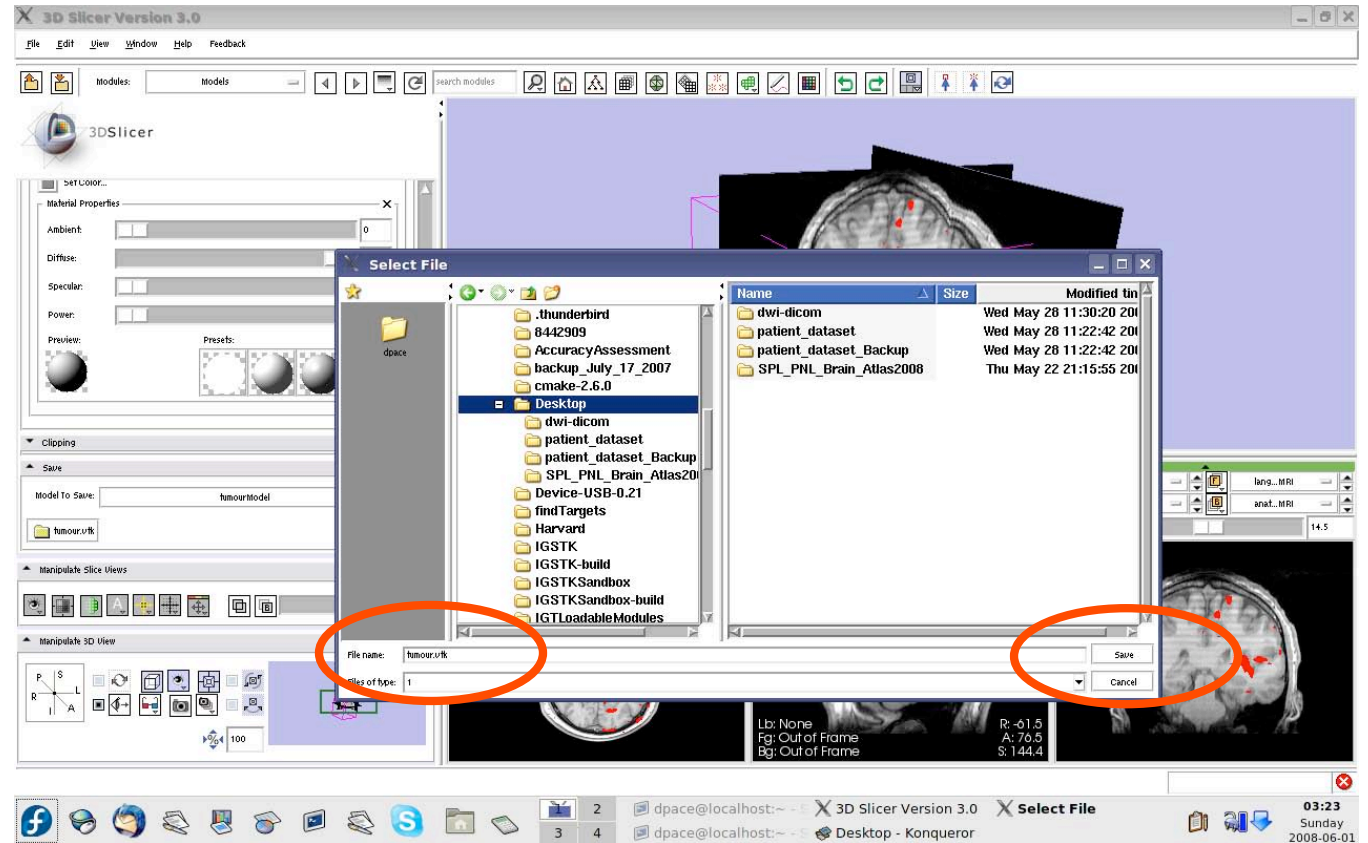




Save the tumour model

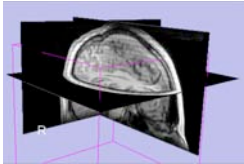
Name the tumour model
tumour.vtk

Click
“Save”

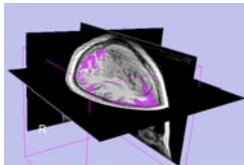




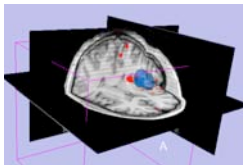
Overview



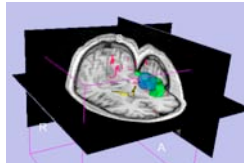
1. Loading and visualizing anatomical MRI data



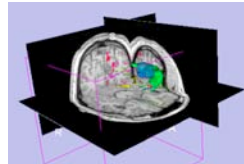
2. Incorporating fMRI data using image registration and thresholding



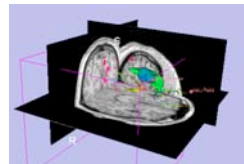
3. Creating a 3D model of the tumour volume



4. **Predicting the locations of brain structures using image registration and a brain atlas**



5. Incorporating brain fiber tractography from diffusion weighted images

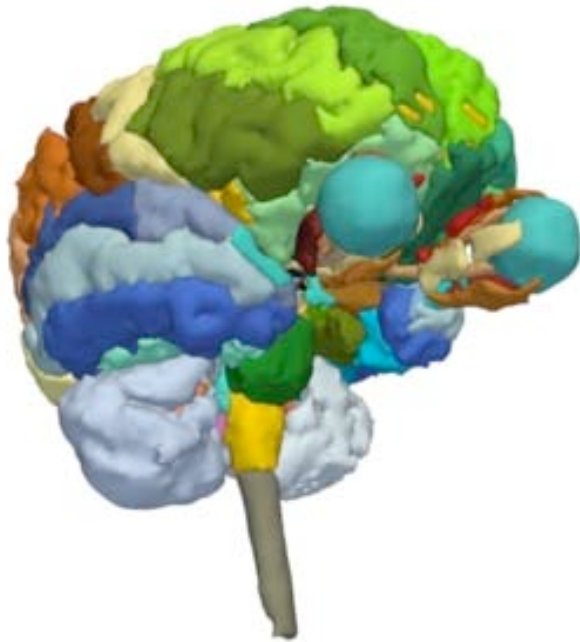

6. Annotating the preoperative plan and saving the scene



The SPL-PNL Brain Atlas

http://www.na-mic.org/pages/Special:PubDB_View?dSPACEID=1265



- Includes:
 - Anatomical MRI
 - Label maps
 - >160 models
- from a healthy volunteer



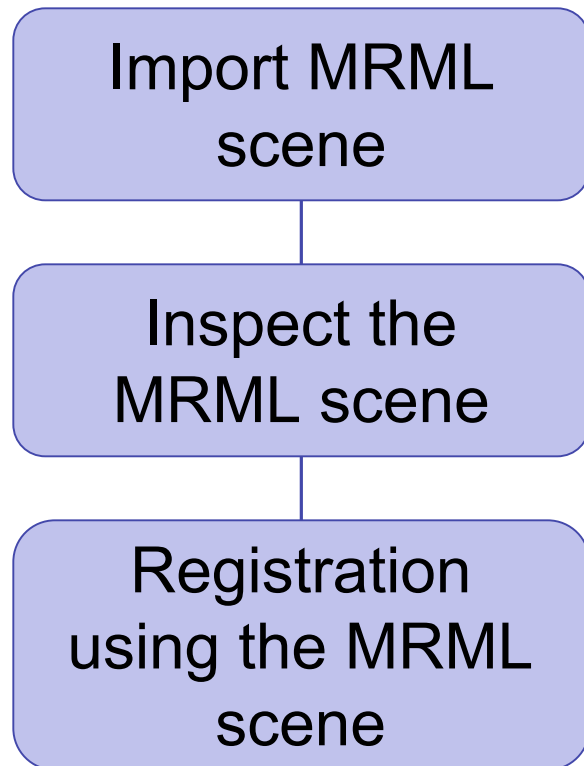
Incorporating a brain atlas

- **Utility of an atlas in IGT:**
 - Estimate the positions, orientations and shapes of important brain structures without having to segment each one in the patient dataset



Incorporating a brain atlas

- **Steps involved in this section:**



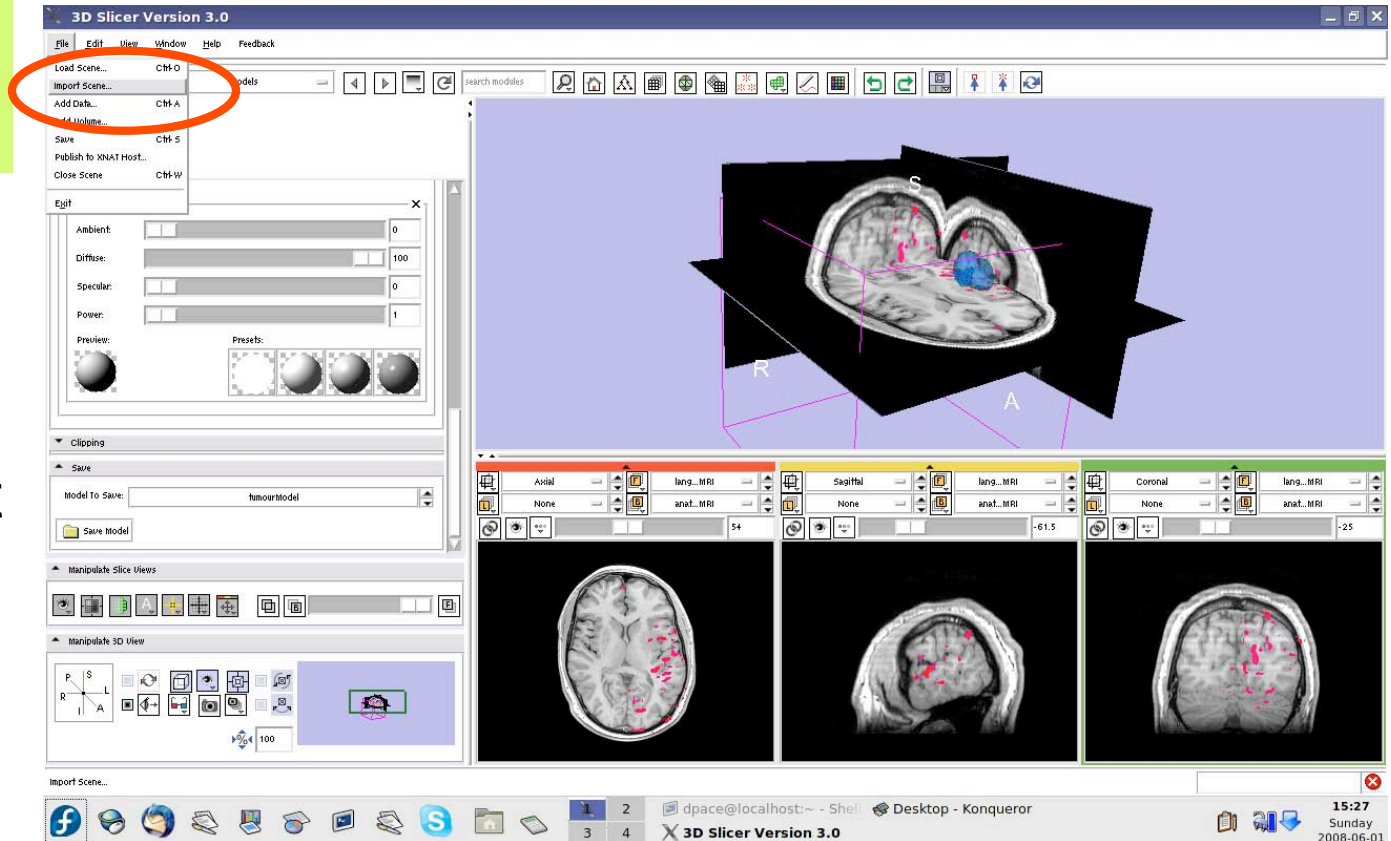
- The precomputed MRML scene contains a copy of the patient's anatomical MRI, the atlas's anatomical MRI, and three models:
 - Left and right optic tracts
 - Left anterior superior temporal gyrus
- The anatomical MRIs of the patient and the atlas were registered with an initial manual transform followed by an automatic affine registration



Import the patient-atlas registration transform scene

Select File -> Import Scene

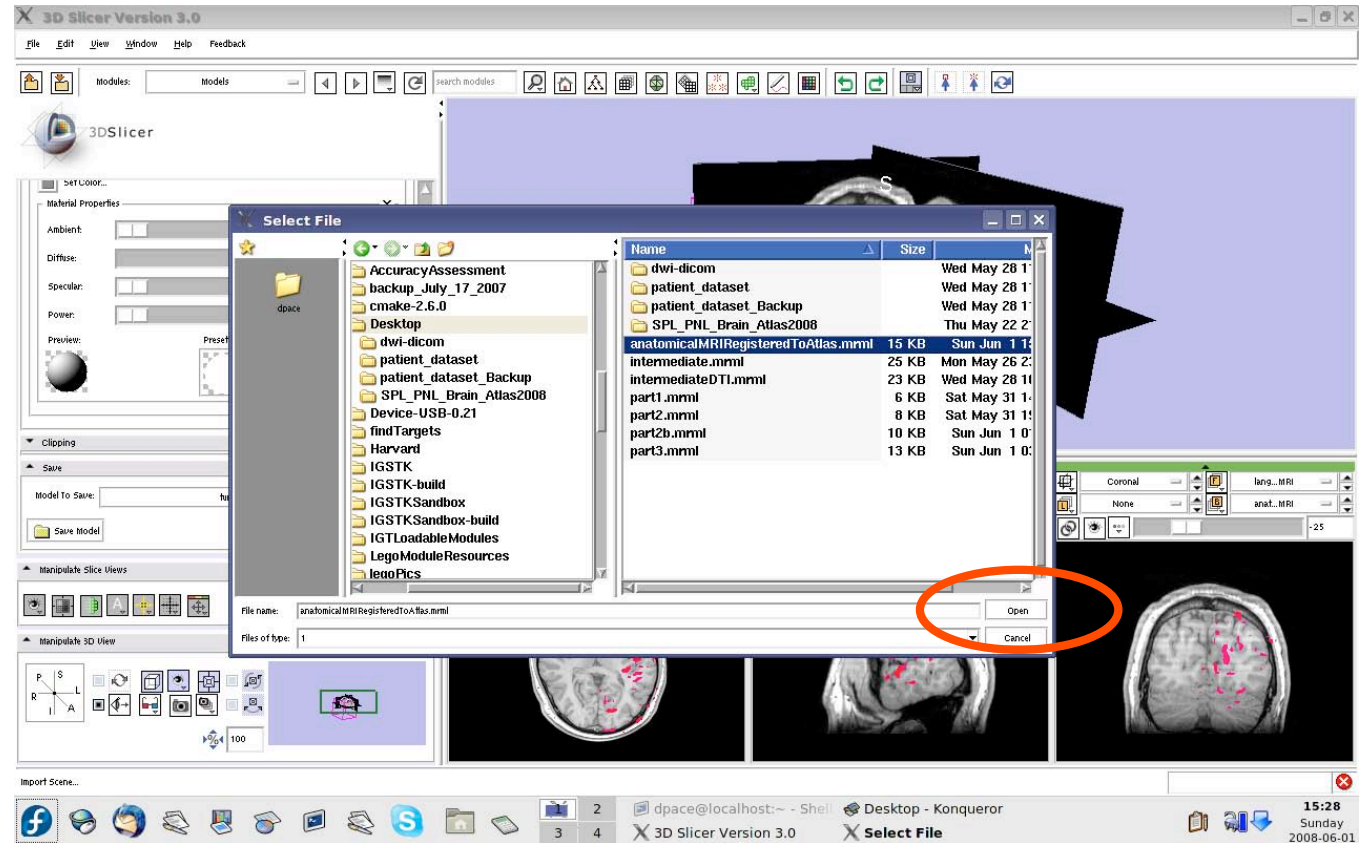
Note: Make sure that you select “Import Scene” and not “Load Scene”, as “Load Scene” will delete your work so far





Import the patient-atlas registration transform scene

Select
“anatomical
MRI
Registered
ToAtlas.mrml”,
then click
“Open”



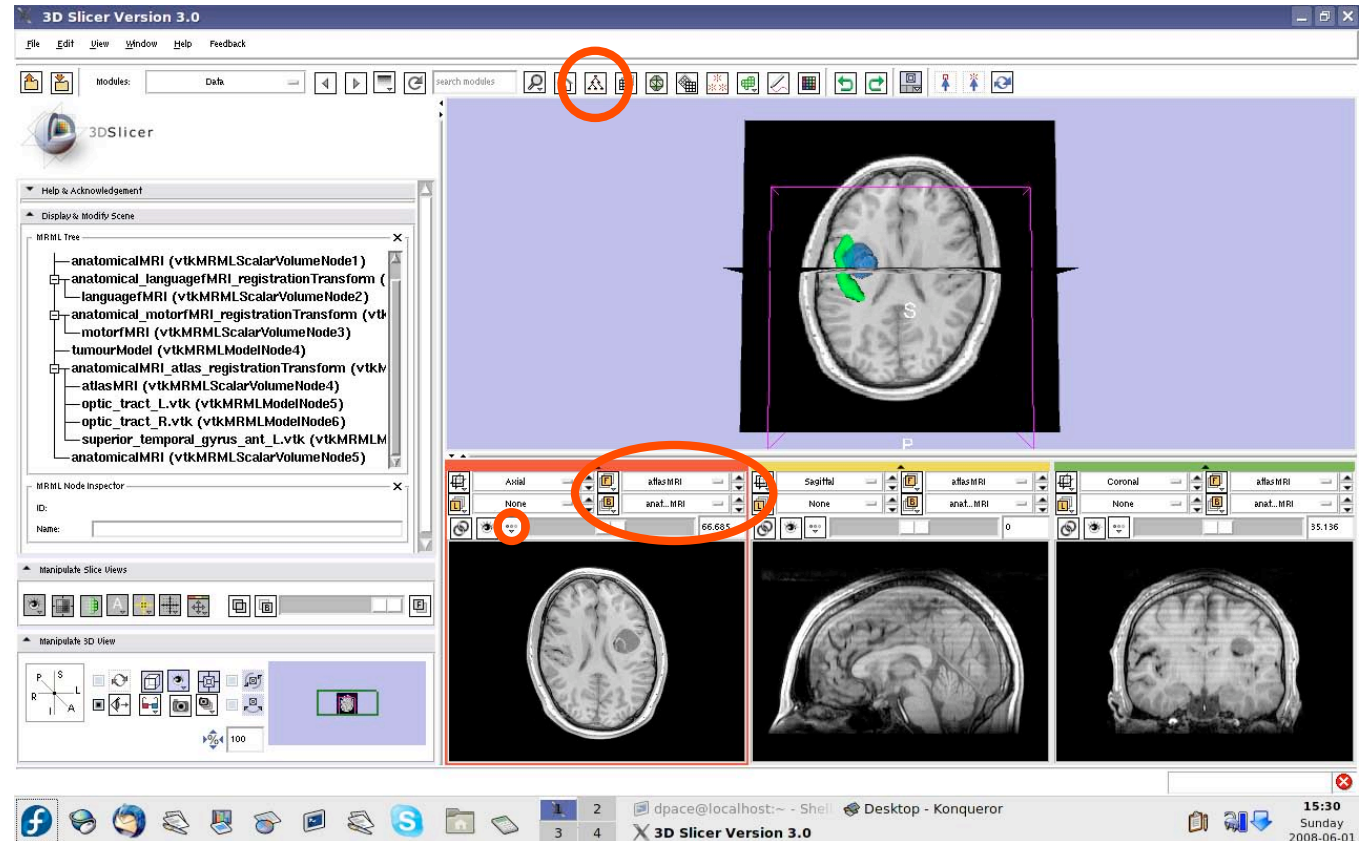


Inspect the MRML scene

Open the Data module

Set the foreground to atlasMRI and the background to anatomicalMRI

Click on the “fit to window” button

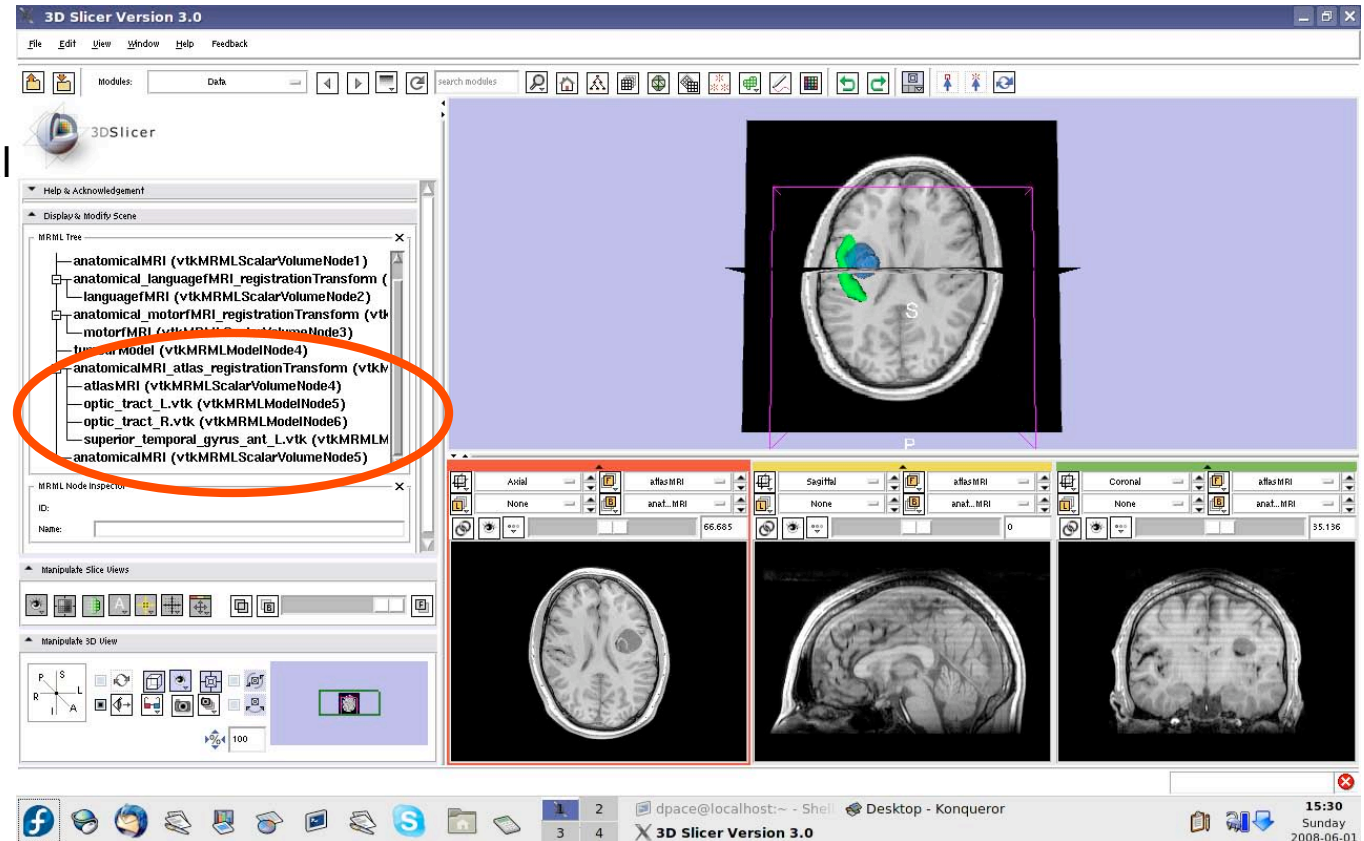




Inspect the MRML scene

Inspect the atlas MRML scene

- atlasMRI = anatomical MRI from the atlas
- optic_tract_L.vtk = model of the left optic tract
- optic_tract_R.vtk = model of the right optic tract
- Superior_temporal_gyrus_ant_L.vtk = model of the left anterior superior temporal gyrus

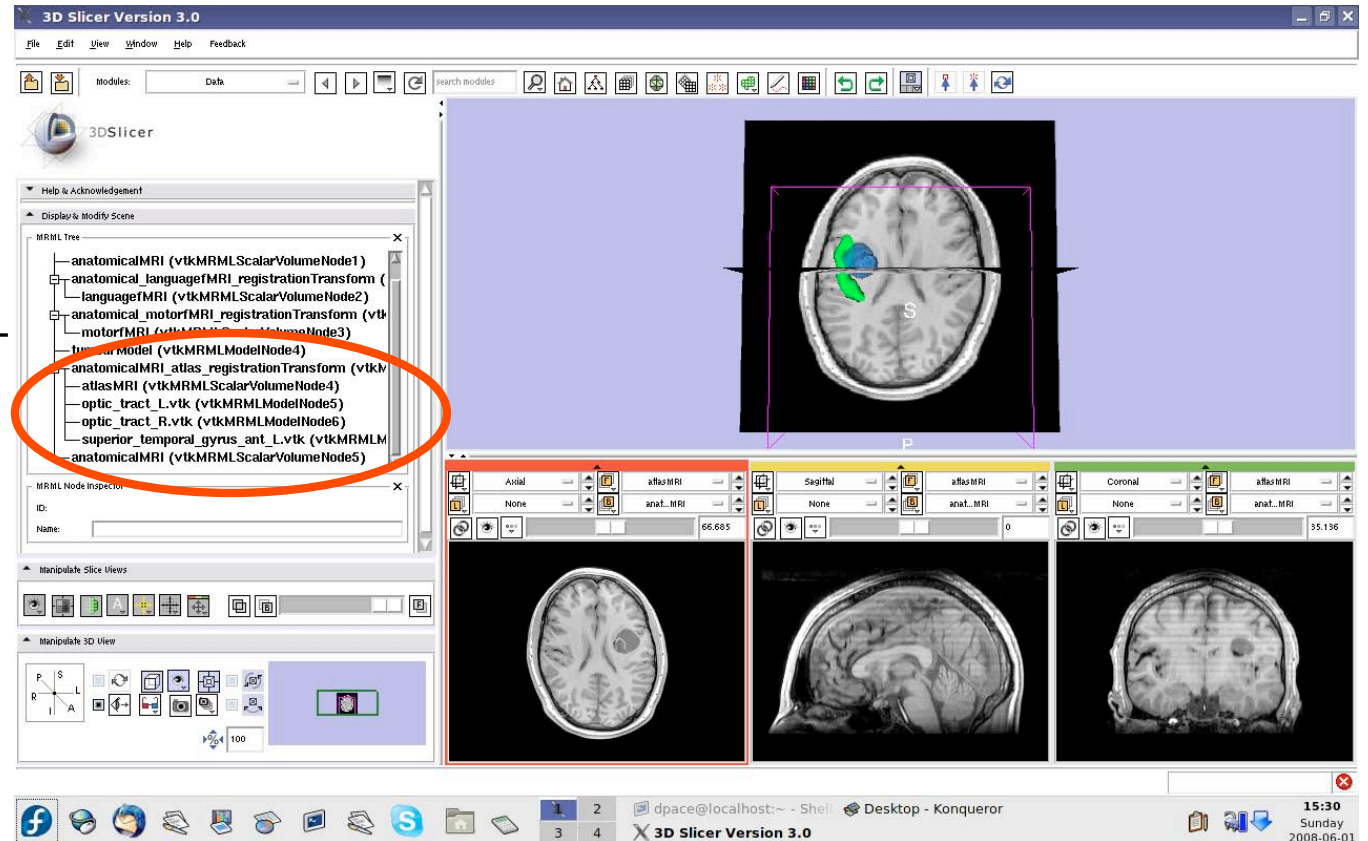




Inspect the MRML scene

Inspect the atlas MRML scene

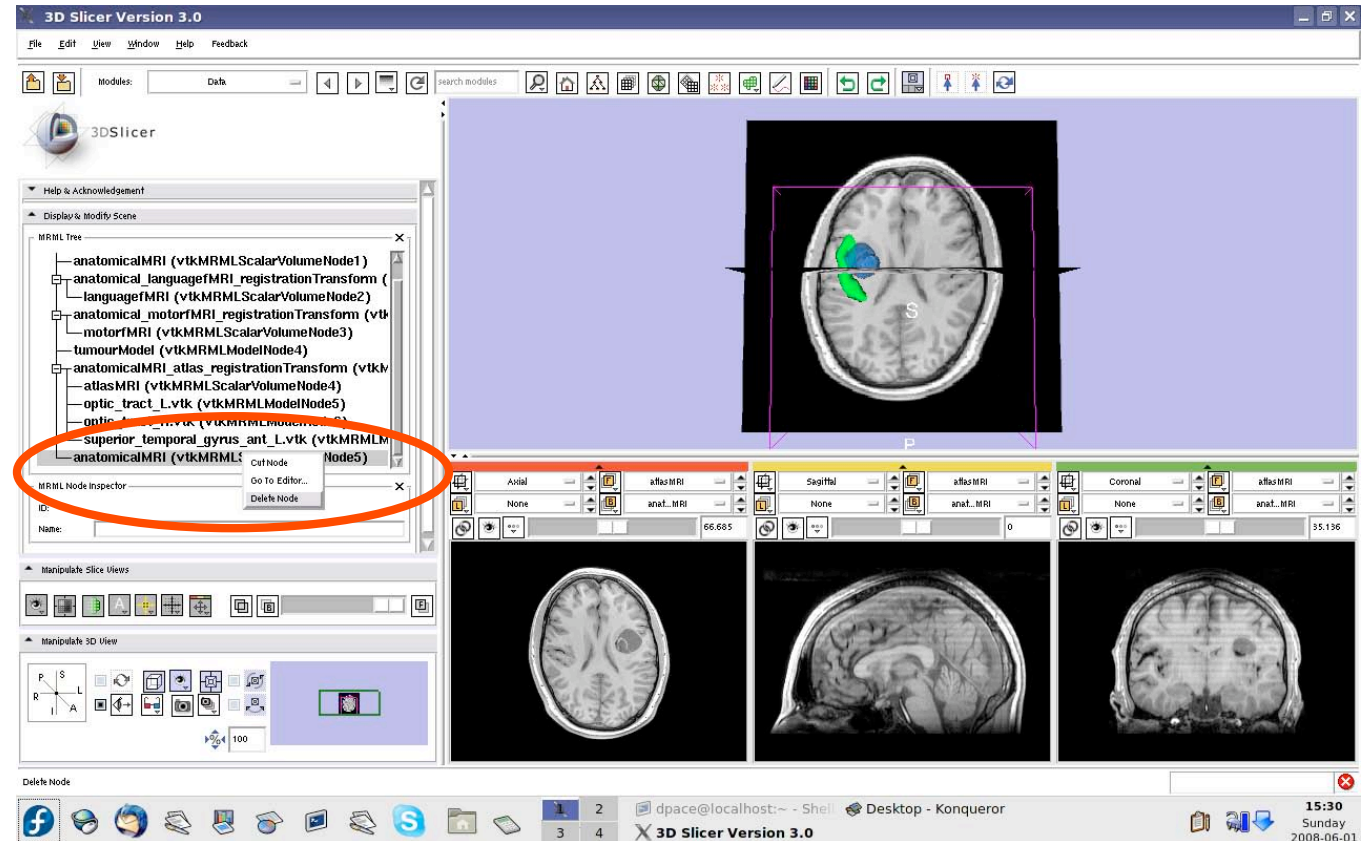
- anatomical MRI = copy of the patient's anatomical MRI
- anatomicalMRI_atlas_registration Transformation = the transformation between the patient's anatomical MRI and the atlas's MRI





Inspect the MRML scene

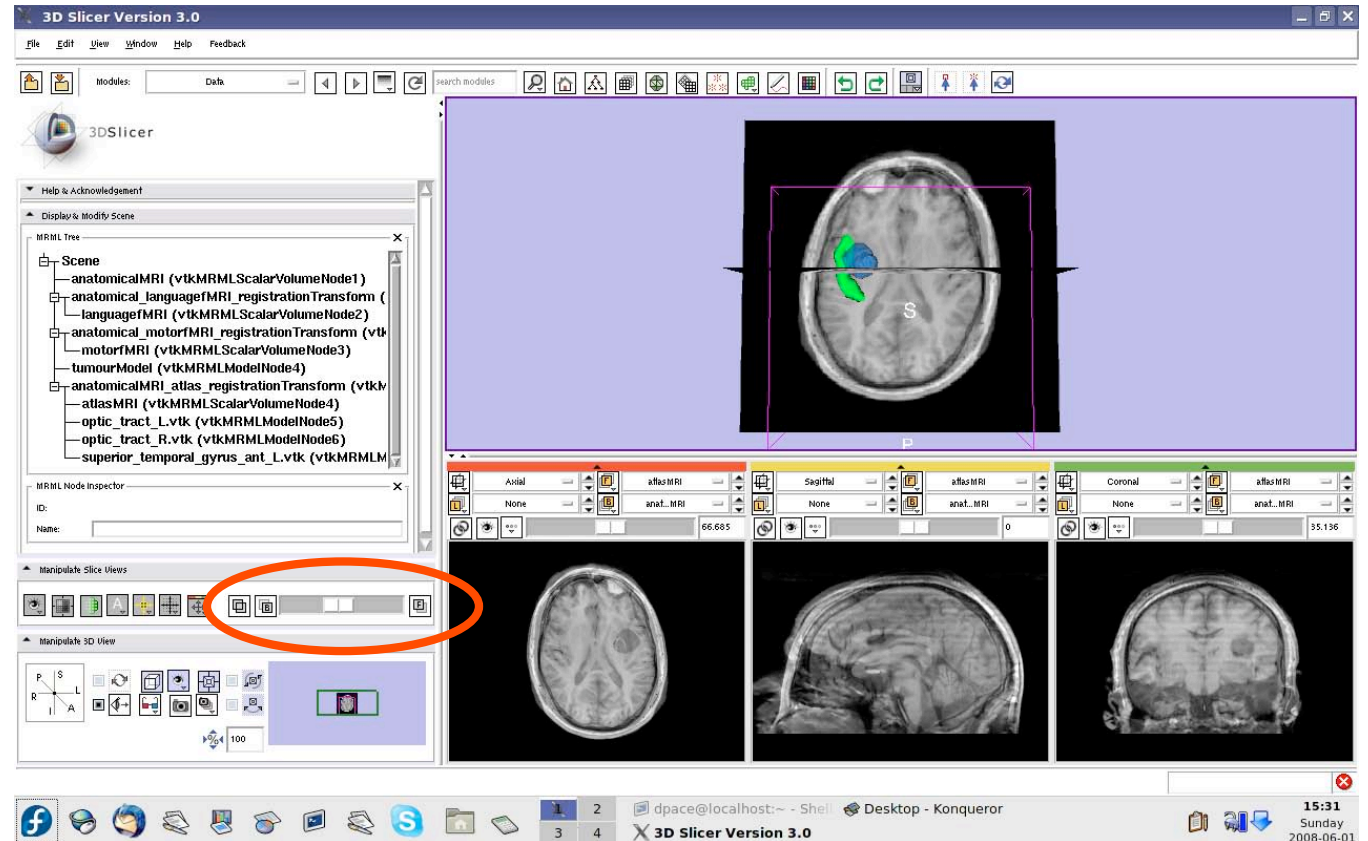
Delete the duplicate anatomicalMRI node by right-clicking and selecting “Delete Node”





Inspect the patient-atlas registration

Scale the opacities to see how well the atlas MRI and patient anatomical MRI image volumes are aligned



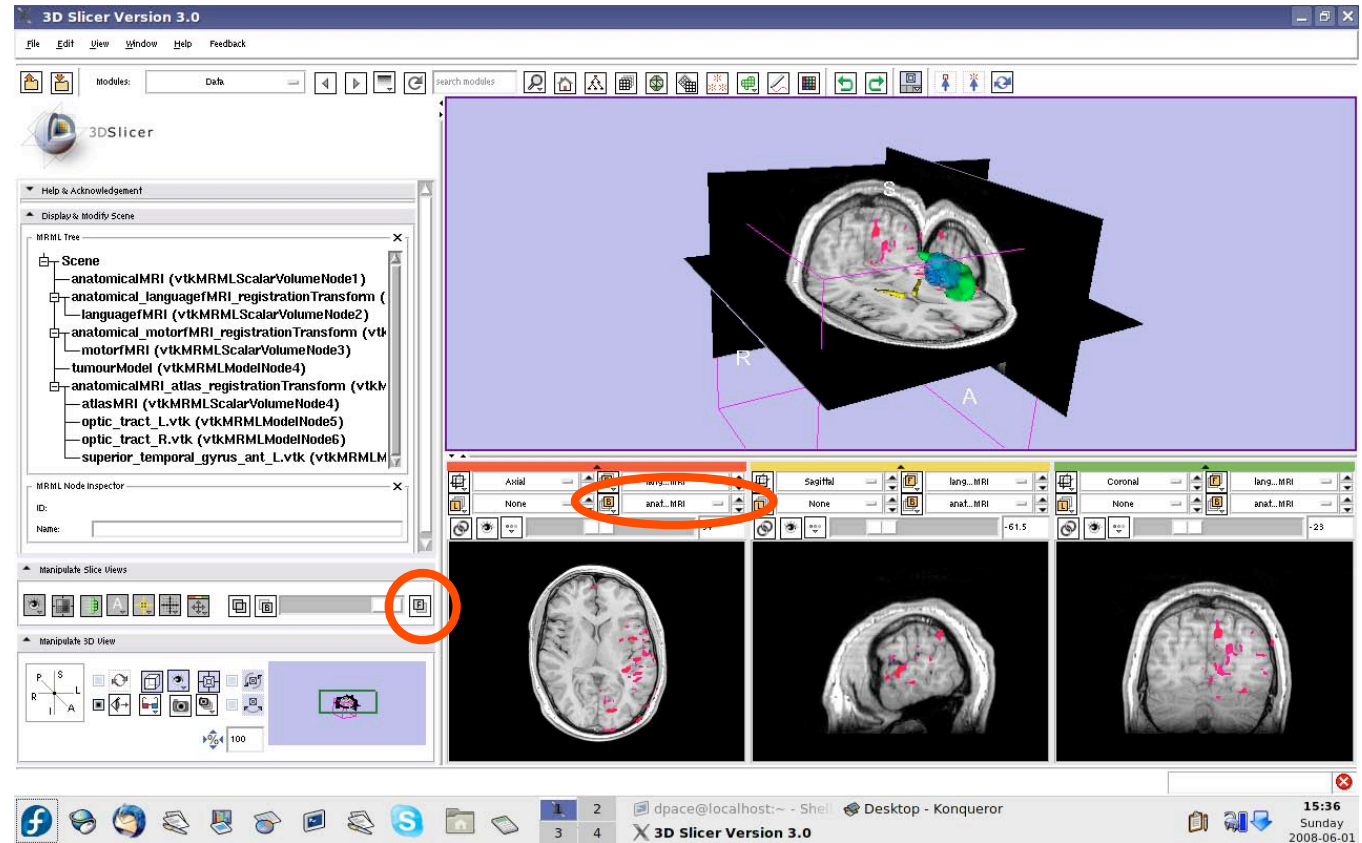


Inspect the entire scene so far

Set the foreground to languagefMRI

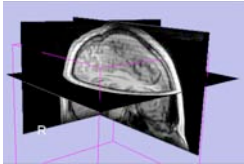
Click on the Foreground layer button to show the language fMRI data

Slice through the image volume to get a good view

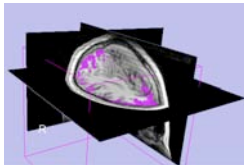




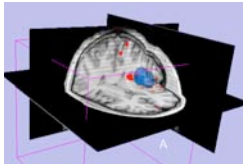
Overview



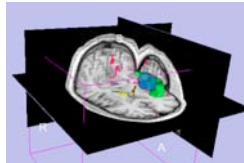
1. Loading and visualizing anatomical MRI data



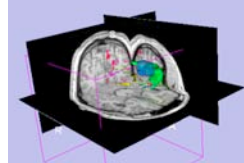
2. Incorporating fMRI data using image registration and thresholding



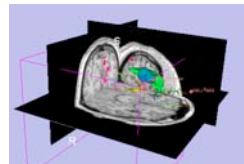
3. Creating a 3D model of the tumour volume



4. Predicting the locations of brain structures using image registration and a brain atlas



- 5. Incorporating brain fiber tractography from diffusion weighted images**




6. Annotating the preoperative plan and saving the scene

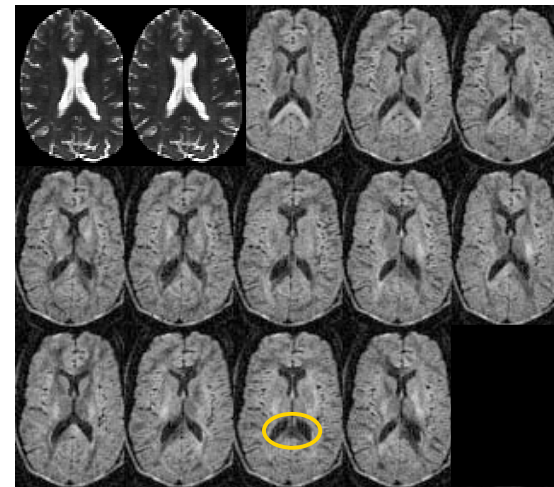


Diffusion Tensor Imaging (DTI)

Diffusion Sensitizing Gradients



Diffusion Weighted Images



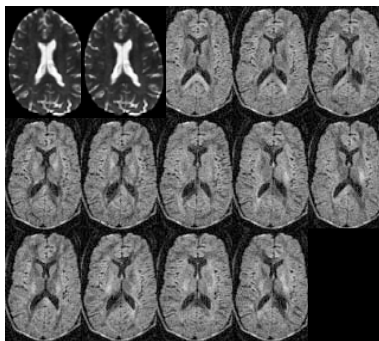


- Each diffusion weighted image shows the diffusion of water in the direction of the diffusion sensitizing gradient



Diffusion Tensor Imaging (DTI)

- Acquire diffusion weighted images (DWI) and baseline images
 - Estimate a tensor at each voxel
 - Calculate a scalar “diffusion anisotropy index”, such as fractional anisotropy, to quantify the diffusion’s anisotropy
 - Perform tractography (fiber tracking)





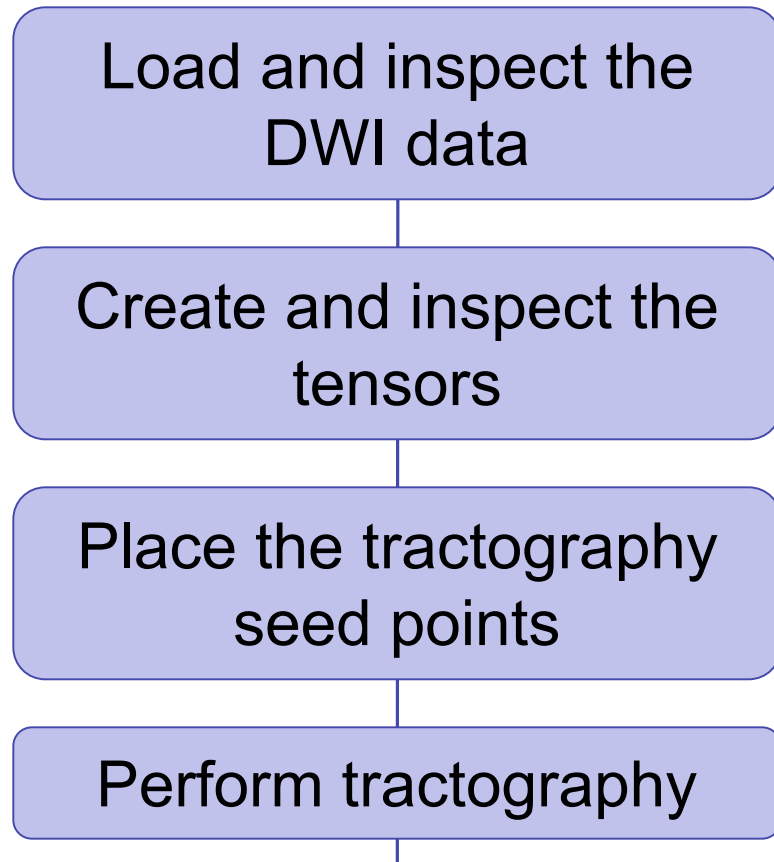
Diffusion Tensor Imaging (DTI)

- **Utility of Diffusion Tensor Imaging in IGT:**
 - Major tracts that run between functionally important regions of the brain must remain intact to prevent side effects for the patient
 - Knowing where these tracts are allows us to modify our surgical plan so that we avoid them (as much as possible)



Diffusion Tensor Imaging (DTI)

- **Steps involved in this section:**



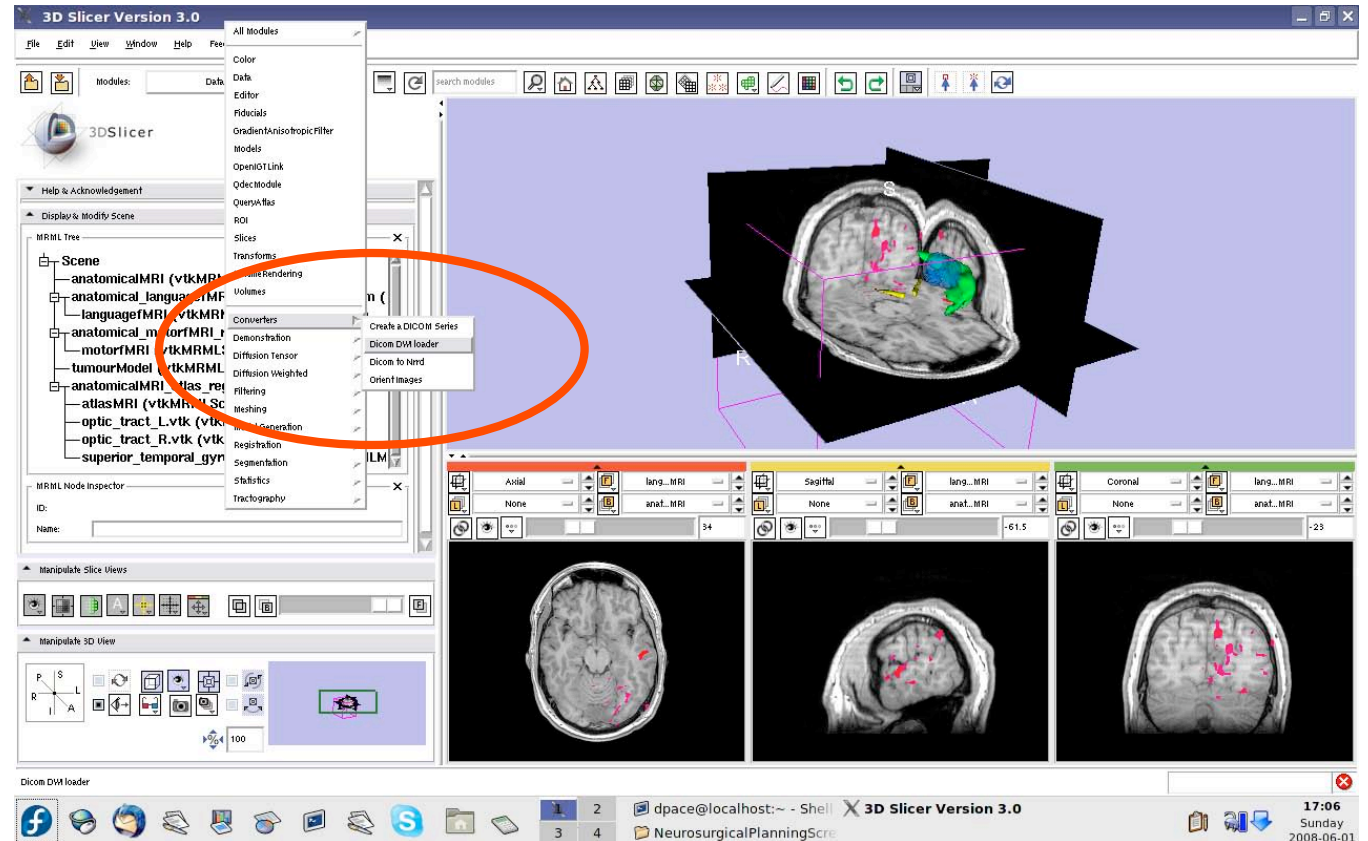
Registration using a precomputed MRML scene

- The precomputed MRML scene contains a copy of the patient's anatomical MRI, a copy of the baseline image of the patient's DTI, and the transformation that registers them together



Load the DWI data

Open the
DICOM DWI
Loader module

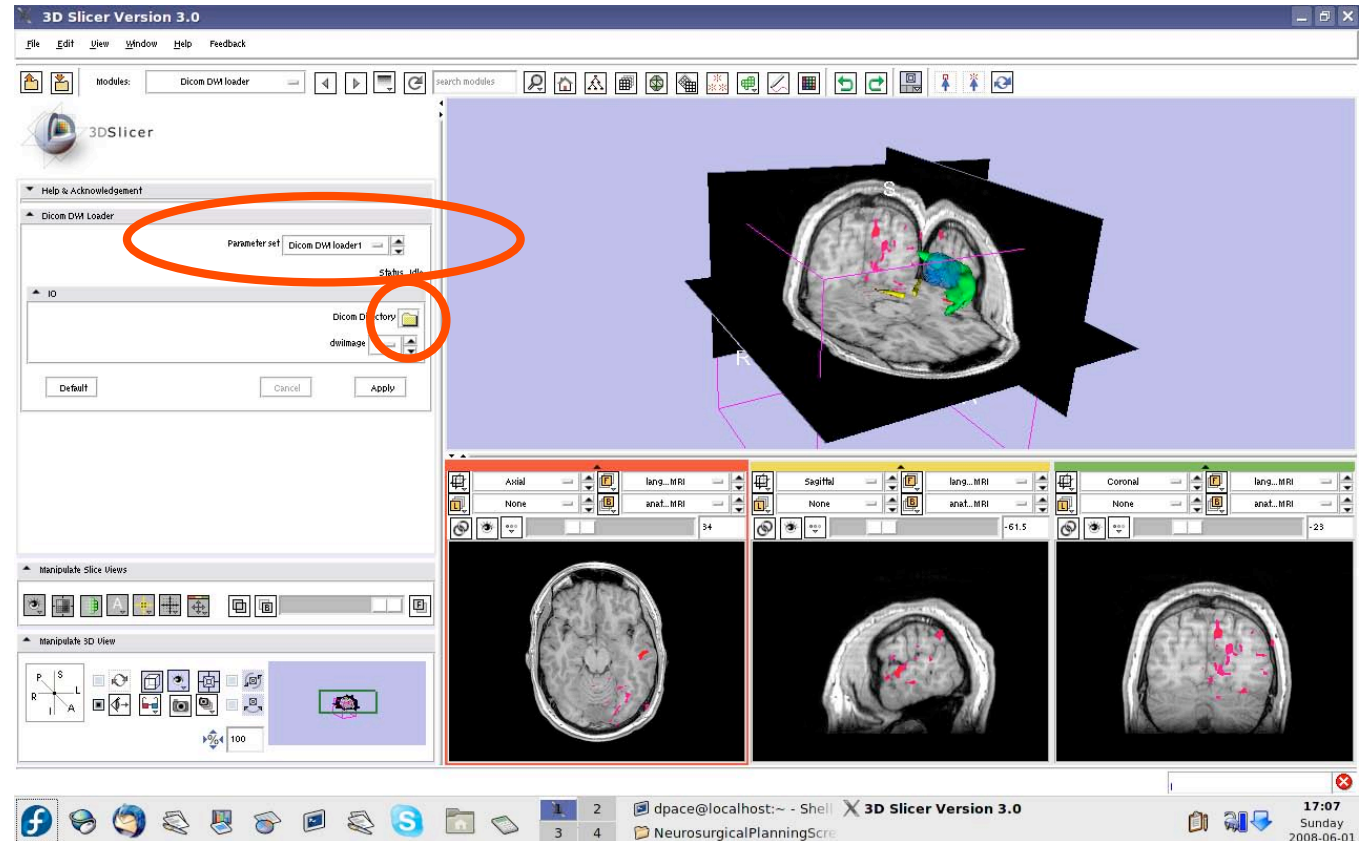




Load the DWI data

Create a new
CommandLine
Module

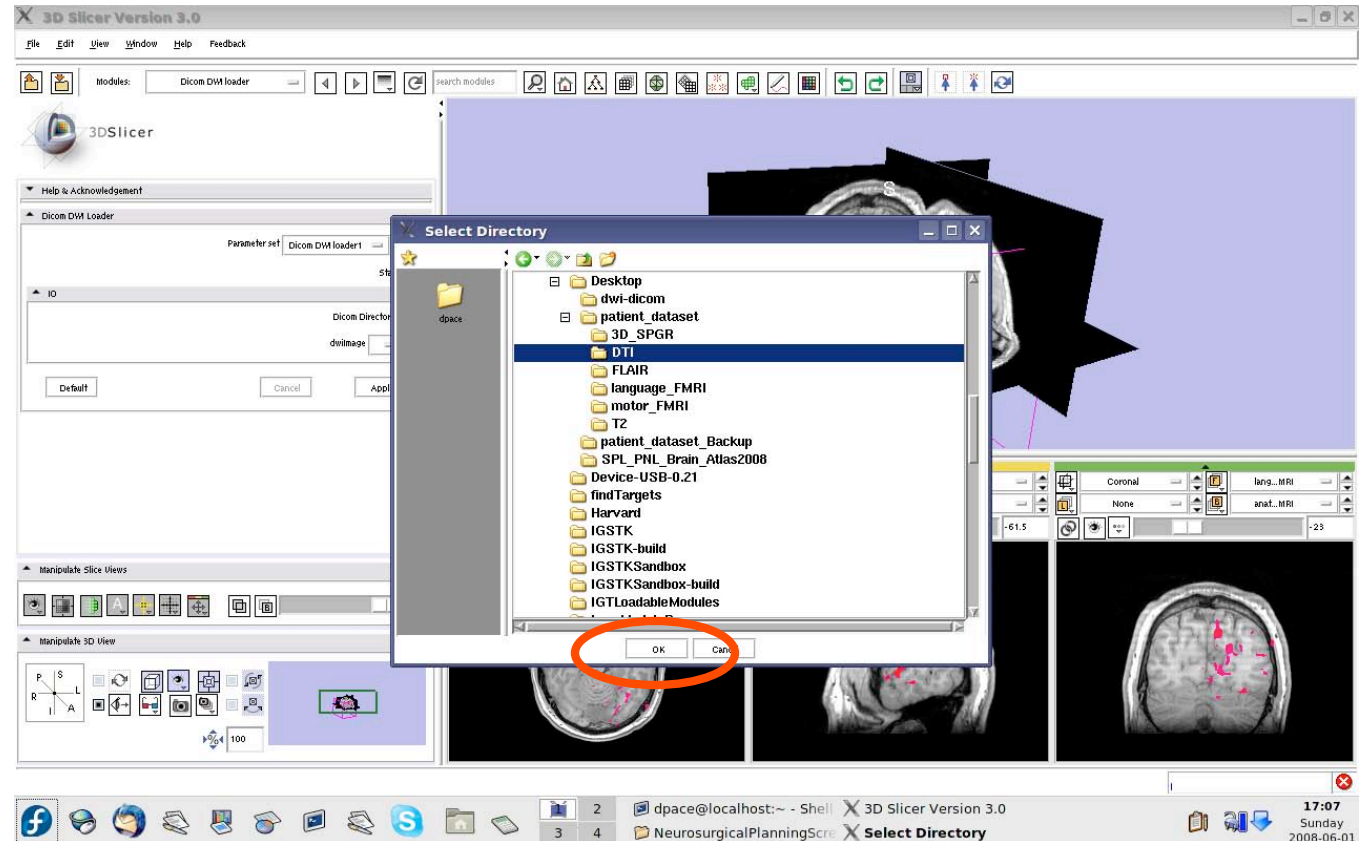
Click on the
folder icon to
set the
DICOM
directory





Load the DWI data

Click on the DTI folder within the patient dataset, then click “OK”



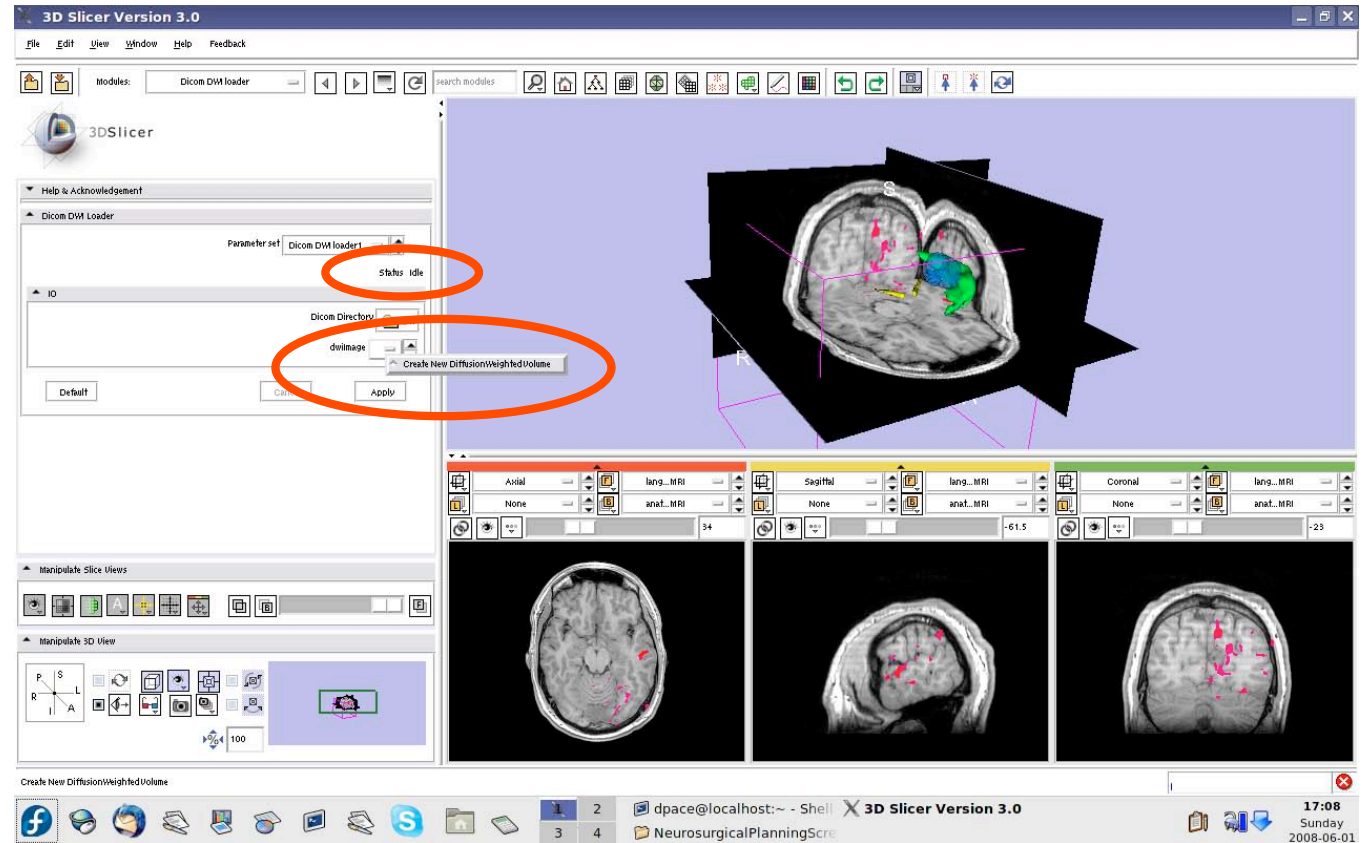


Load the DWI data

Set the dwiImage to “Create New Diffusion Weighted Volume”

Click “Apply”

This step may take a few minutes. Wait until Status says “Completed”

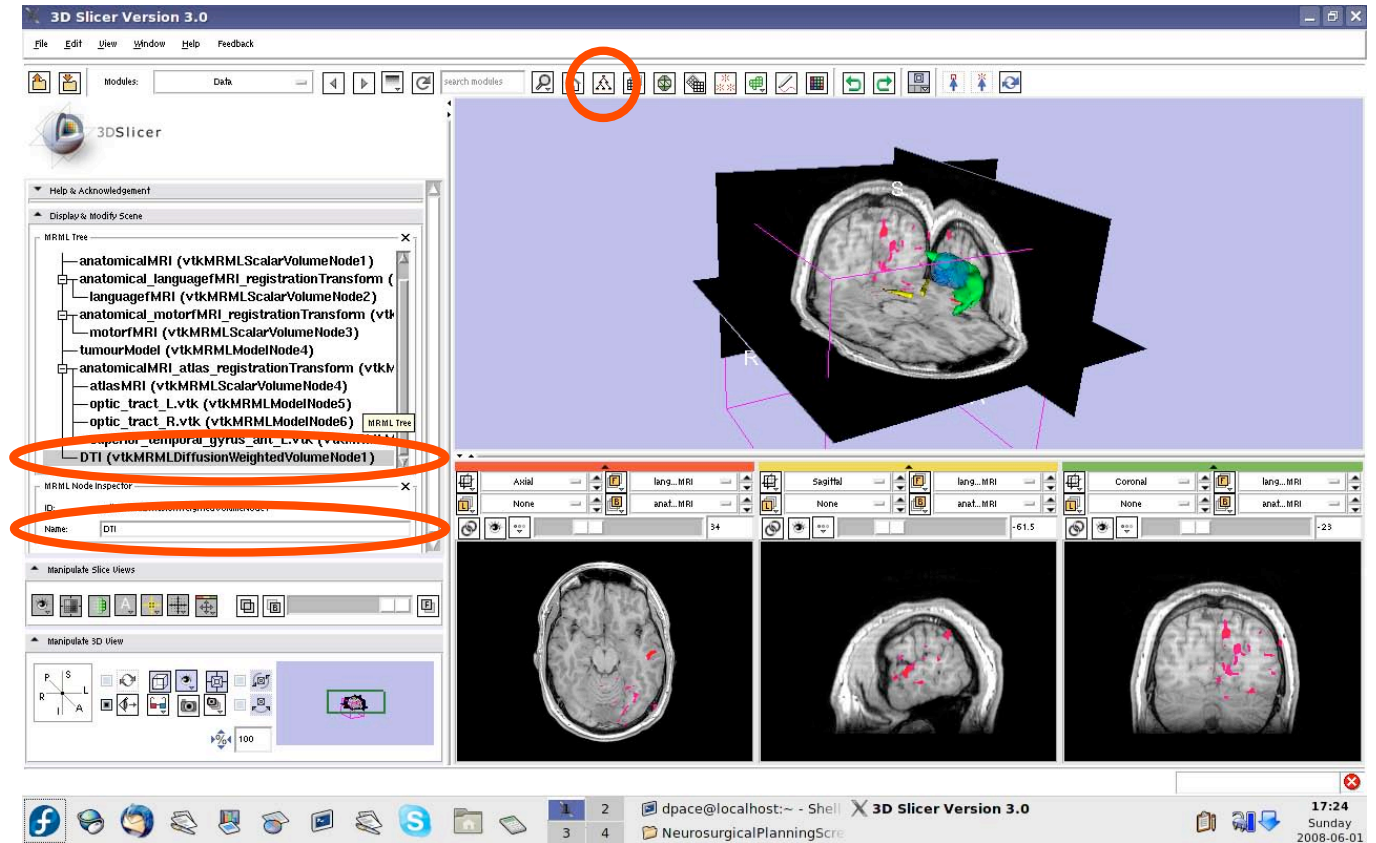




Load the DWI data

Open the Data module

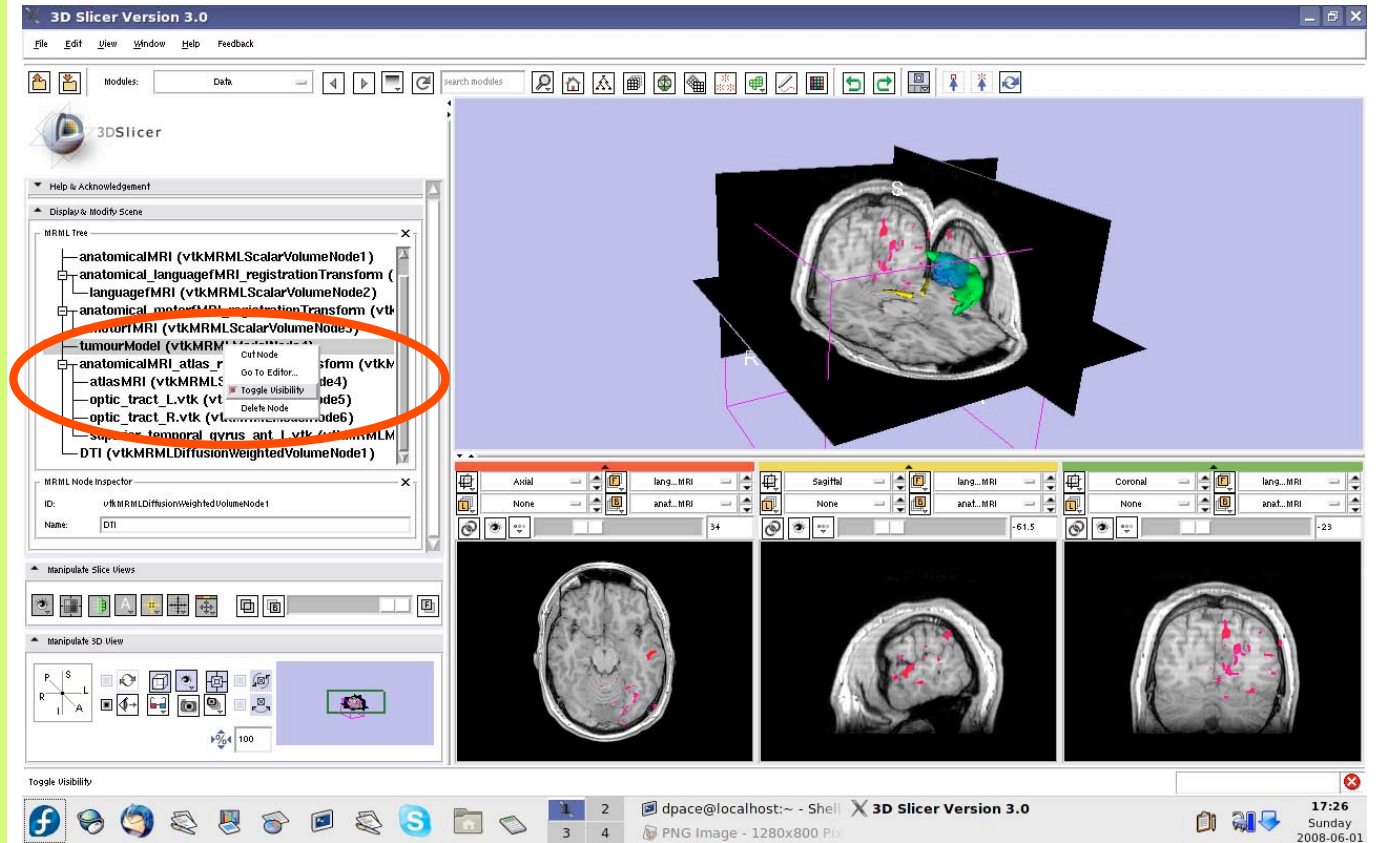
Rename the new DICOM DWI Loader Volume node to “DTI” by selecting it and changing the name in the MRML Node Inspector pane





Load the DWI data

Turn the visibility off for the four models in the scene (tumour, left and right optic tracts, and left anterior superior temporal gyrus) by right-clicking and selecting “Toggle Visibility”



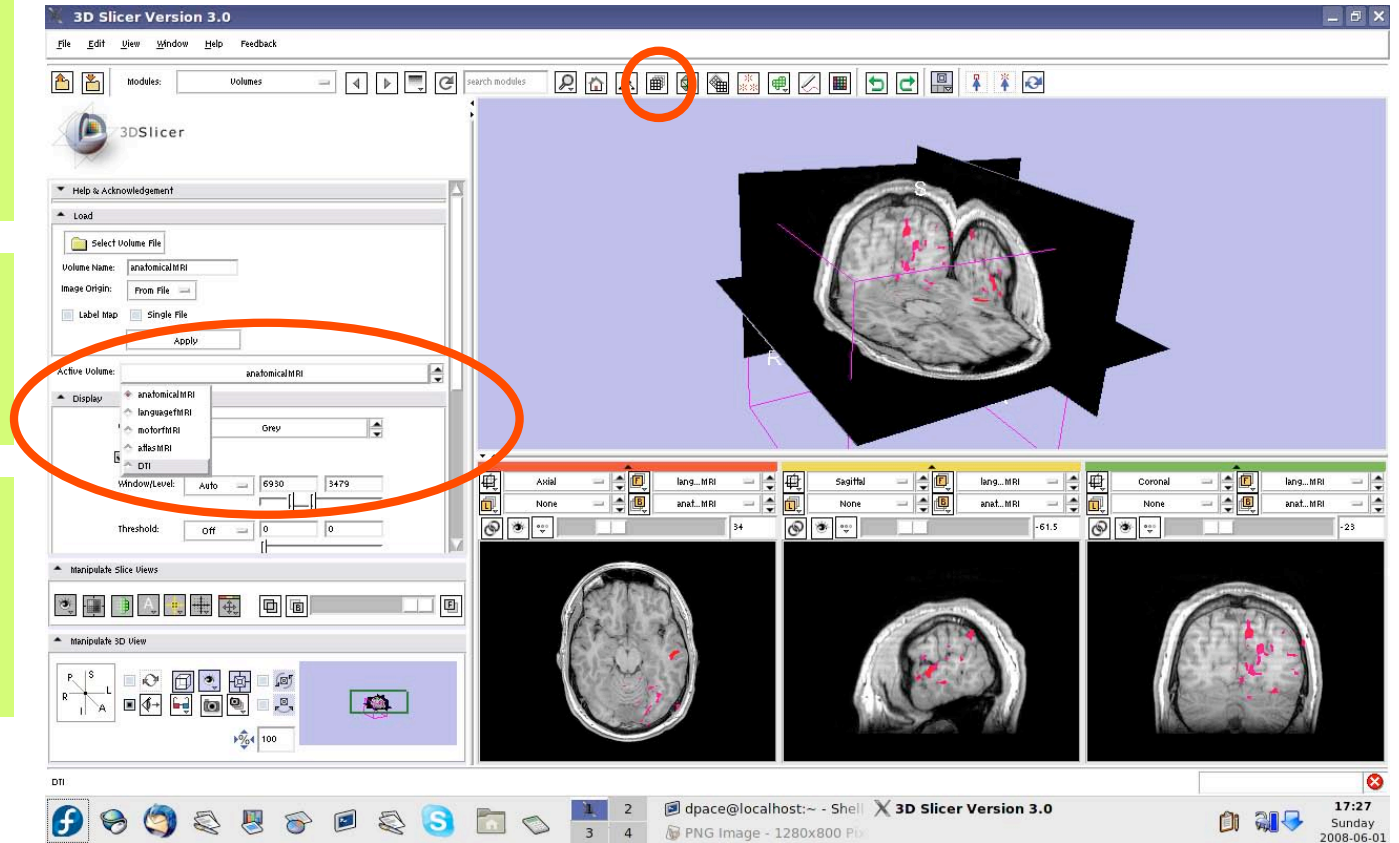


Inspect the DWI data

Open the Volumes module

Open the Display pane

Set the active volume to the DWI volume





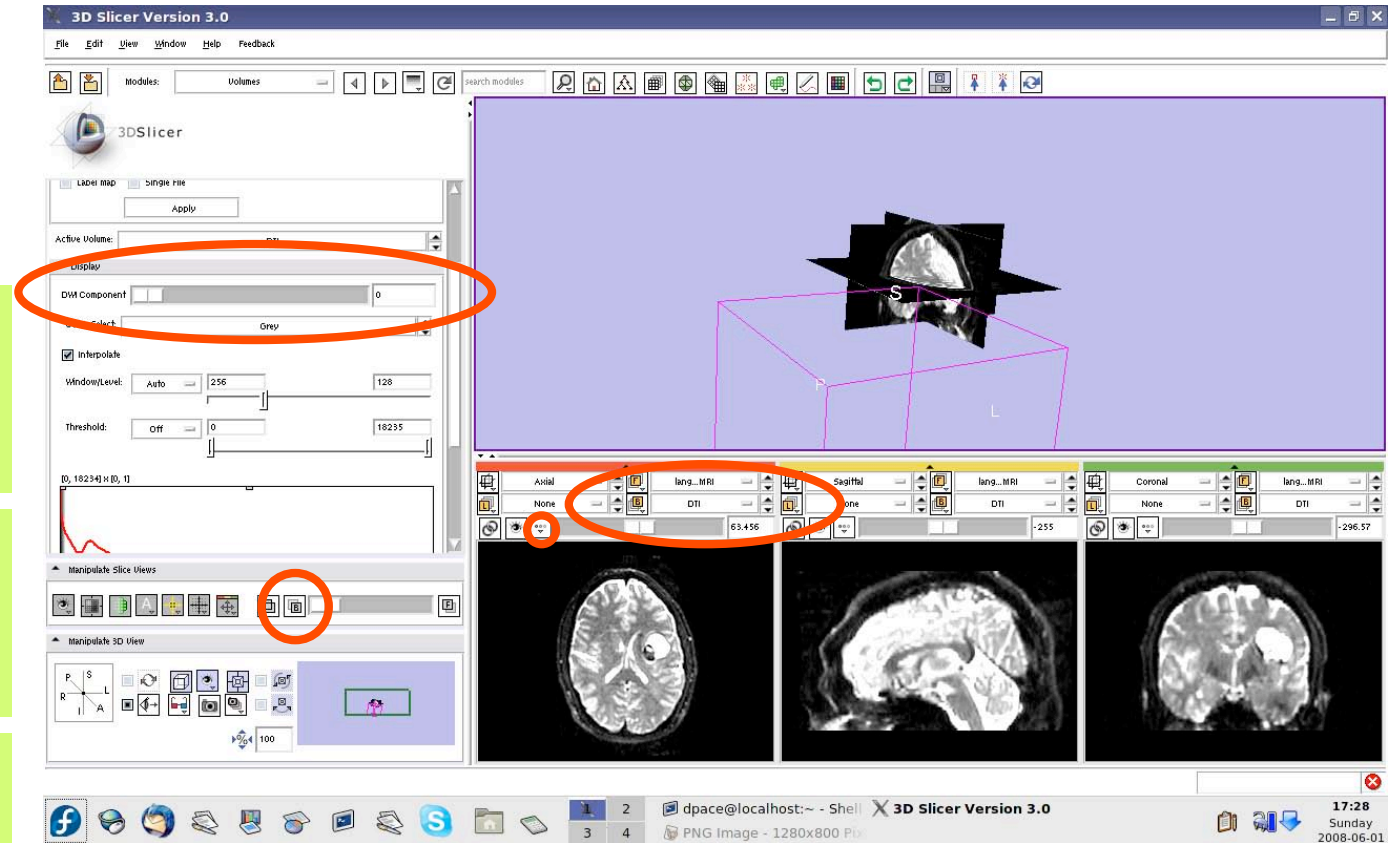
Inspect the DWI data

Note that the Display pane now allows you to select the DWI volume

Set the background to DTI

Click on the Background layer button

Click on the “fit to window” button



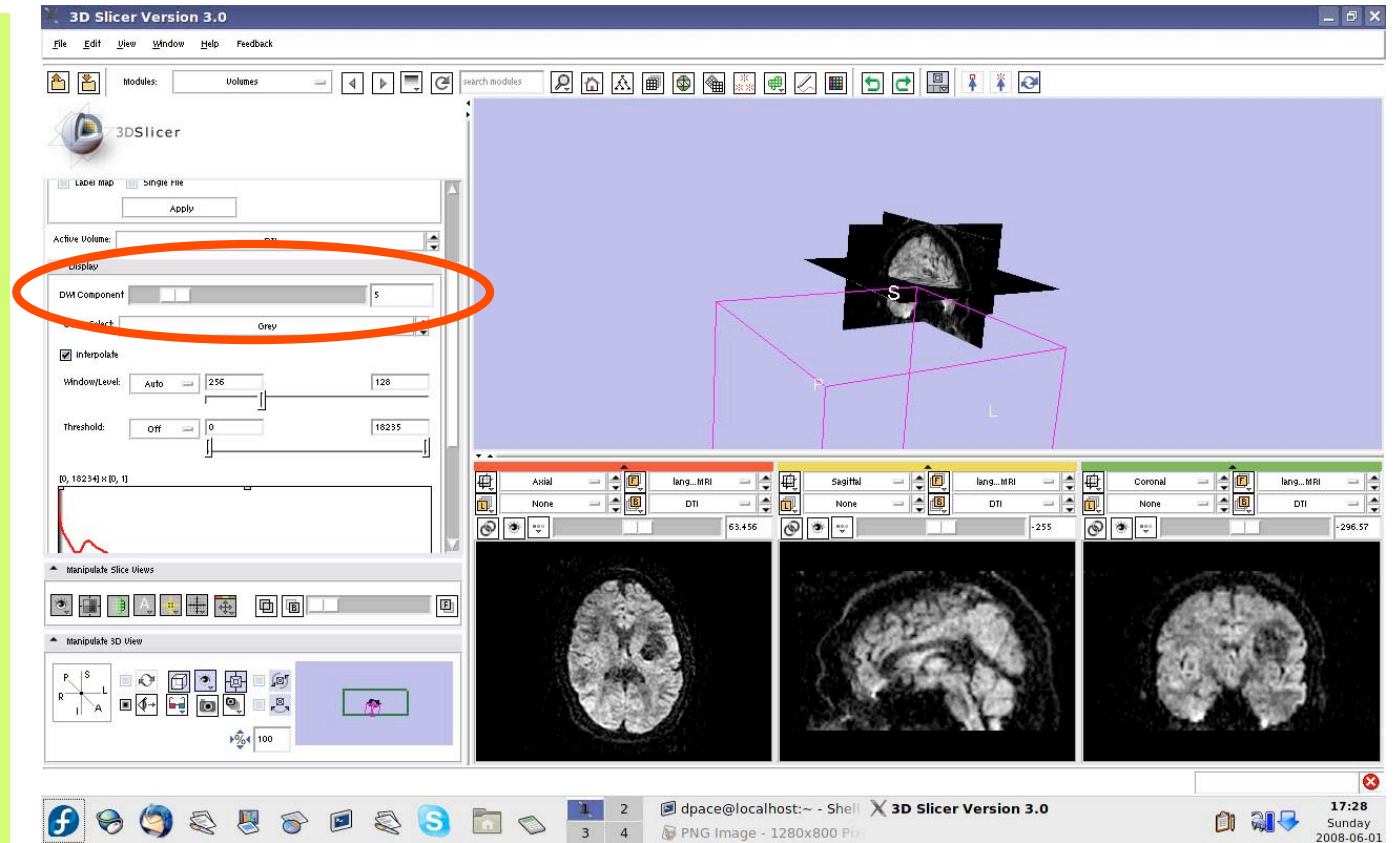


Inspect the DWI data

Scroll through the 36 volumes in the set:

-0 to 4 are baseline images

-5 to 35 are diffusion weighted images

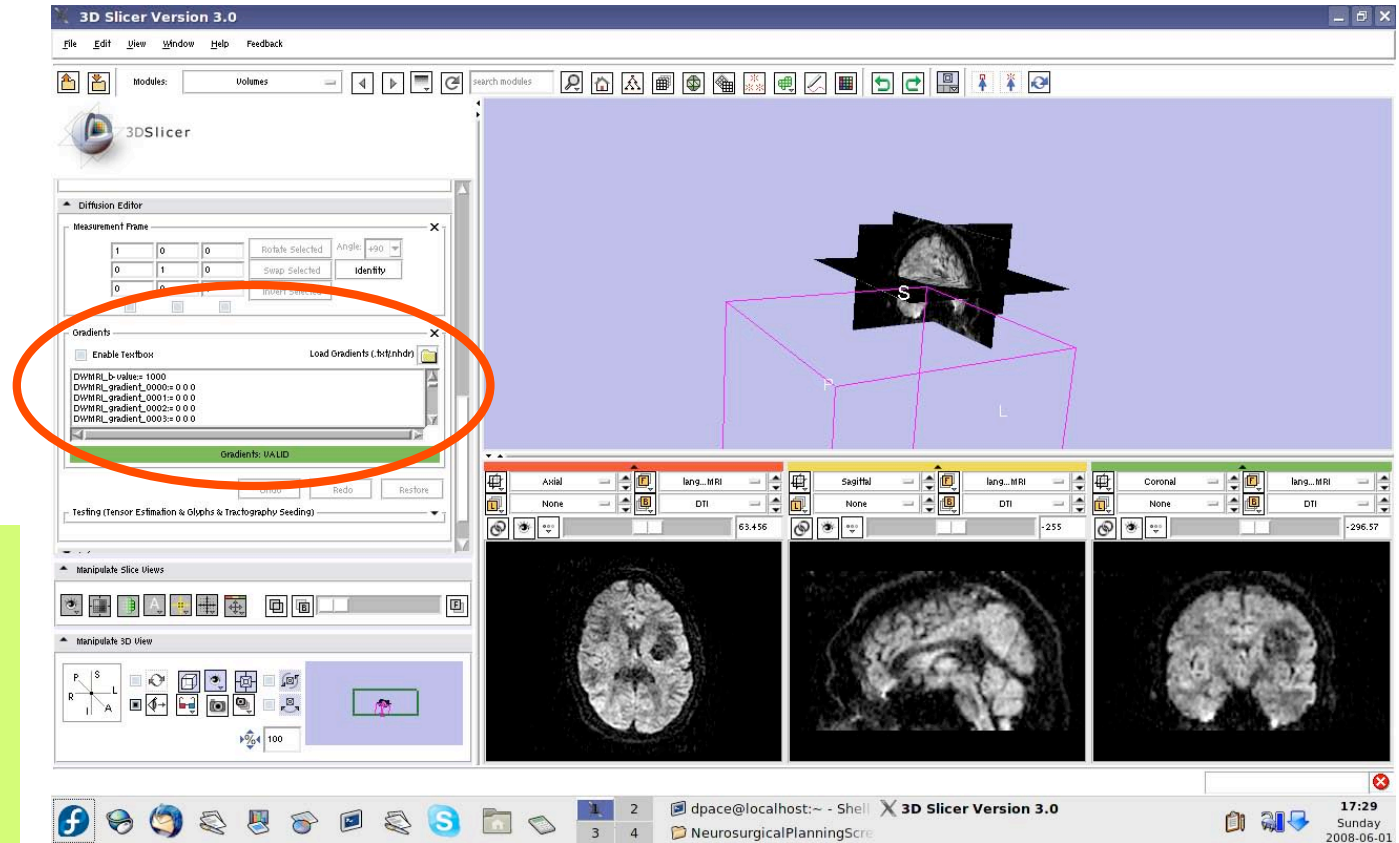




Create the tensors

Note that the Diffusion Editor pane within the volumes module is activated when diffusion weighted images are loaded

Expand the Diffusion Editor pane and note the gradients used to acquire the images

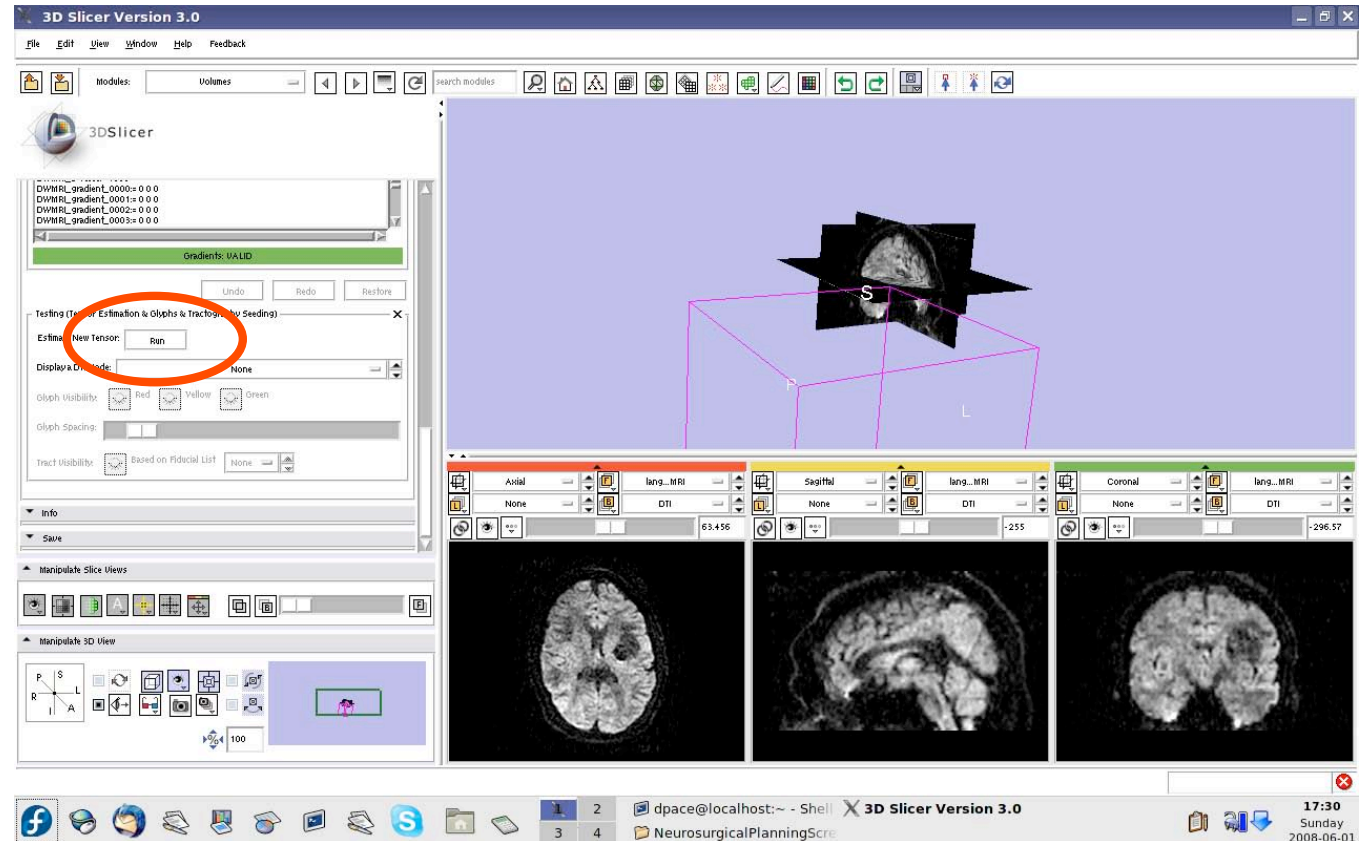




Create the tensors

Expand the “Testing (Tensor Estimation & Glyphs & Tractography Seeding)” pane

Click “Run” to compute the tensors





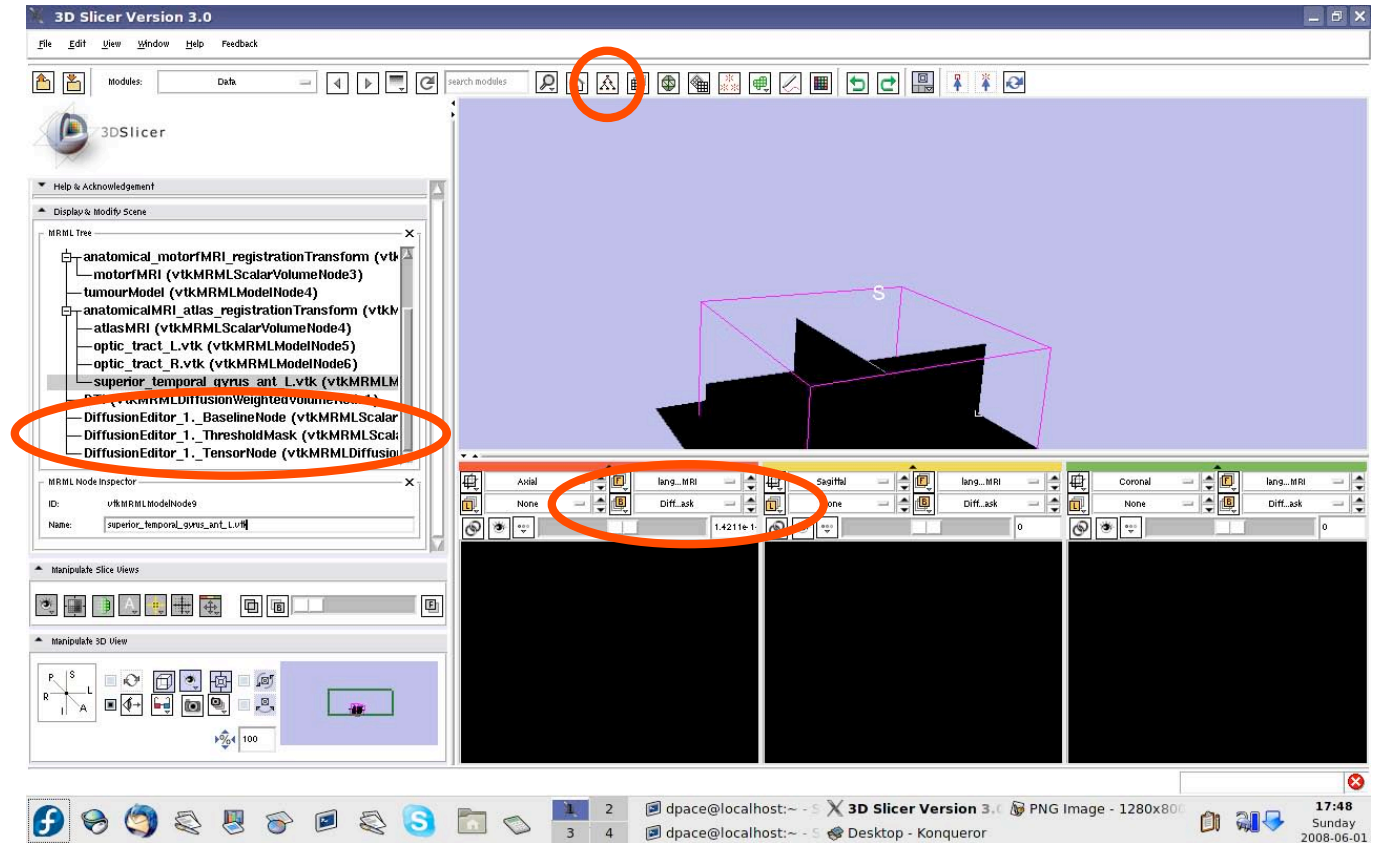
Create the tensors

Open the Data module

3 new nodes:

- **Baseline Node:** image without diffusion weighting
- **Threshold Mask:** mask excluding the background
- **TensorNode** = the tensors

Set the background to the tensor node



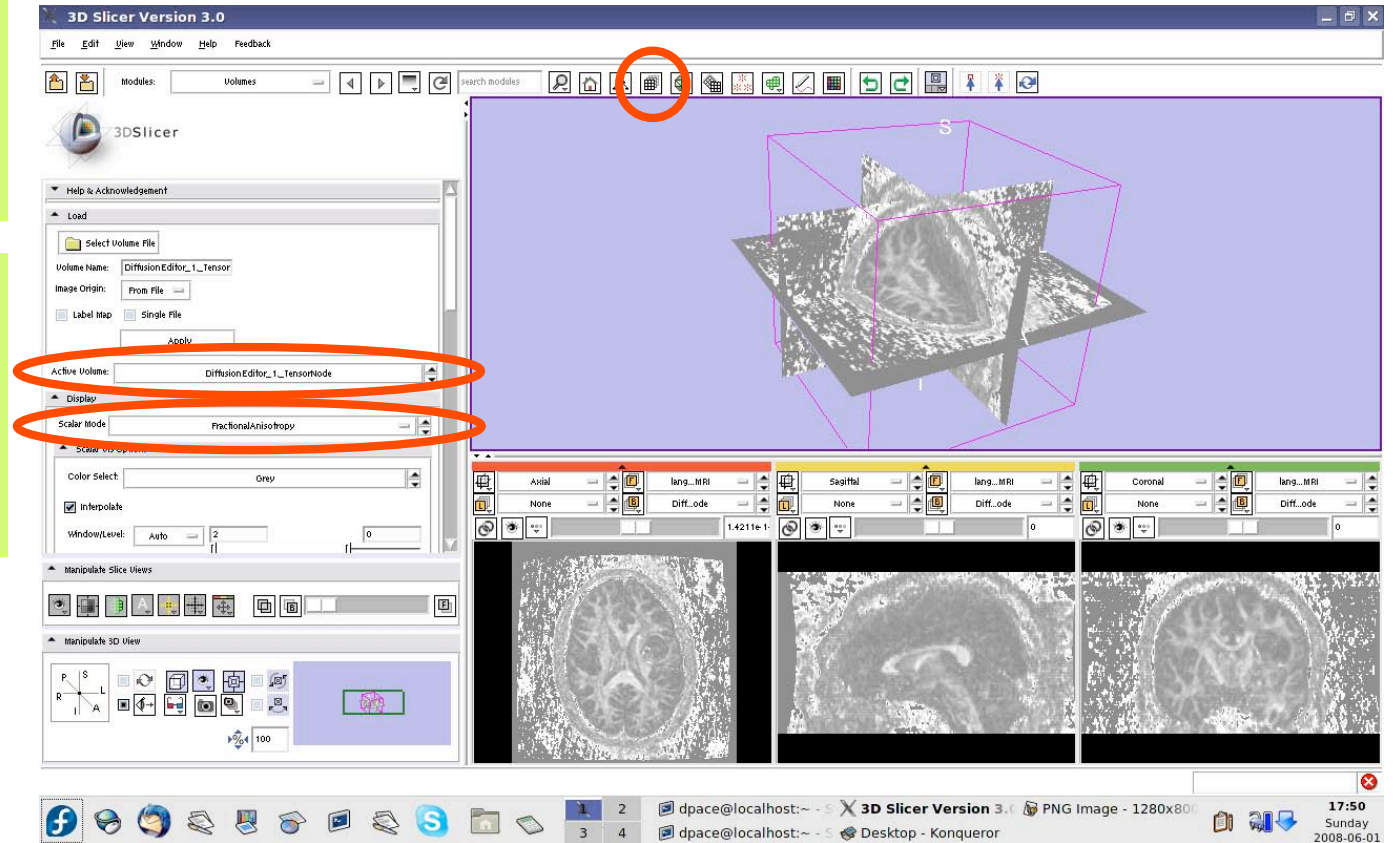


Create the tensors

Open the Volumes module

Set the active volume to the diffusion tensor node

The fractional anisotropy is displayed by default

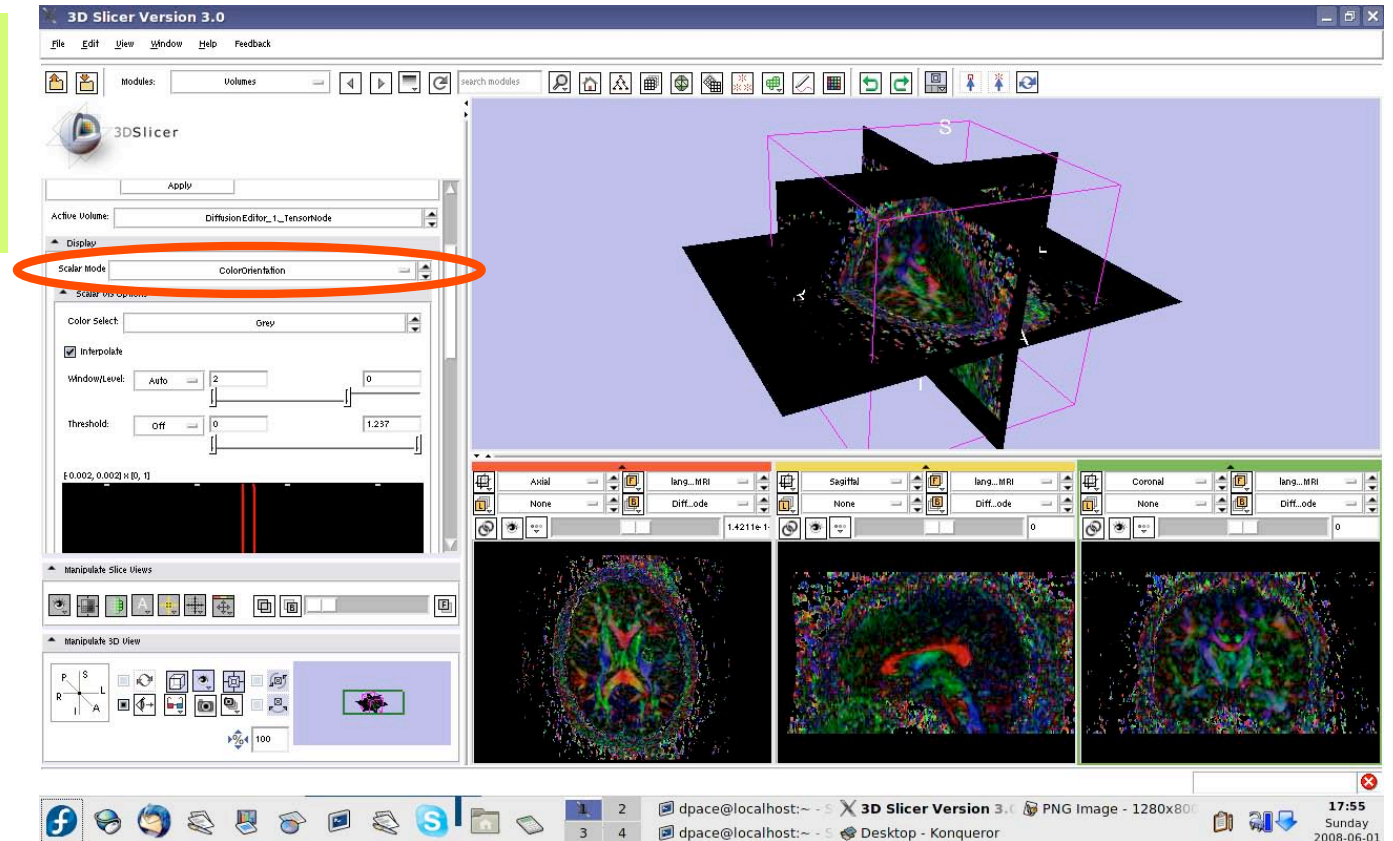




Create the tensors

Set the Scalar Mode to “Color Orientation”

“Color Orientation” maps the direction of the tensor’s main eigenvector to a colormap

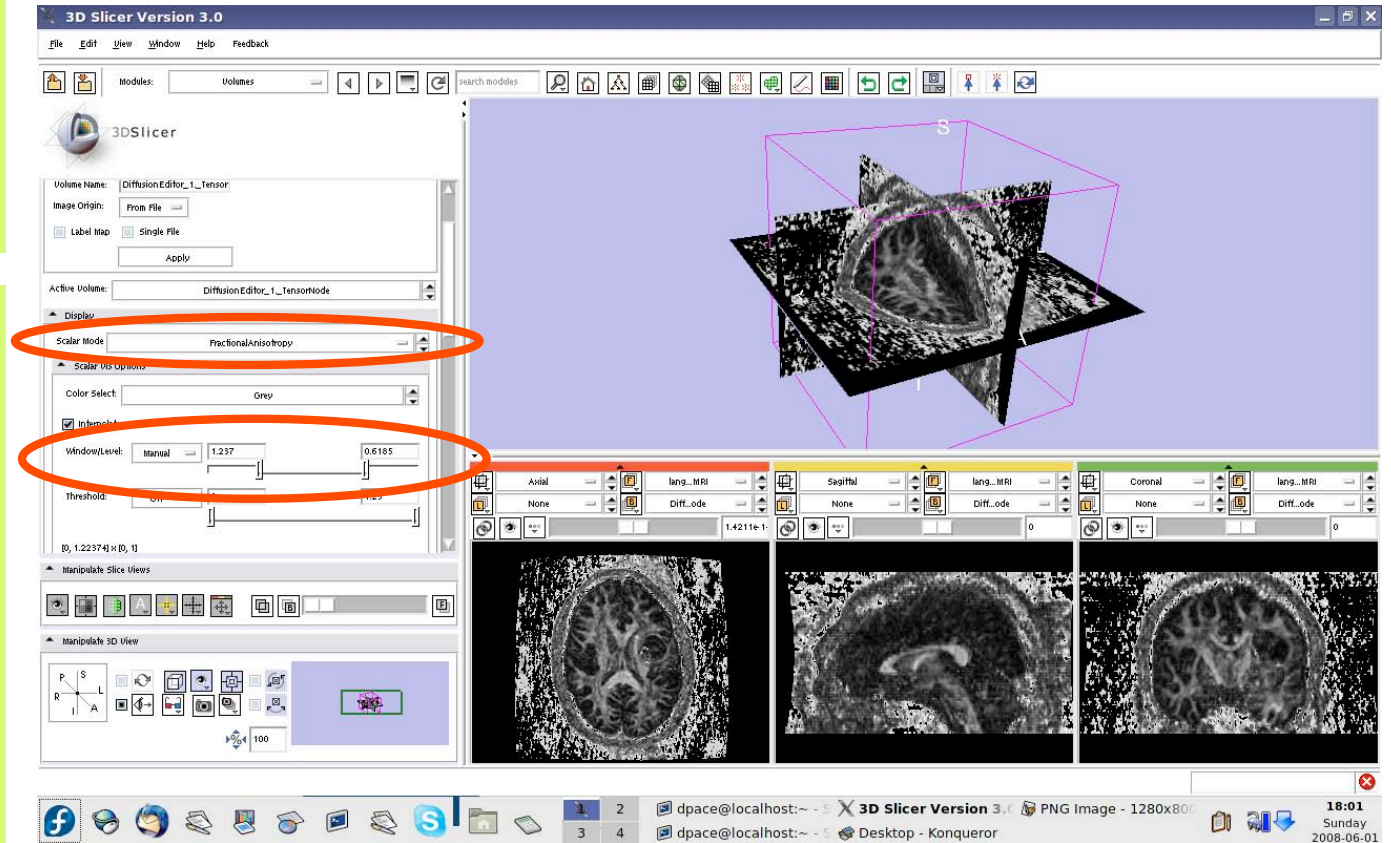




View the tensors

Set the Scalar Mode back to “Fractional Anisotropy”

Set the Window/Level to Manual and adjust the levels to invert the image so that the tensors will be easier to see



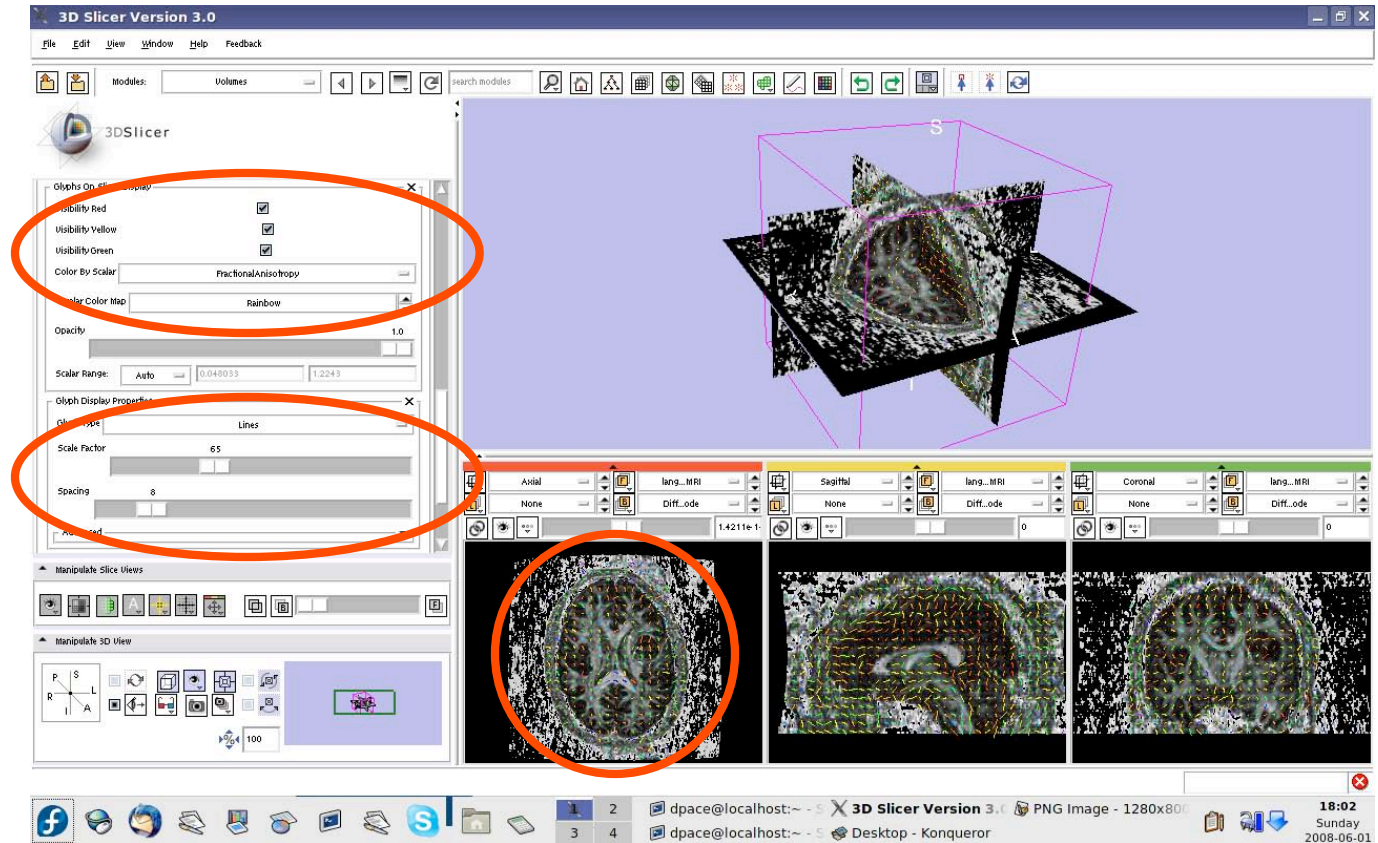


View the tensors

Scroll down and turn the glyphs on for all three views

Adjust the scale factor and the spacing

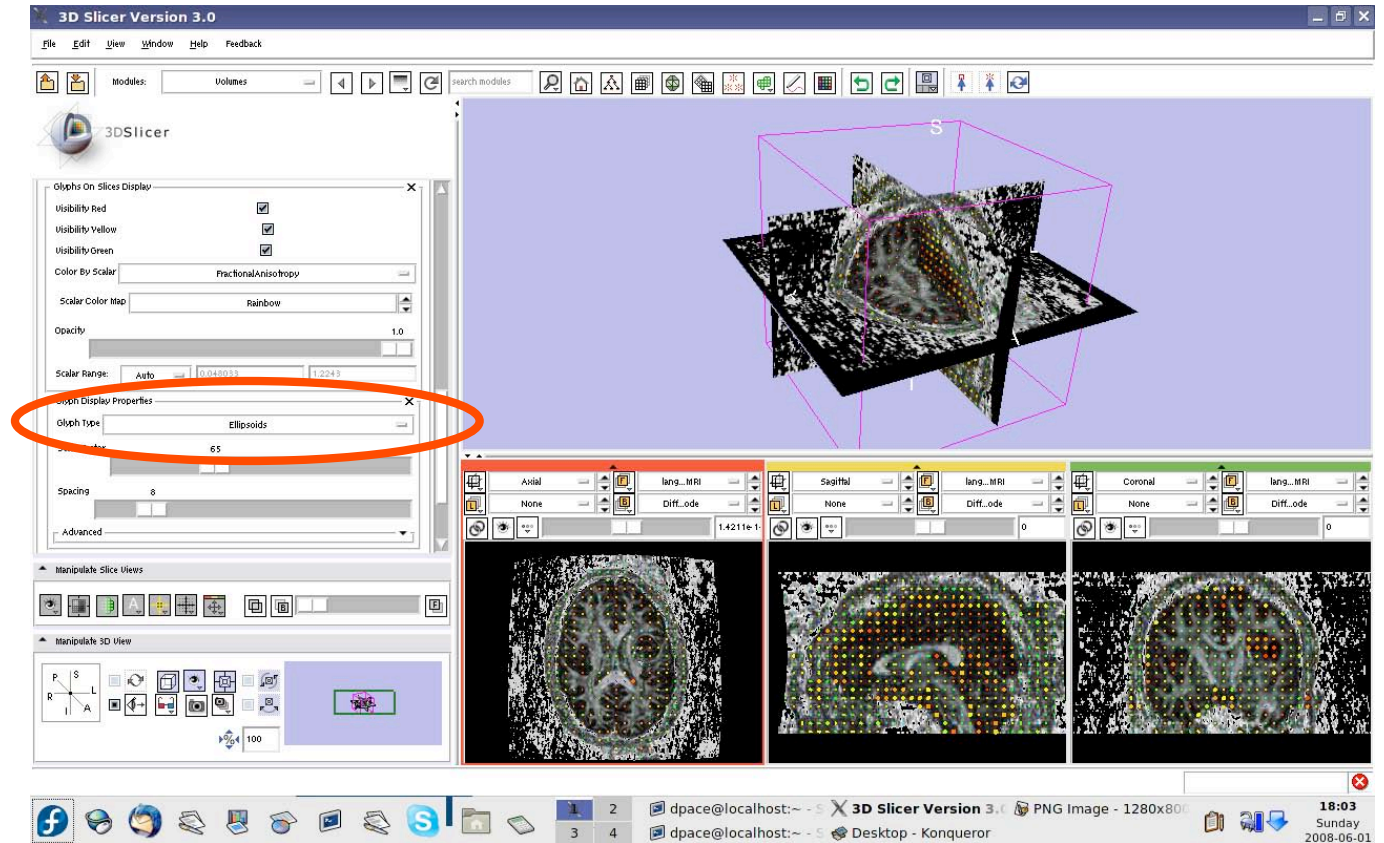
The line direction is the direction of the tensor's main eigenvector, while the length and the colour shows the tensor's magnitude





View the tensors

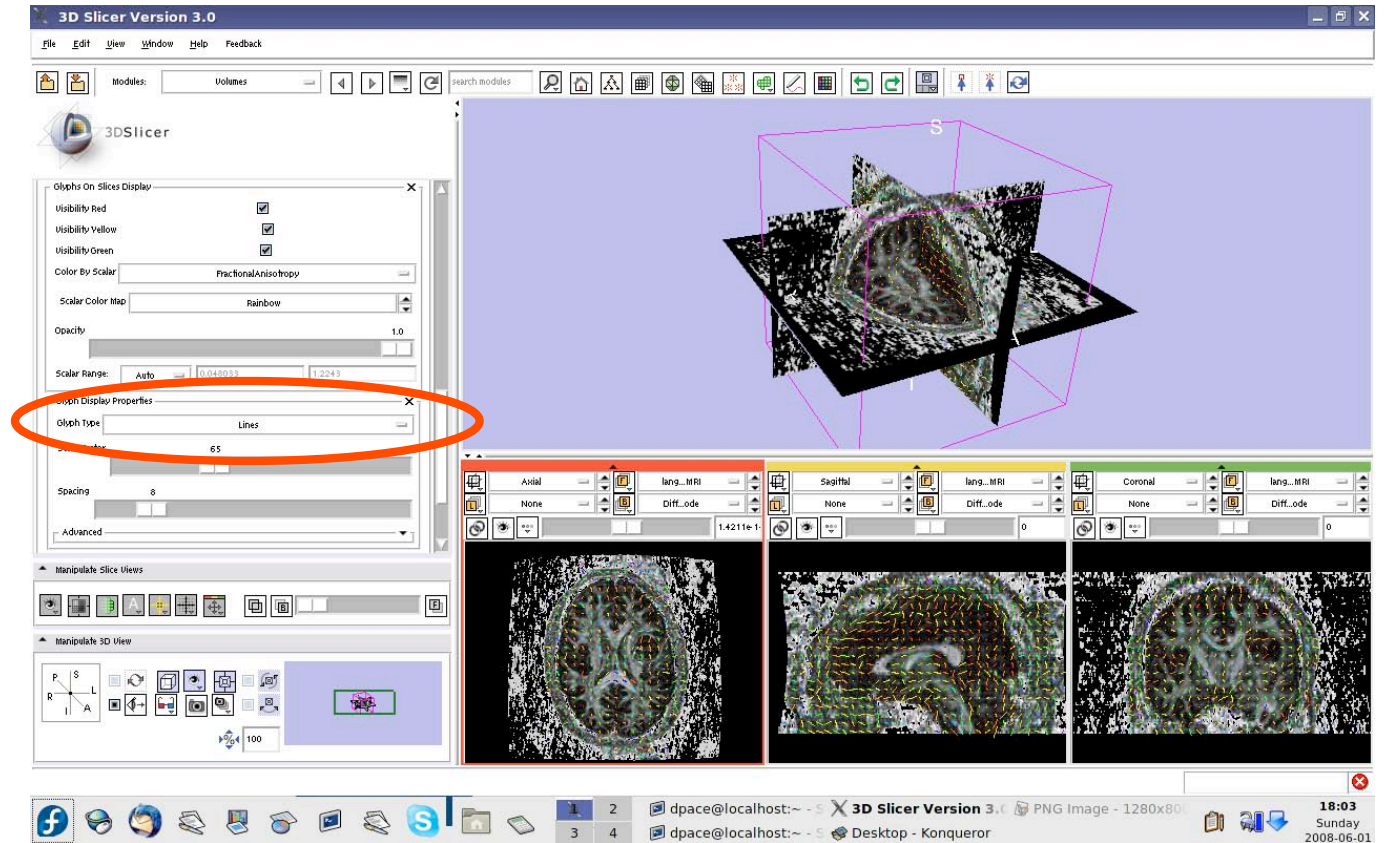
Change the
Glyph Type to
“Ellipsoids”





View the tensors

Change the
Glyph Type
back to “Lines”

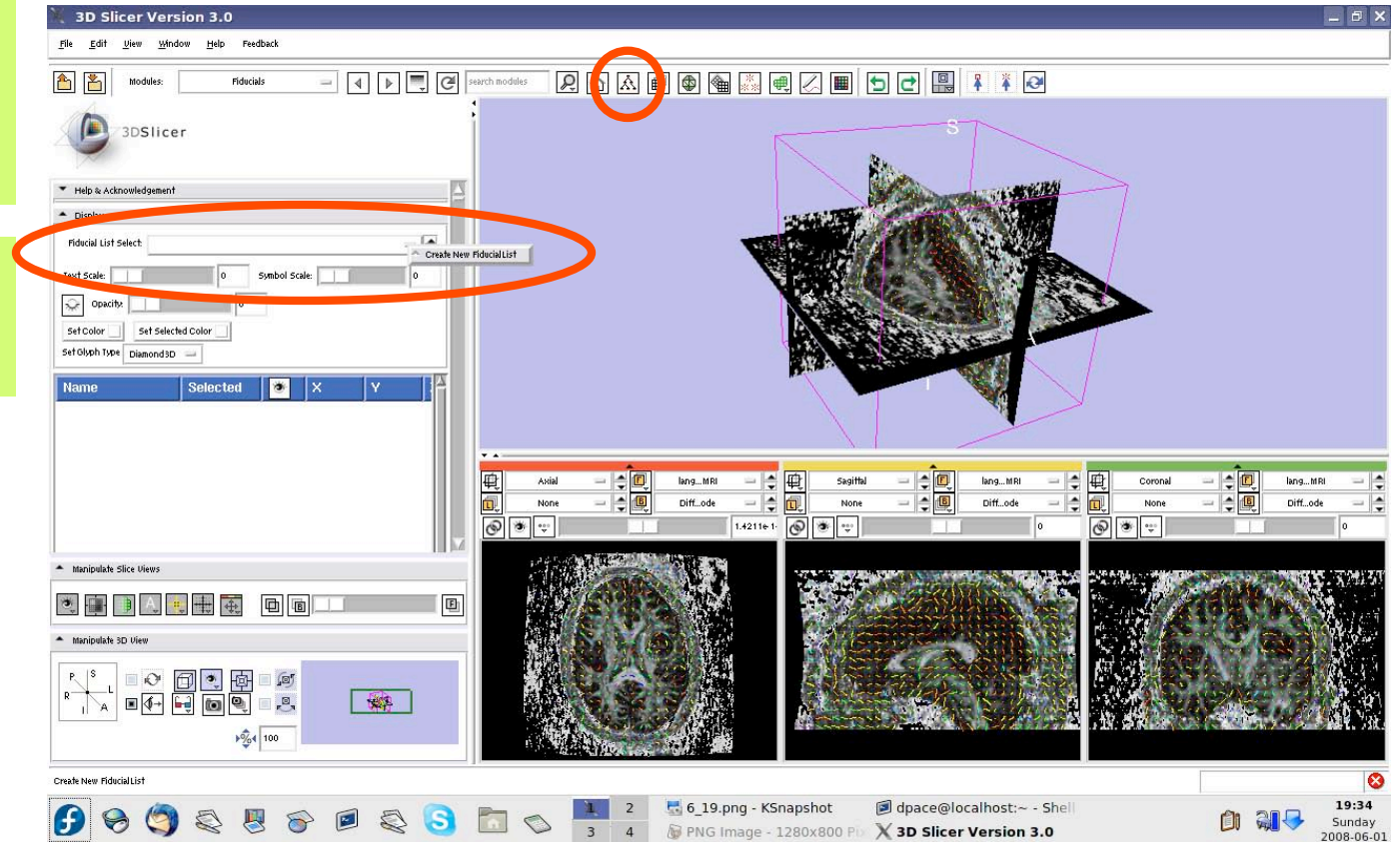




Place the tractography seed points

Open the
Fiducials
module

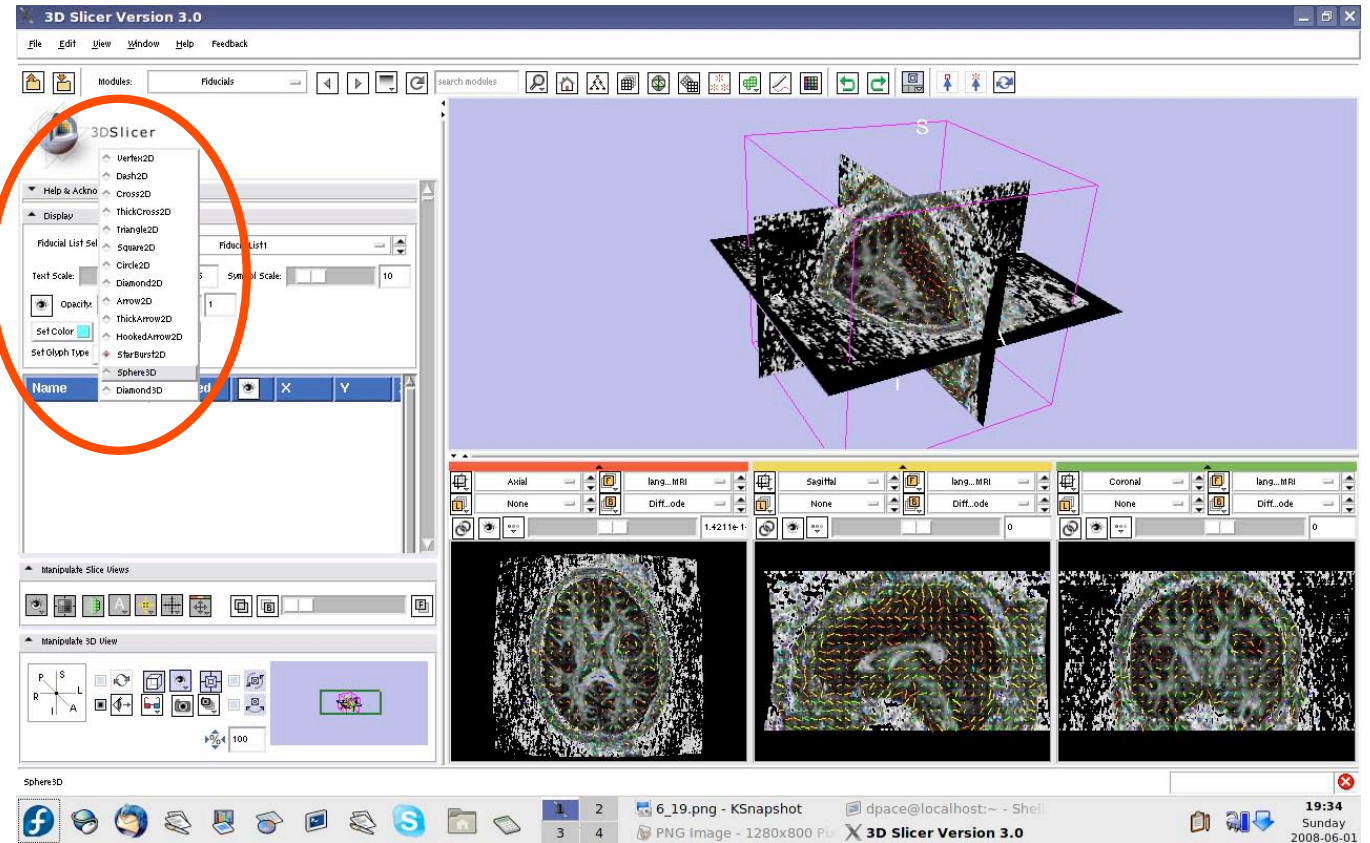
Create a new
Fiducial List





Place the tractography seed points

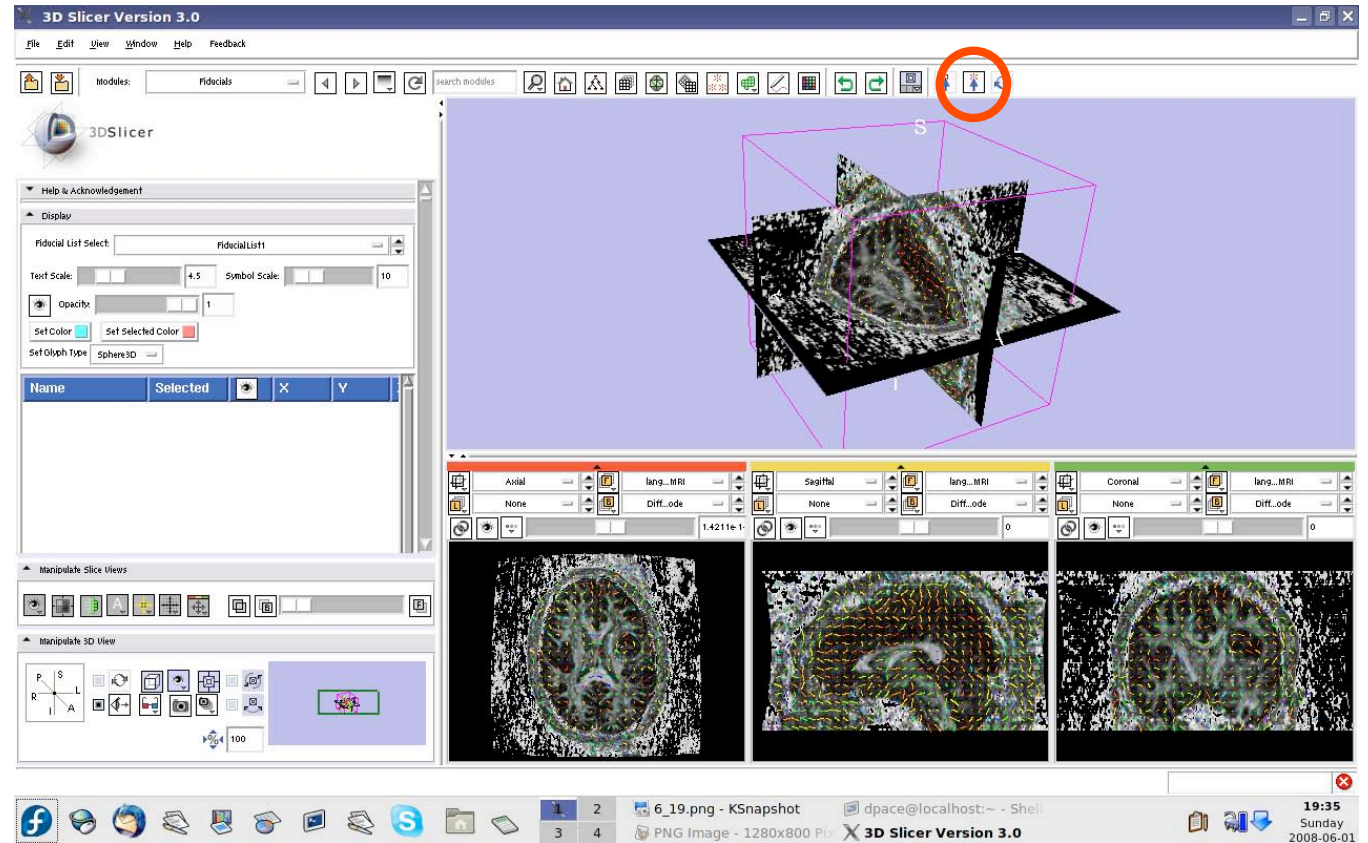
Set the glyph
type to
Sphere3D





Place the tractography seed points

Set the mouse mode to “place items”

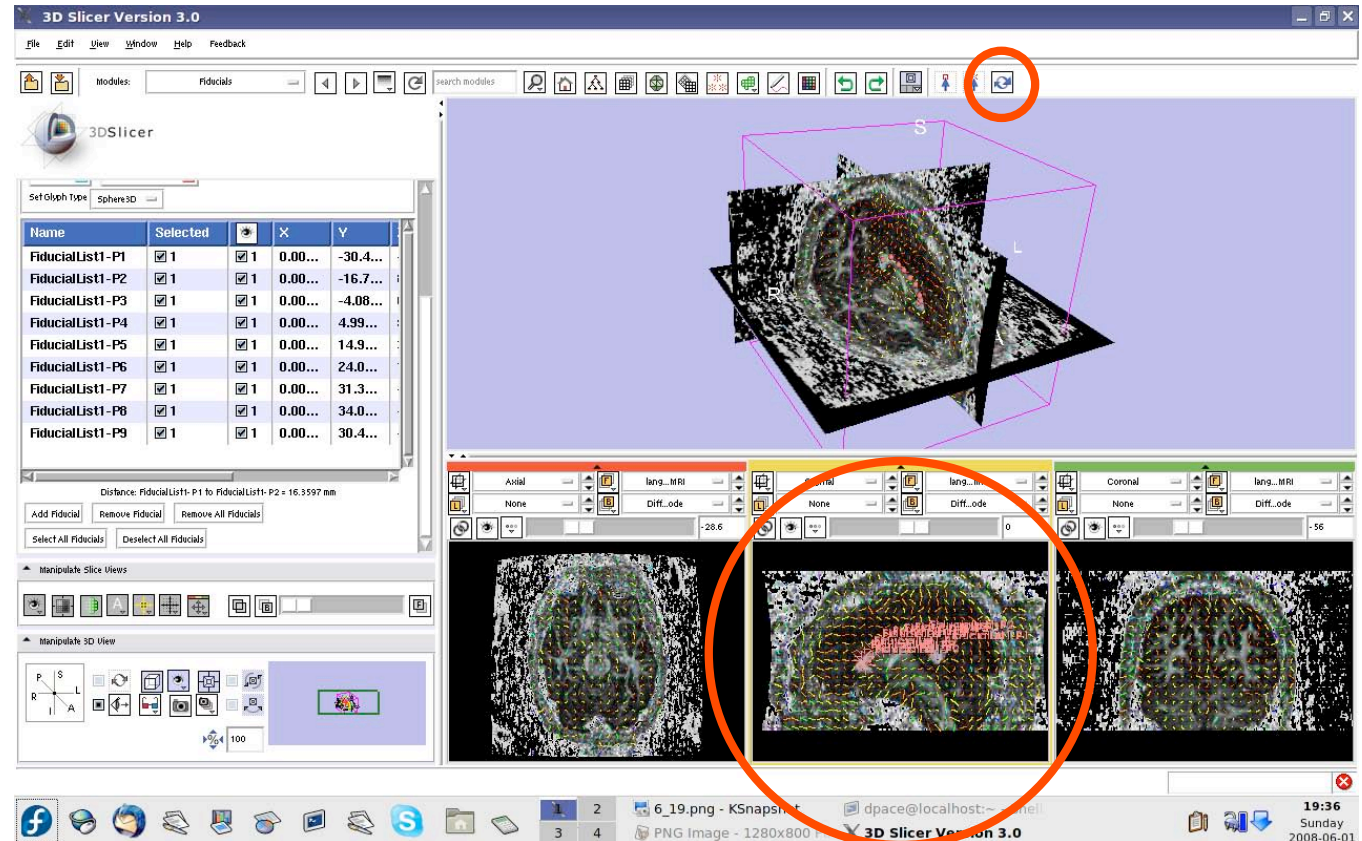




Place the tractography seed points

Click to place approximately ten fiducial points along the corpus callosum

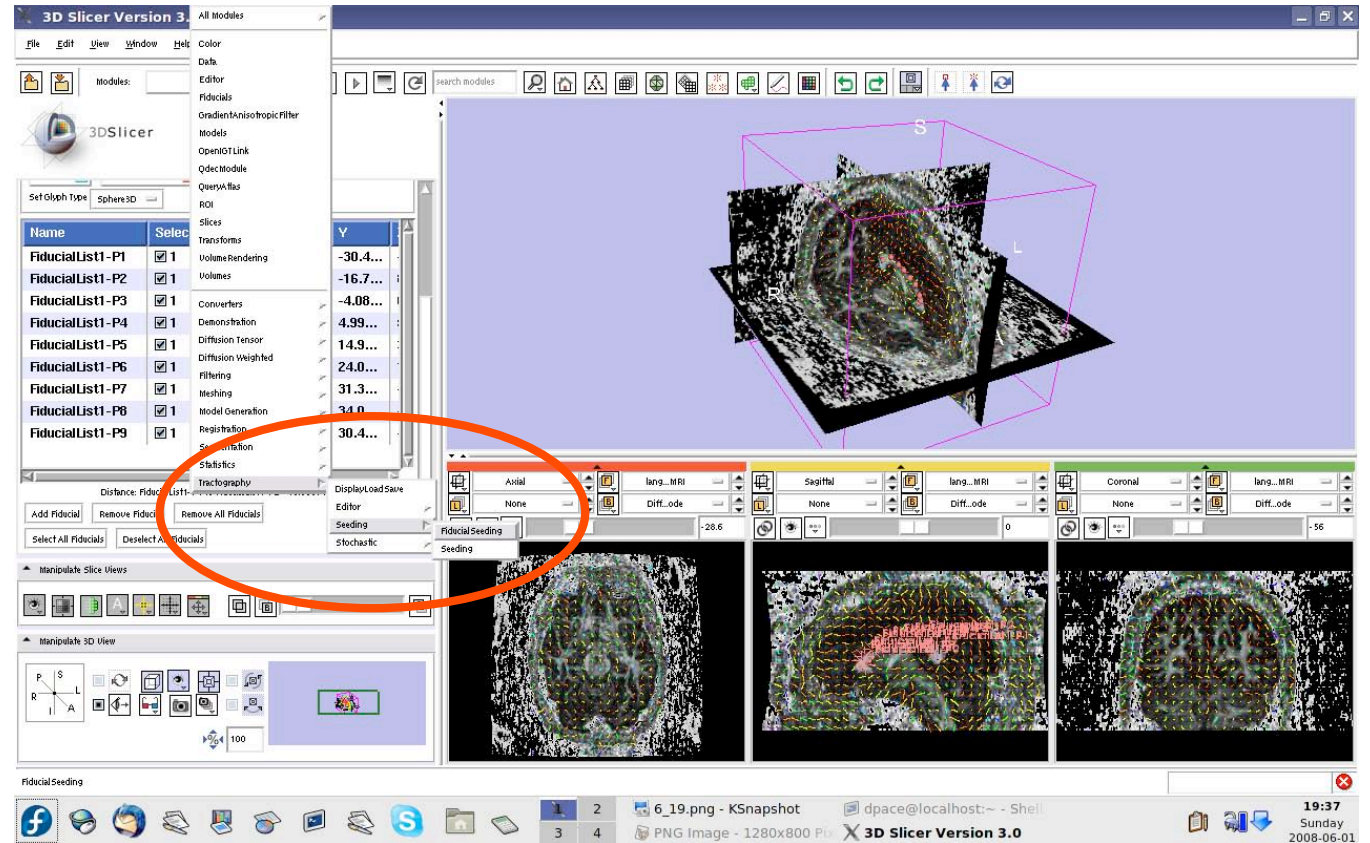
Set the mouse mode to “transform view”





Perform tractography (fiber tracking)

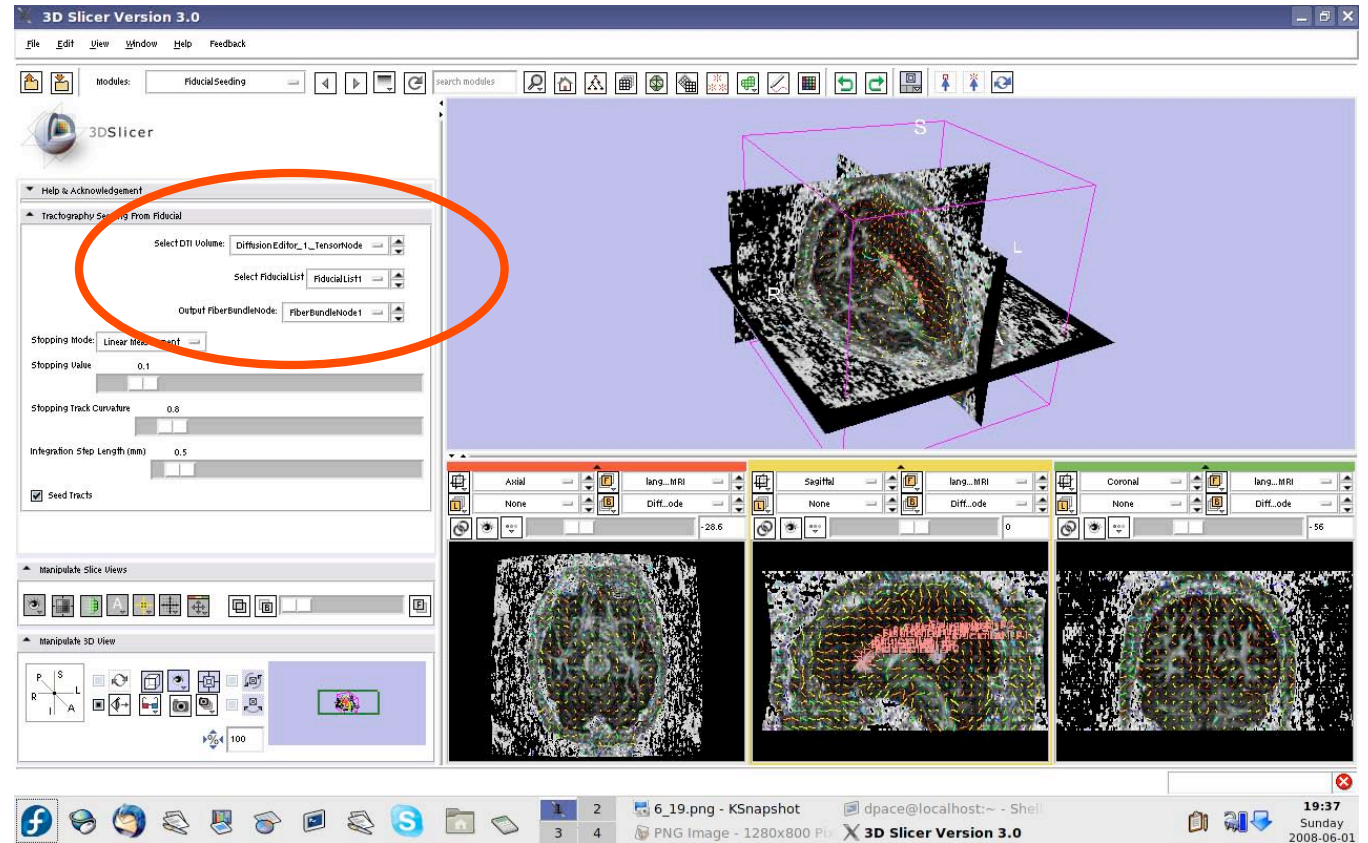
Open the tractography “Fiducial Seeding” module





Perform tractography (fiber tracking)

- DTI volume = Diffusion Editor_1_TensorNode
- Fiducial list = FiducialList1
- Output FiberBundle Node = Create New Fiber Bundle



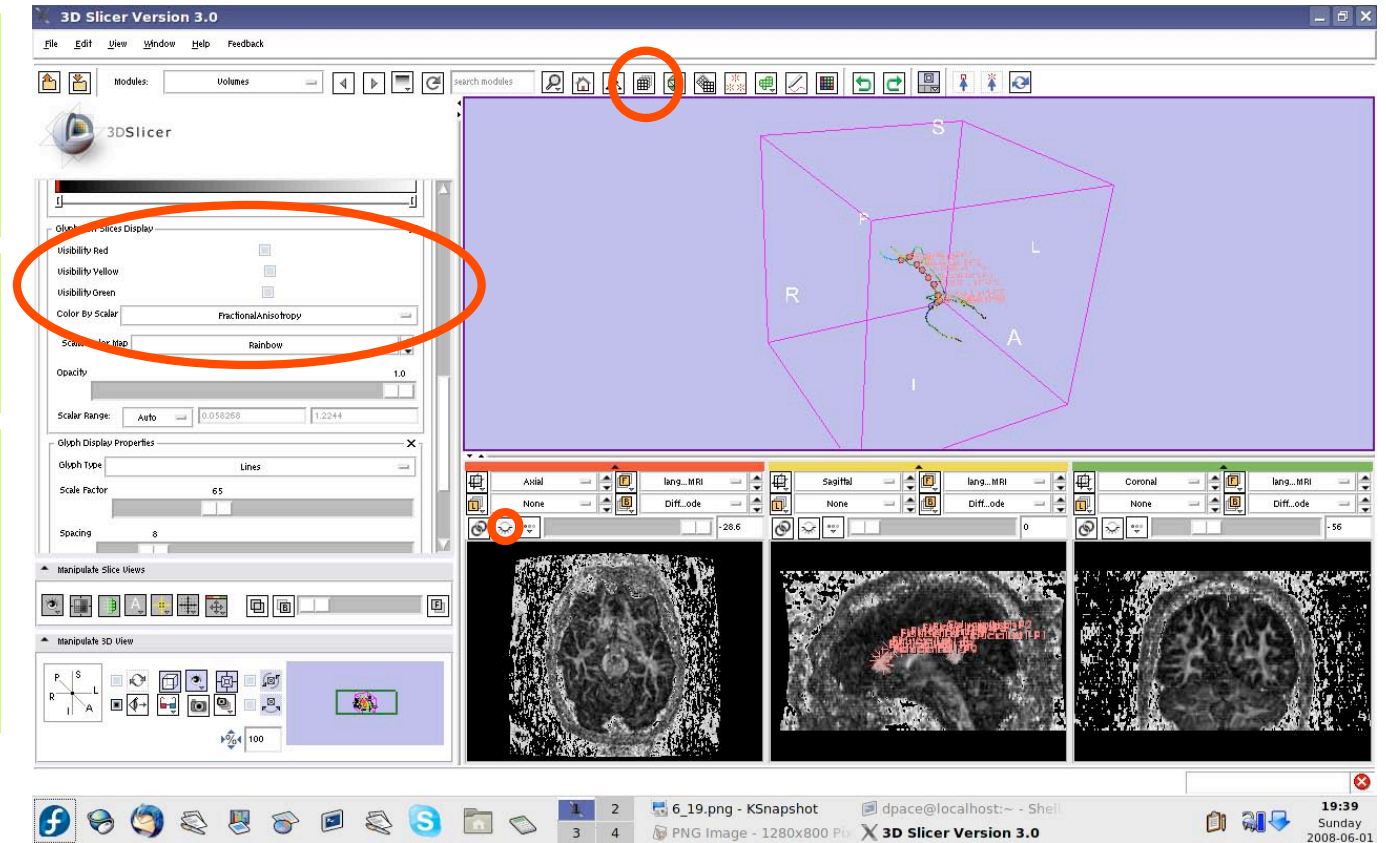


Perform tractography (fiber tracking)

Turn the glyphs off for all three views

Open the Volumes module

Click on the “visibility” button to turn off the slice visibility

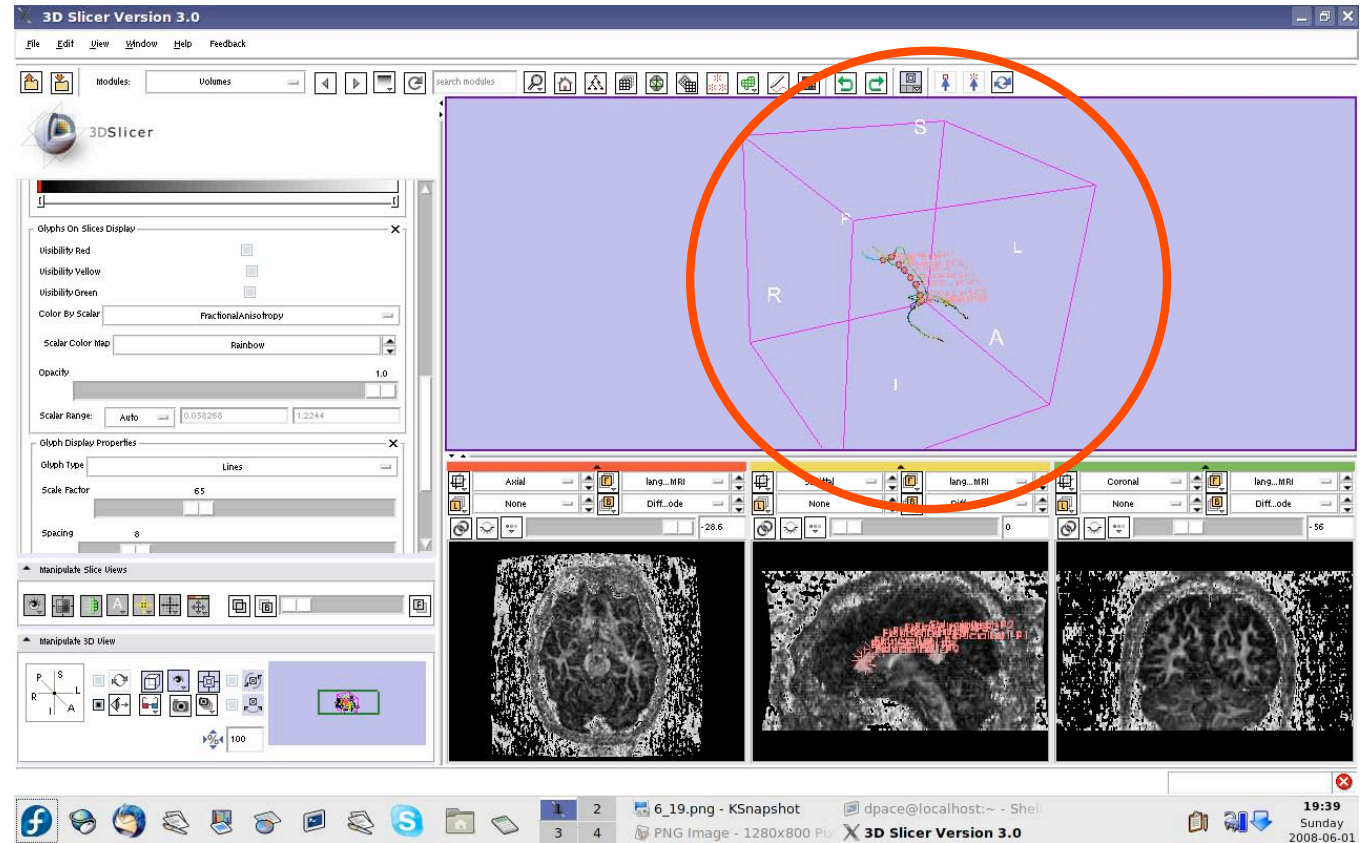




Perform tractography (fiber tracking)

One tract is generated for each fiducial.

The tract colour is the fractional anisotropy by default.

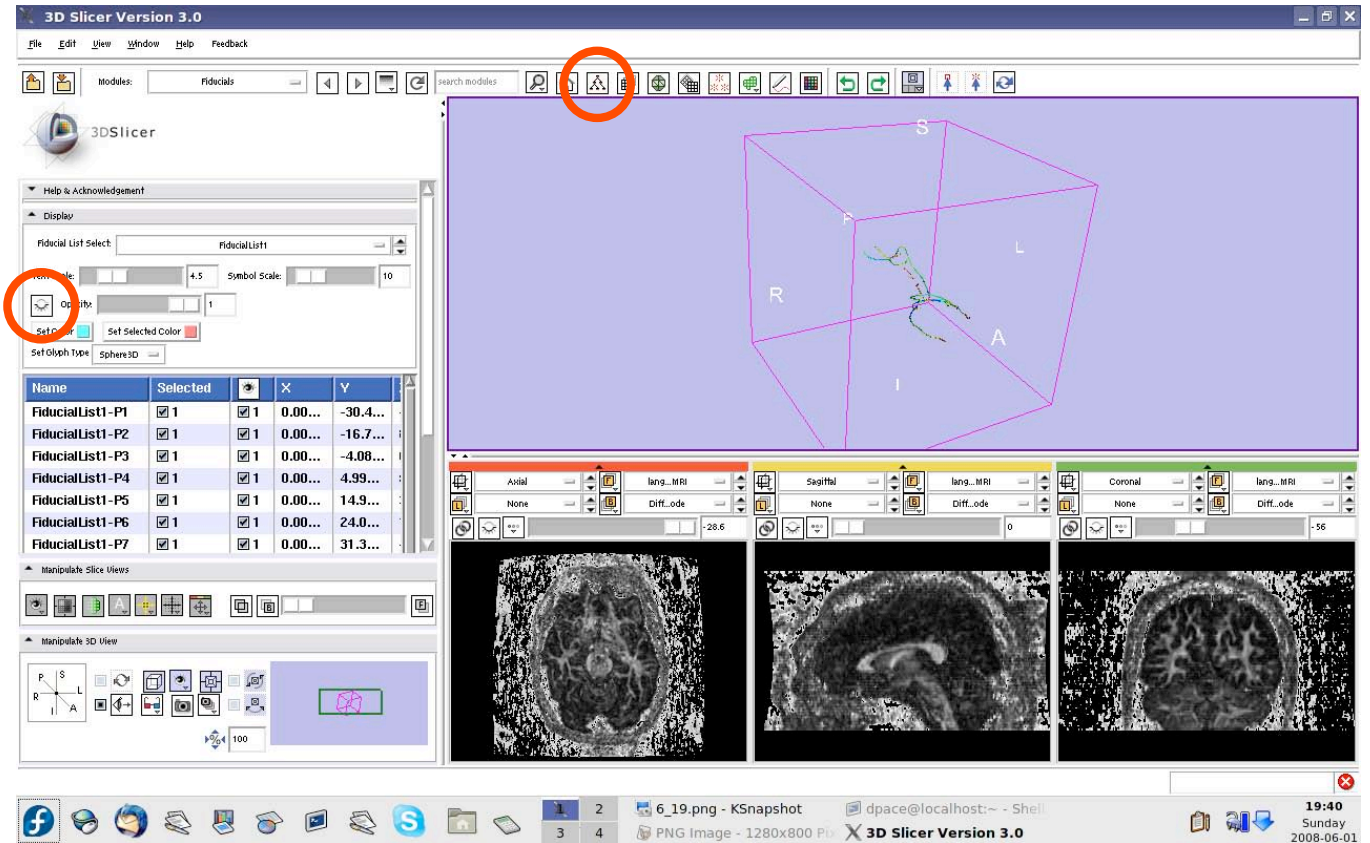




Perform tractography (fiber tracking)

Open the Fiducials module

Turn off the visibility of the fiducials

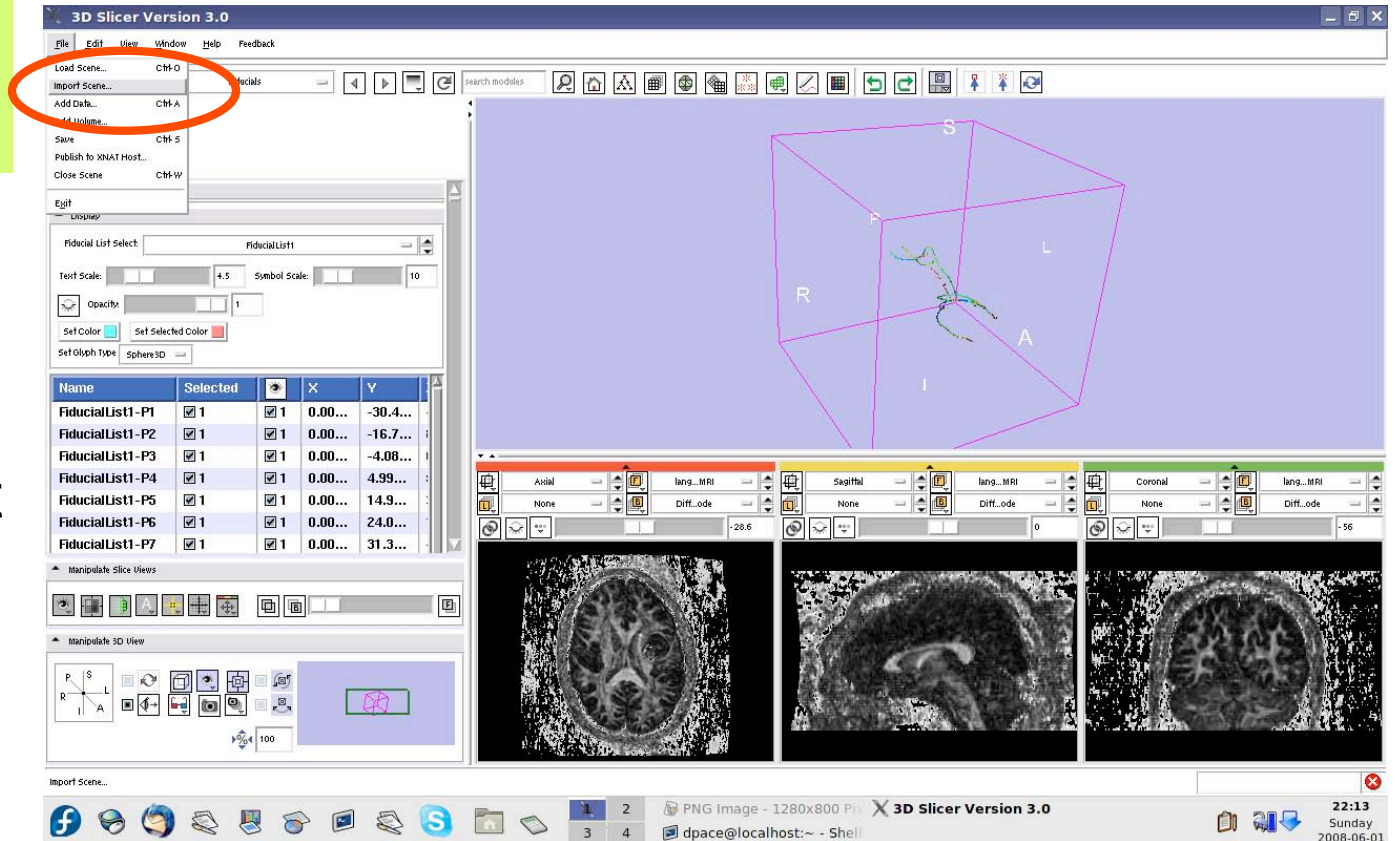




Import the anatomical-DTI registration transform

Select File -> Import Scene

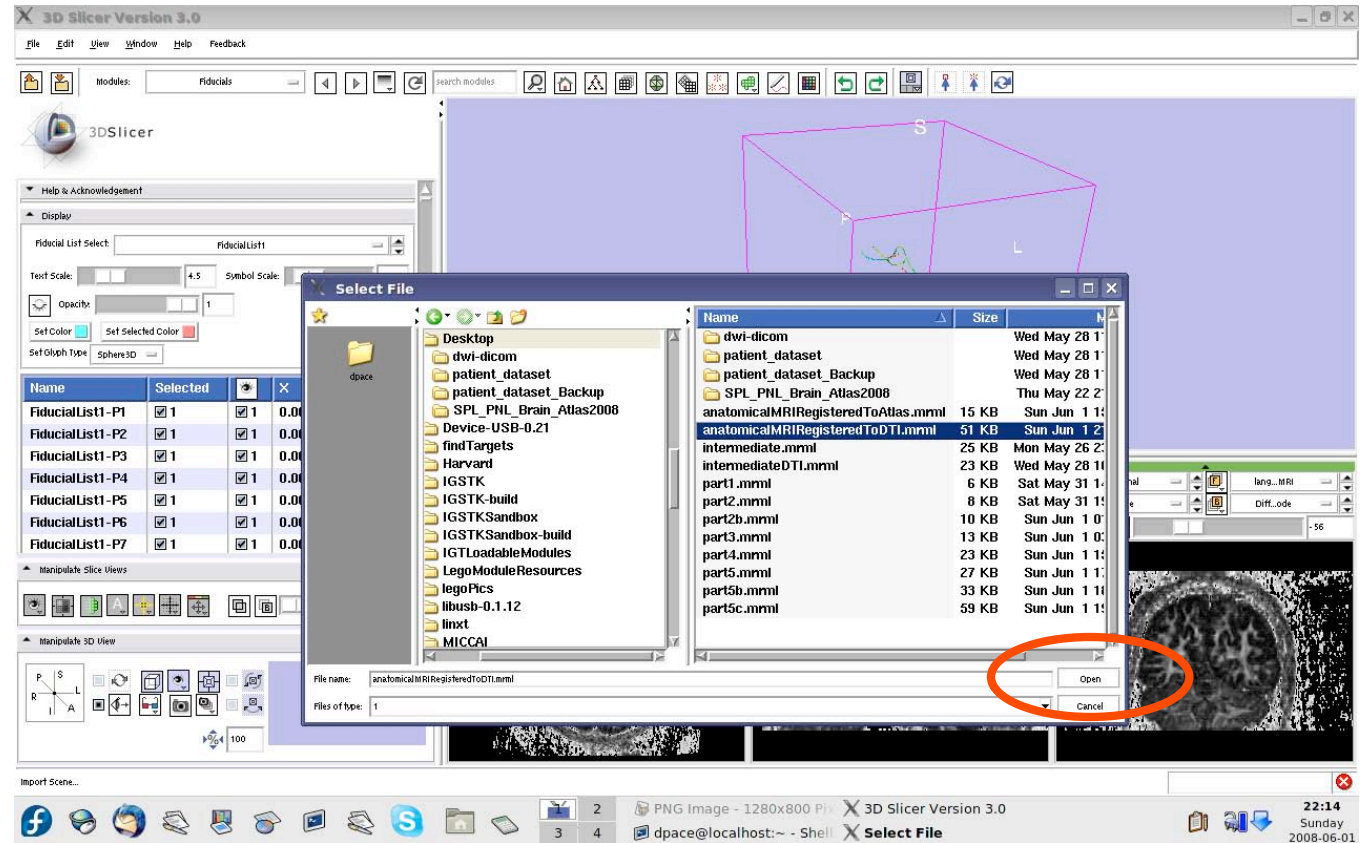
Note: Make sure that you select “Import Scene” and not “Load Scene”, as “Load Scene” will delete your work so far





Import the anatomical-DTI registration transform

Select
“anatomical
MRI
Registered
ToDTI.mrml”,
then click
“Open”



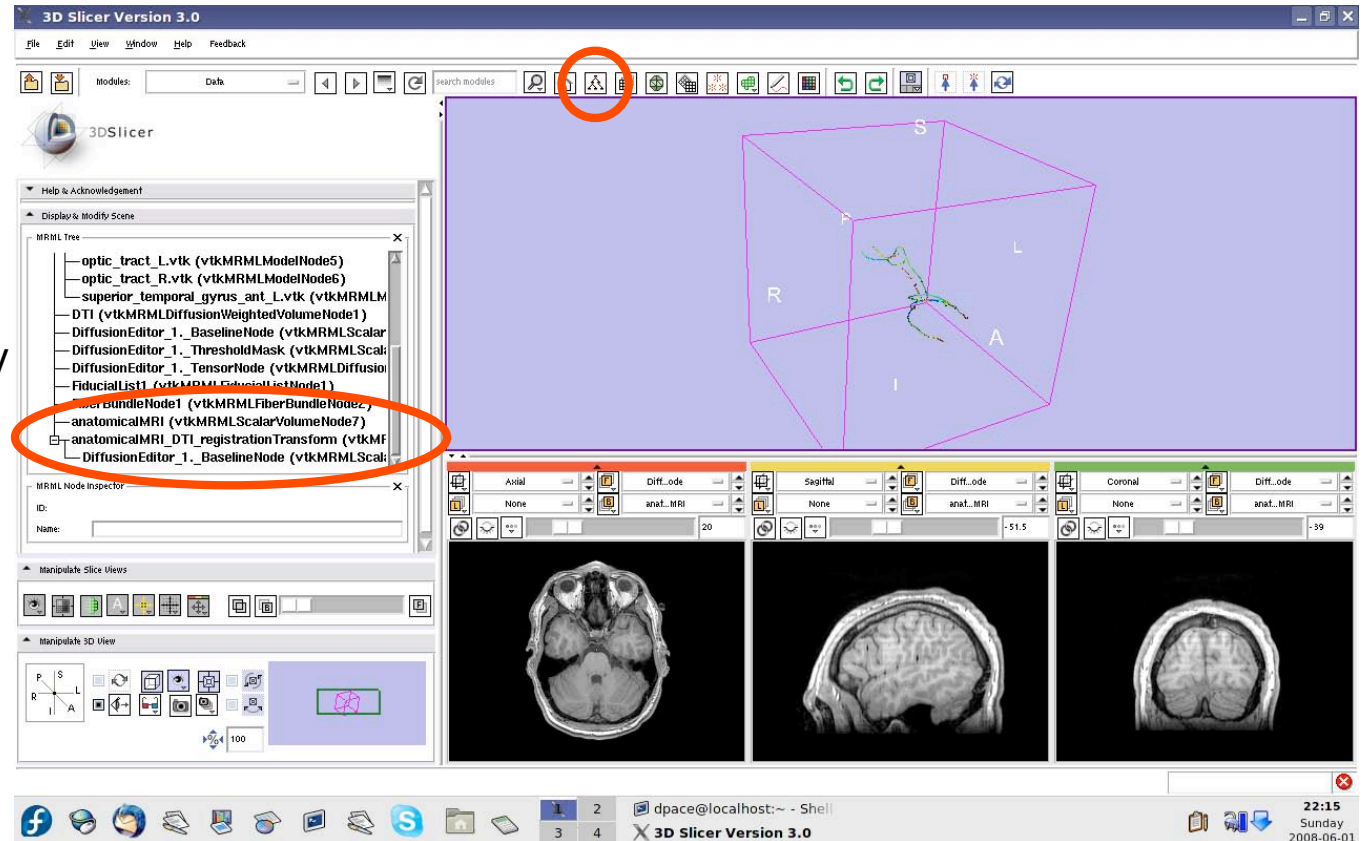


Inspect the MRML scene

Open the Data module

Inspect the atlas MRML scene

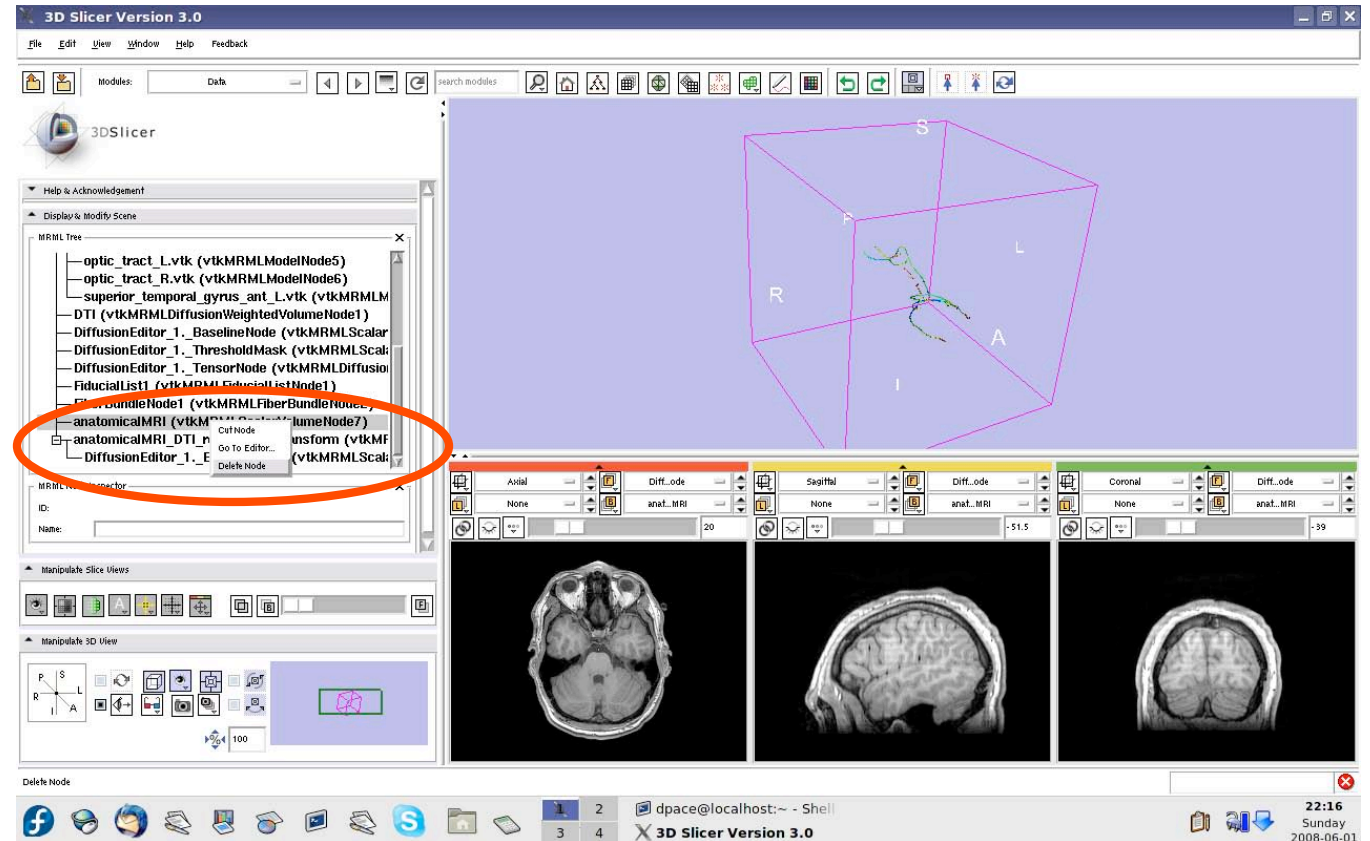
- anatomicalMRI = copy of the patient's anatomical MRI
- BaselineNode = copy of the patient's DTI baseline node
- anatomicalMRI_DTI_registrationTransform = aligns the DTI images with the anatomical image





Inspect the MRML scene

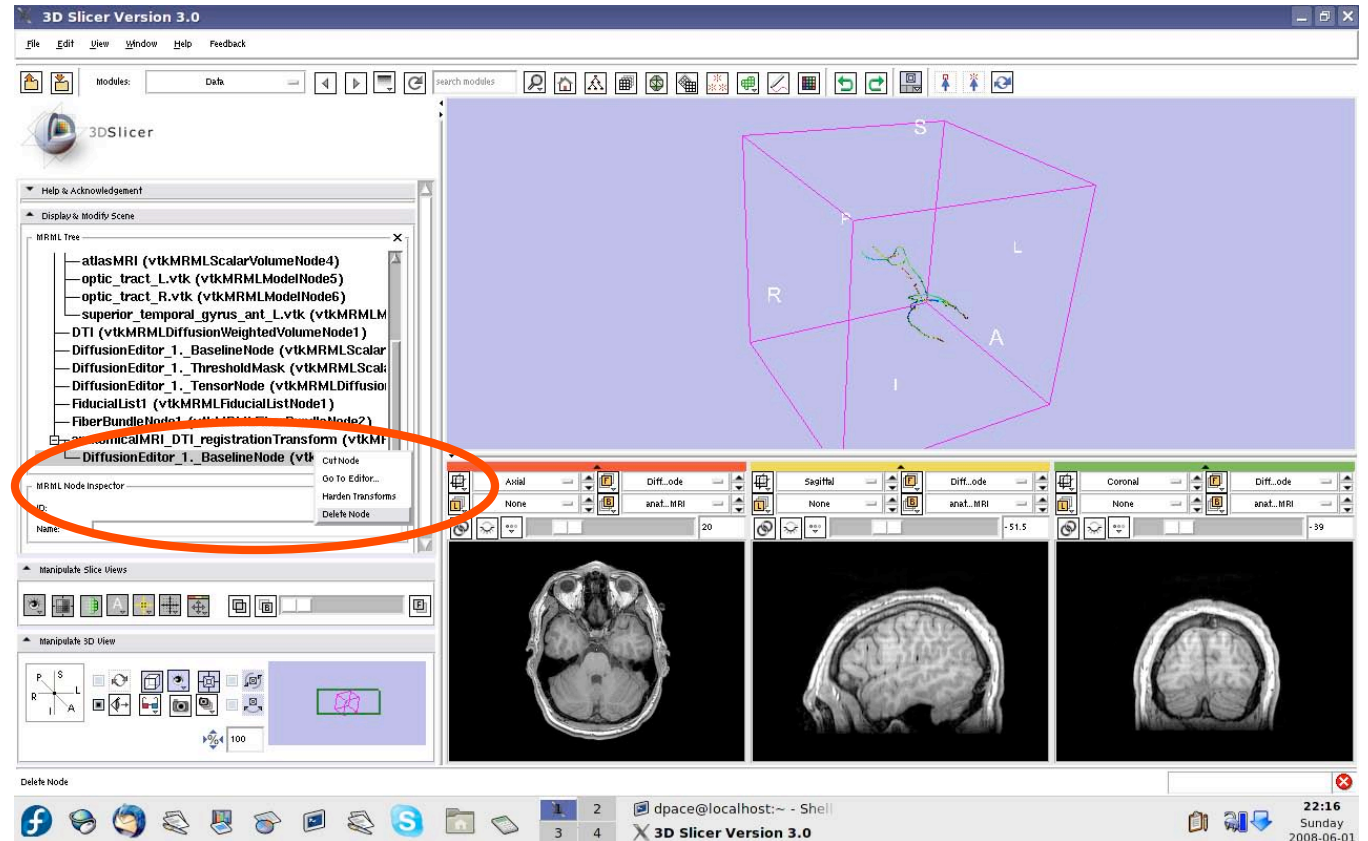
Delete the duplicate anatomicalMRI node by right-clicking and selecting “Delete Node”





Inspect the MRML scene

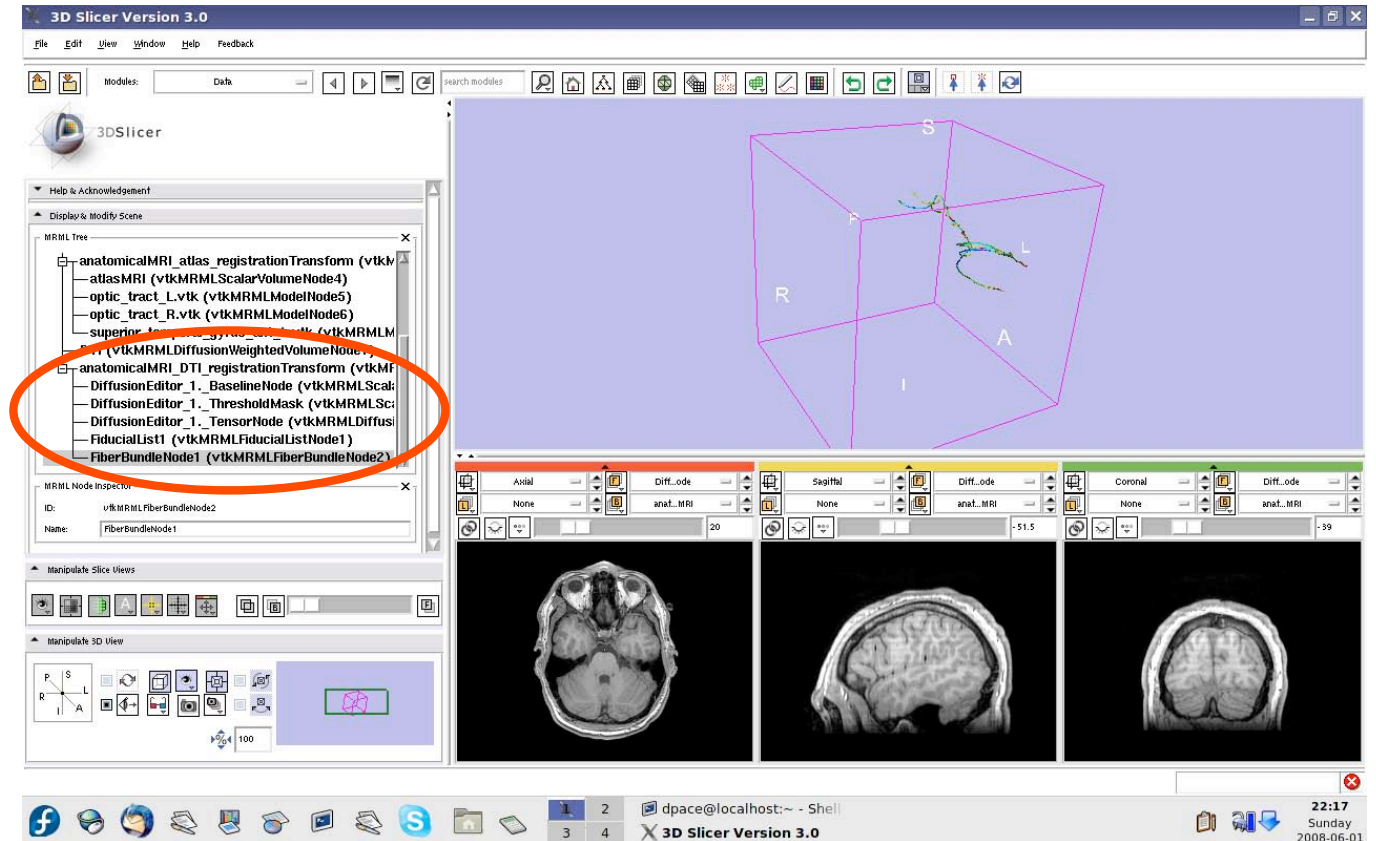
Delete the duplicate BaselineNode node by right-clicking and selecting “Delete Node”





Inspect the MRML scene

Drag the three diffusion editor nodes, the fiducial list and the fiber bundle node under the anatomicalMRI_DTI_registrationTransform

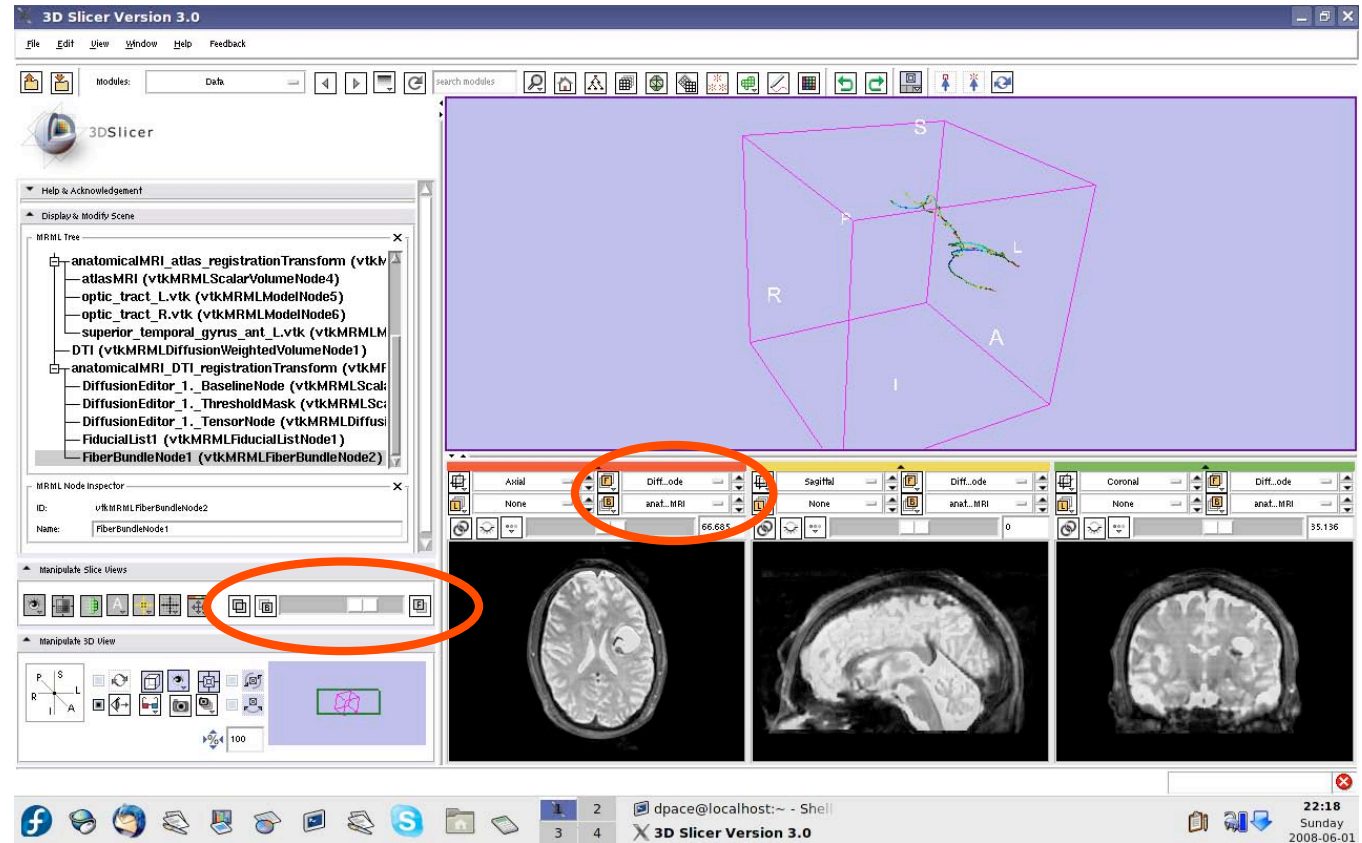




Inspect the anatomical MRI-DTI registration

Set the foreground to the baseline node and the background to anatomicalMRI

Scale the opacities to see how well the atlas MRI and patient anatomical MRI image volumes are aligned

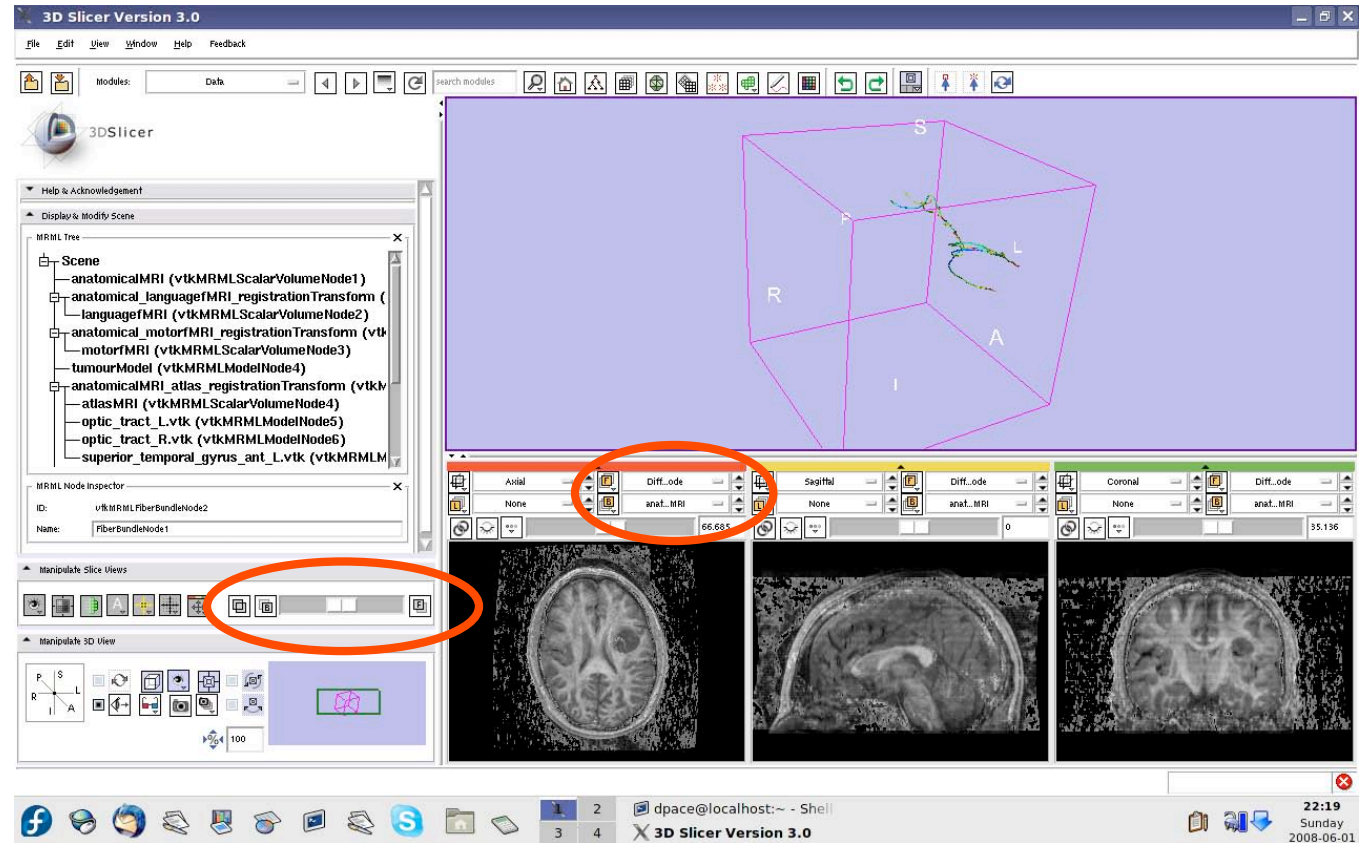




Inspect the anatomical MRI-DTI registration

Set the foreground to the tensor node and the background to anatomicalMRI

Scale the opacities to see how well the atlas MRI and patient anatomical MRI image volumes are aligned





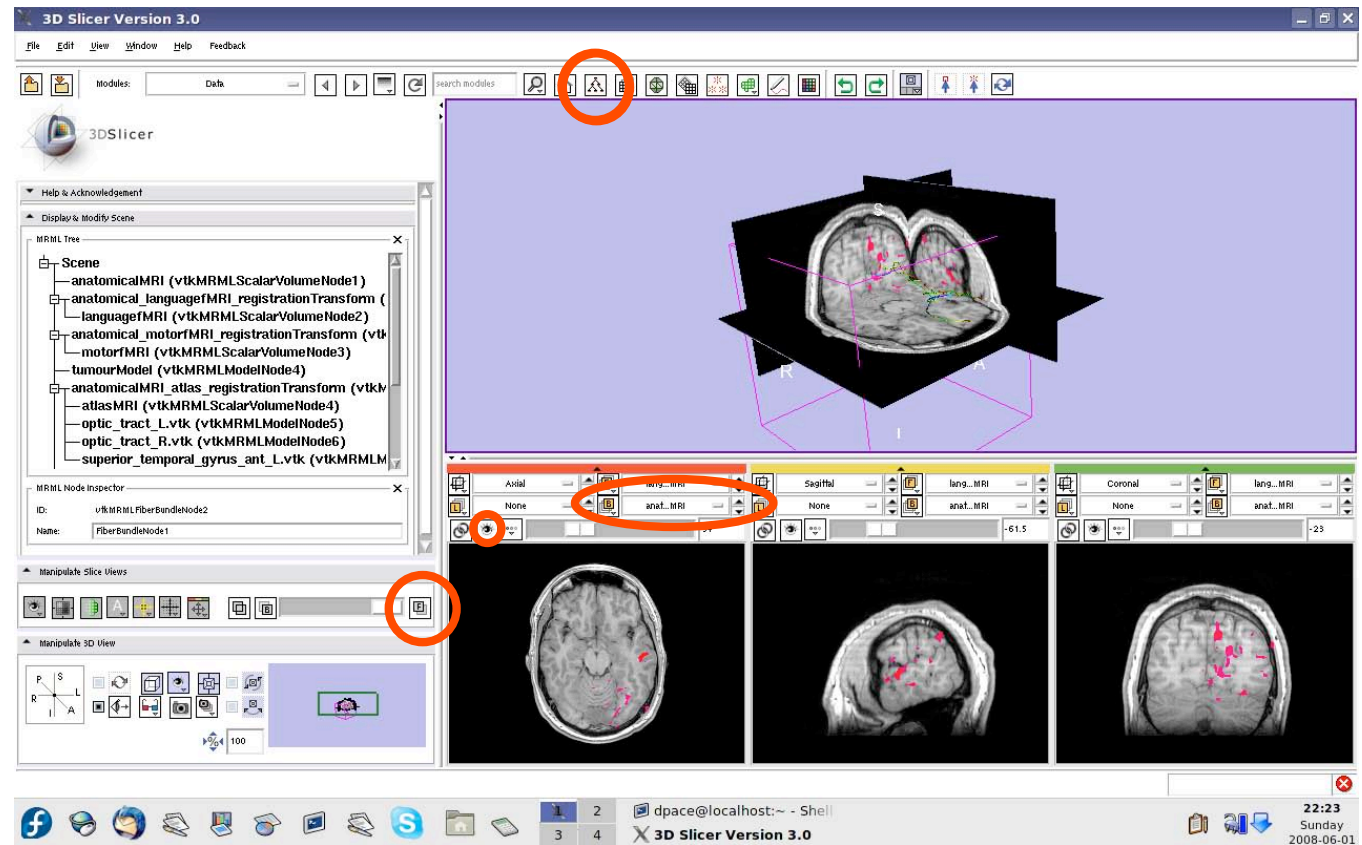
Inspect the entire scene so far

Open the Data module

Set the foreground to languagefMRI

Click on the “visibility” button

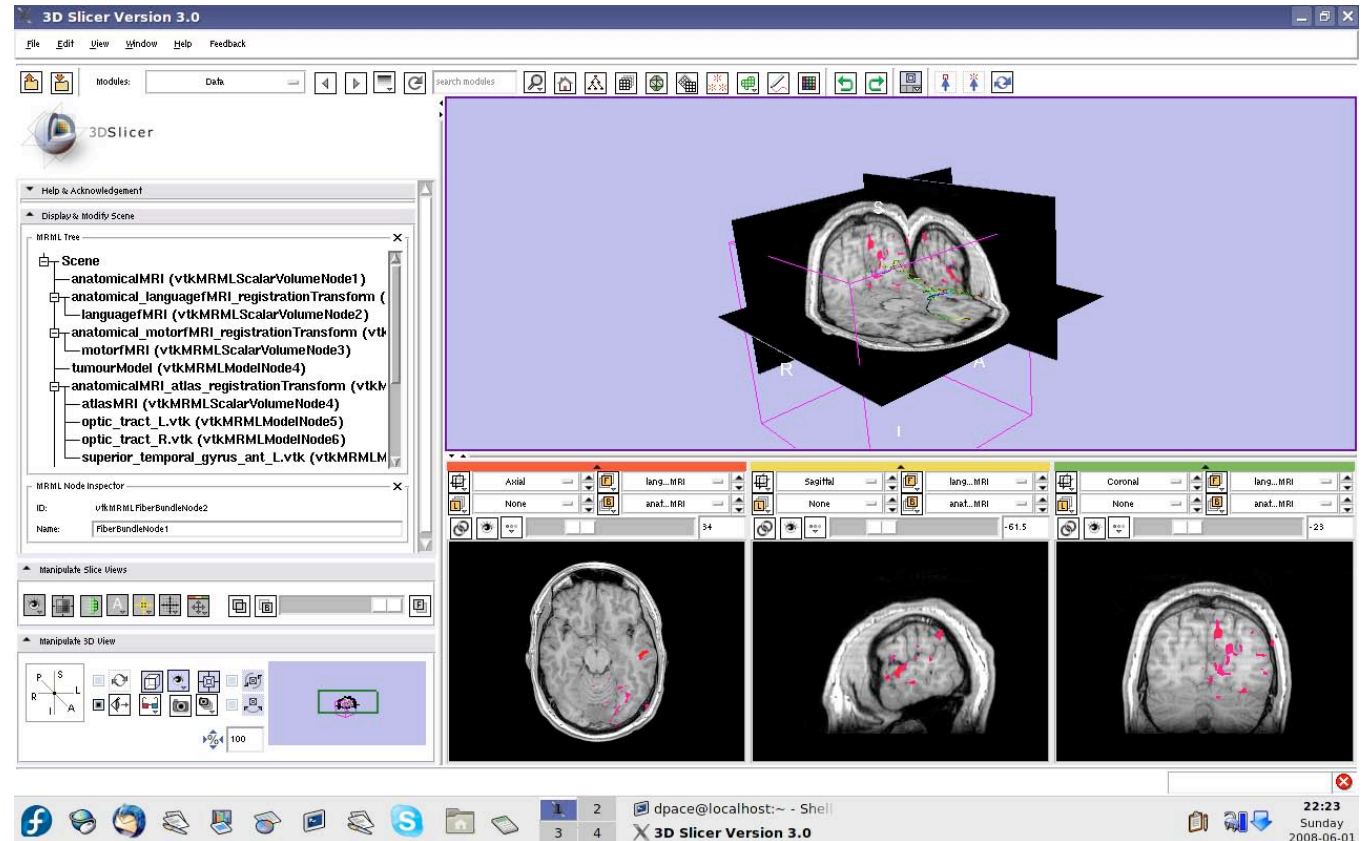
Click on the Foreground layer button to show the language fMRI data





Inspect the entire scene so far

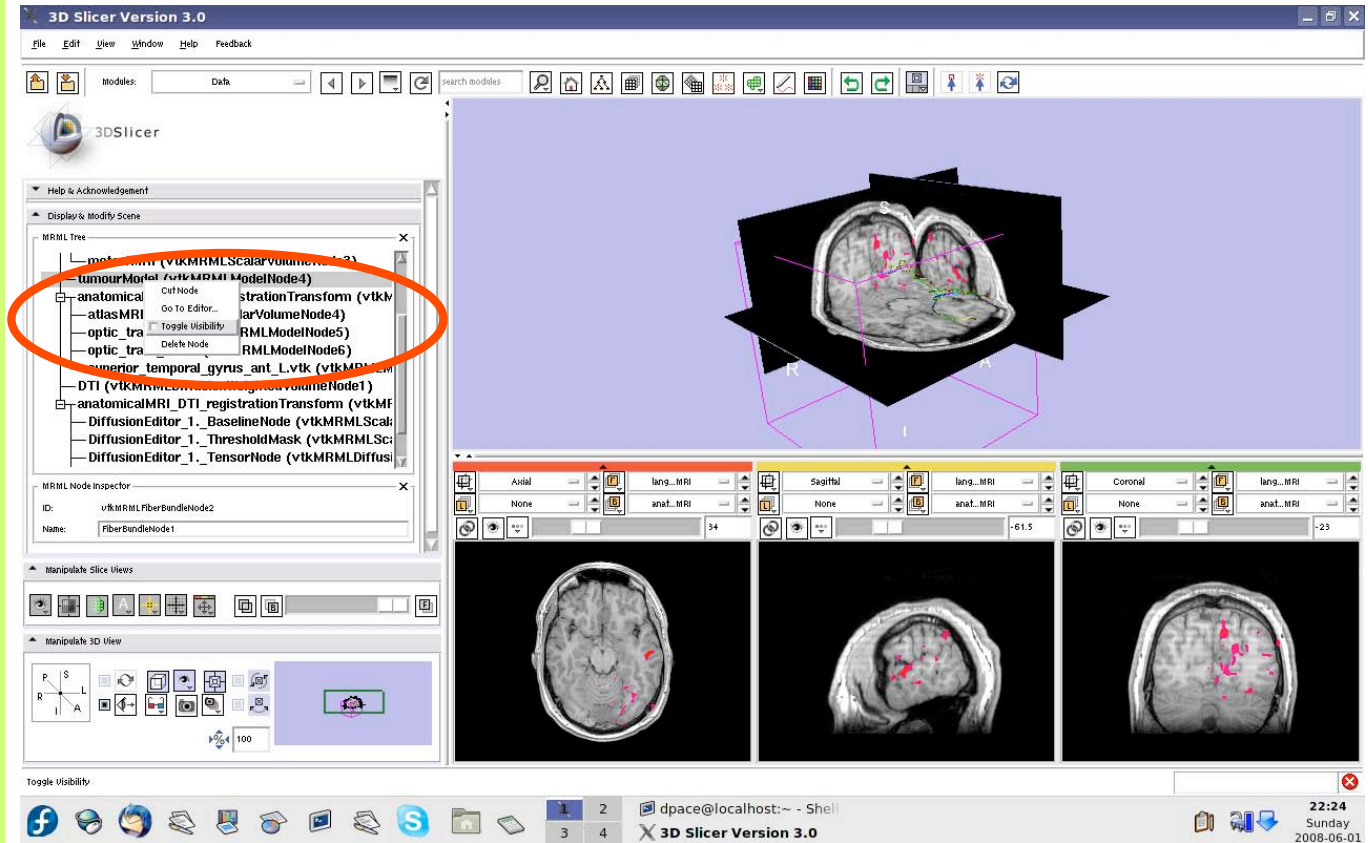
Slice through the image volume to get a good view





Inspect the entire scene so far

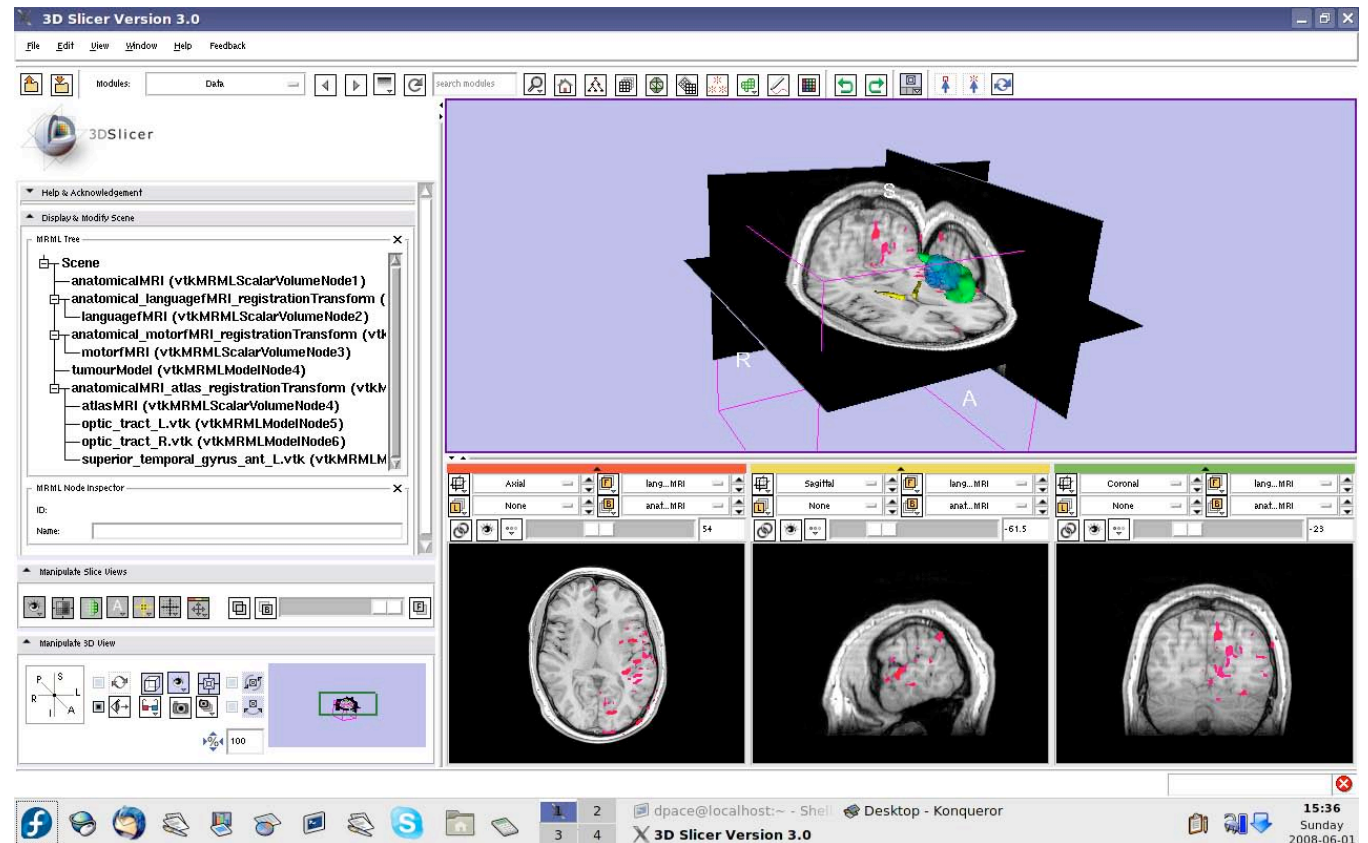
Turn the visibility on for the four models in the scene (tumour, left and right optic tracts, and left anterior superior temporal gyrus) by right-clicking and selecting “Toggle Visibility”





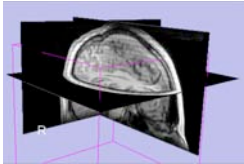
Inspect the entire scene so far

The scene now contains anatomical MRI data, functional MRI data, a segmented tumour volume, estimates of other brain structures and brain fiber tractography

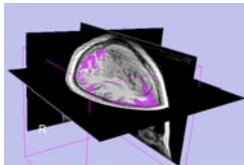




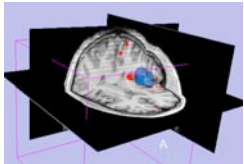
Overview



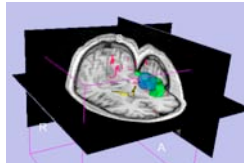
1. Loading and visualizing anatomical MRI data



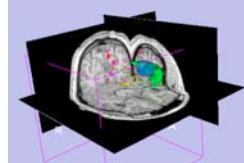
2. Incorporating fMRI data using image registration and thresholding



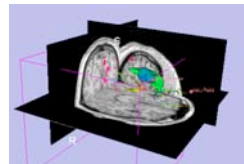
3. Creating a 3D model of the tumour volume



4. Predicting the locations of brain structures using image registration and a brain atlas



5. Incorporating brain fiber tractography from diffusion weighted images

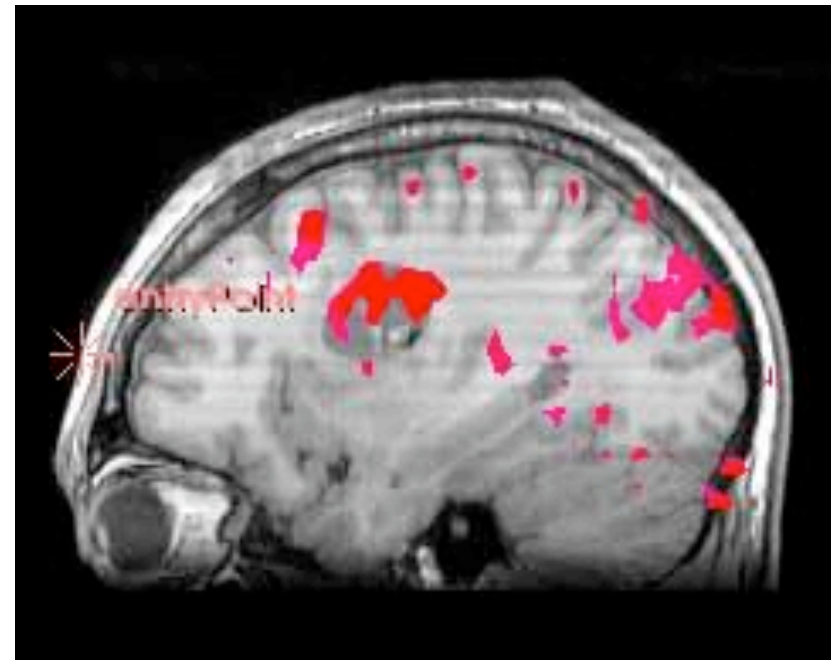


6. Annotating the preoperative plan and saving the scene



Plan annotation

- **Utility of plan annotation in IGT:**
 - Surgeons can mark important points on the plan, such as the planned surgical access point, so that their notes can be brought into the operating room





Plan annotation

- **Steps involved in this section:**

Mark the entry point and the tumour access point on the plan

Measure the distance between the two points

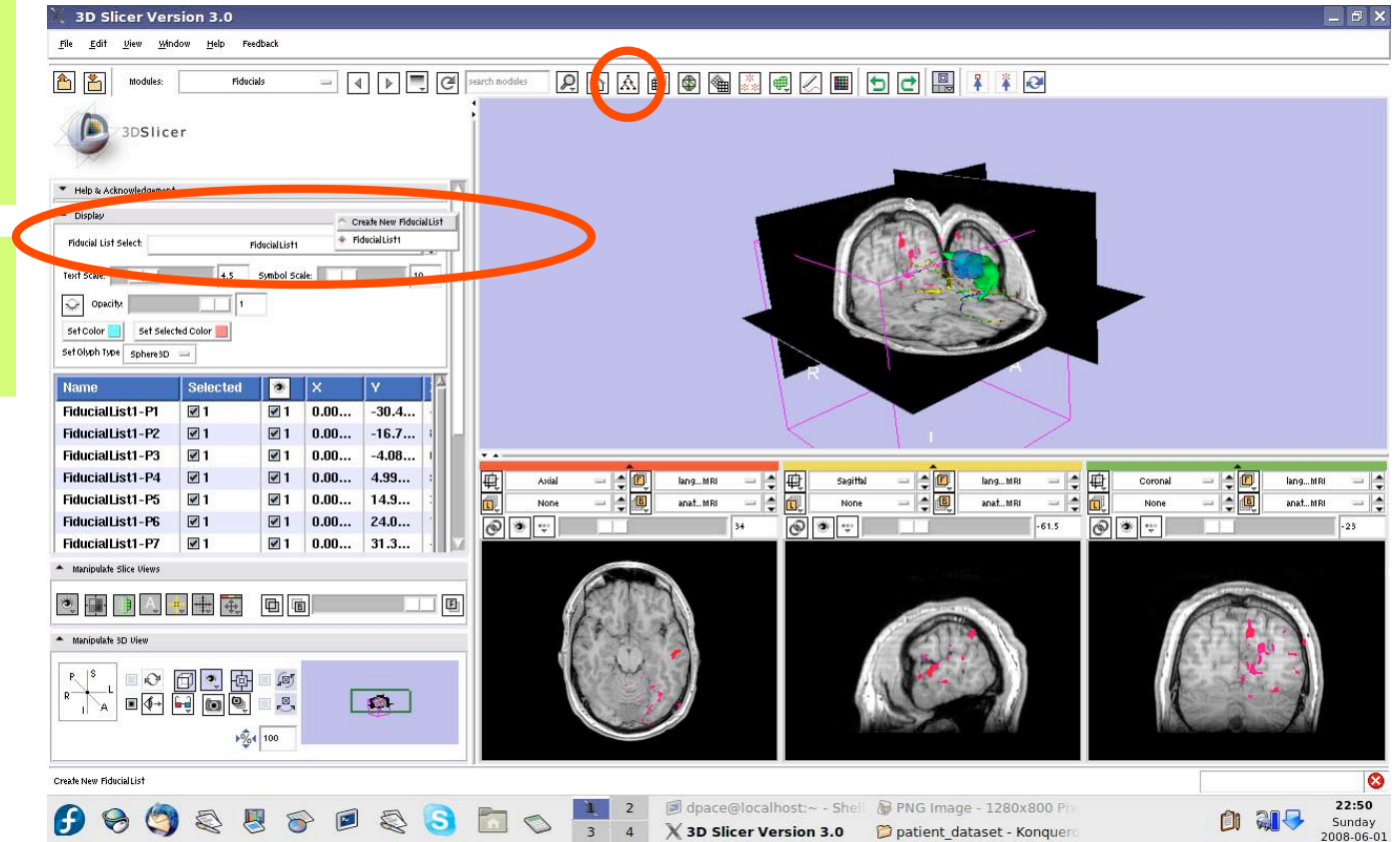
Save the scene



Annotate the plan

Open the Fiducials module

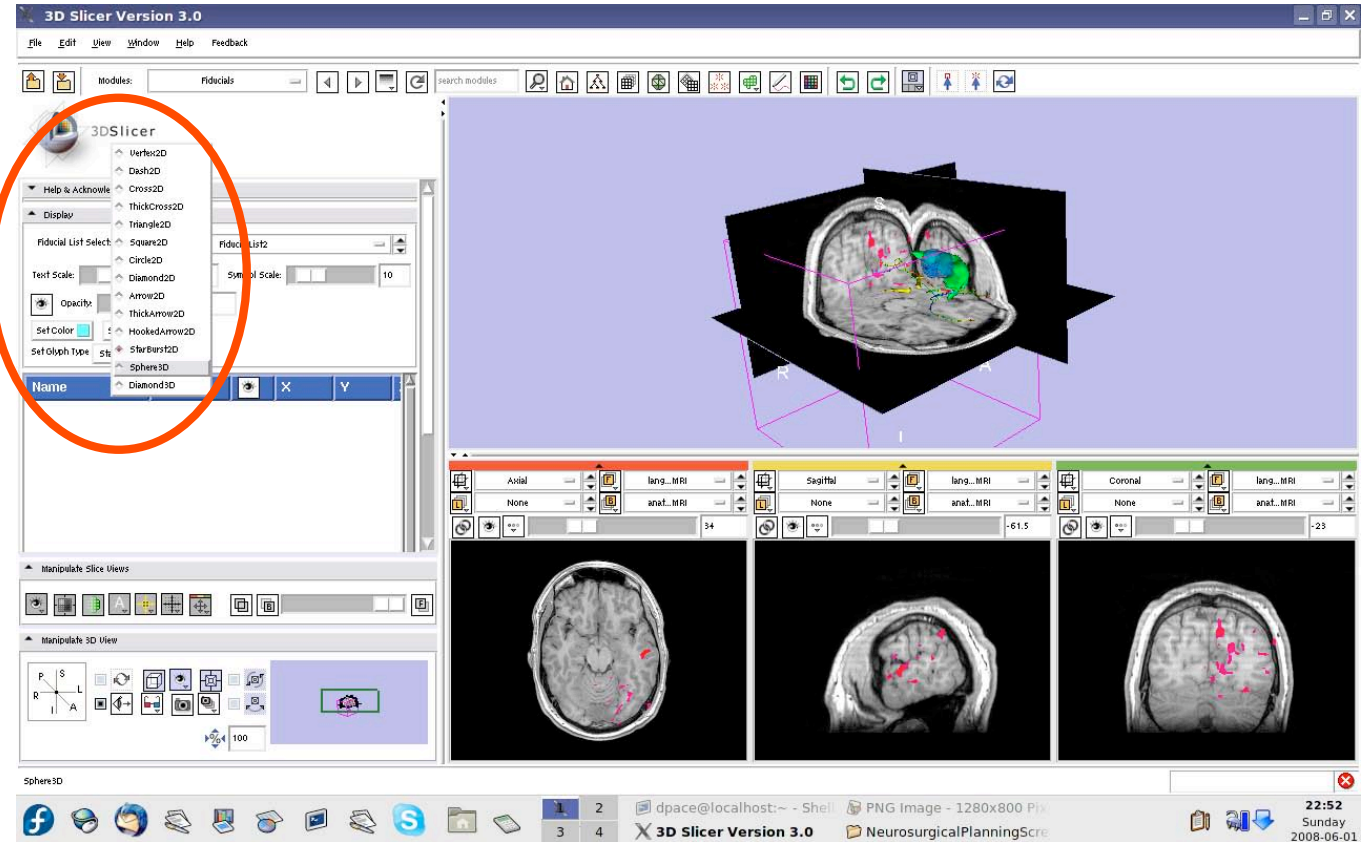
Create a new Fiducial List





Annotate the plan

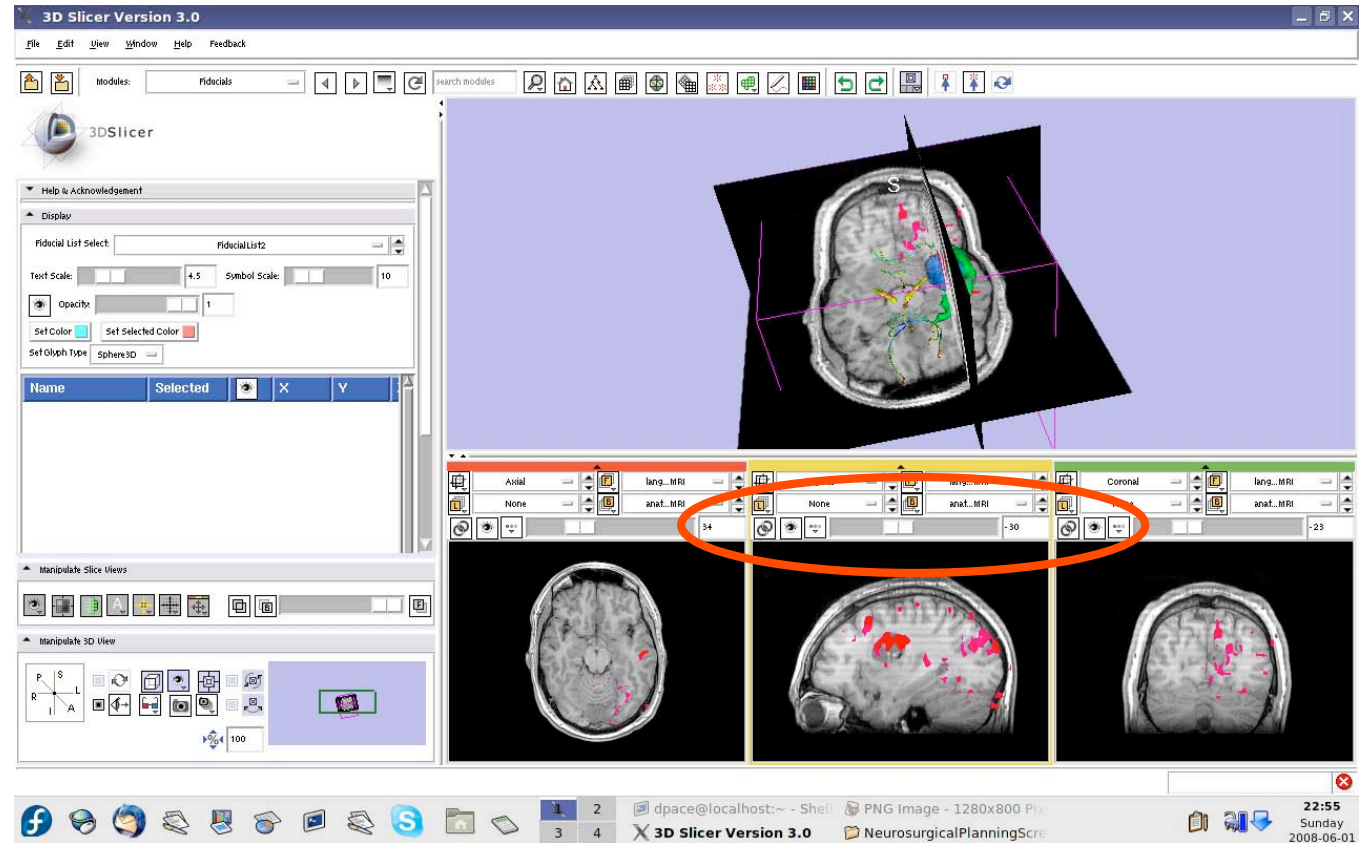
Set the glyph
type to
Sphere3D





Annotate the plan

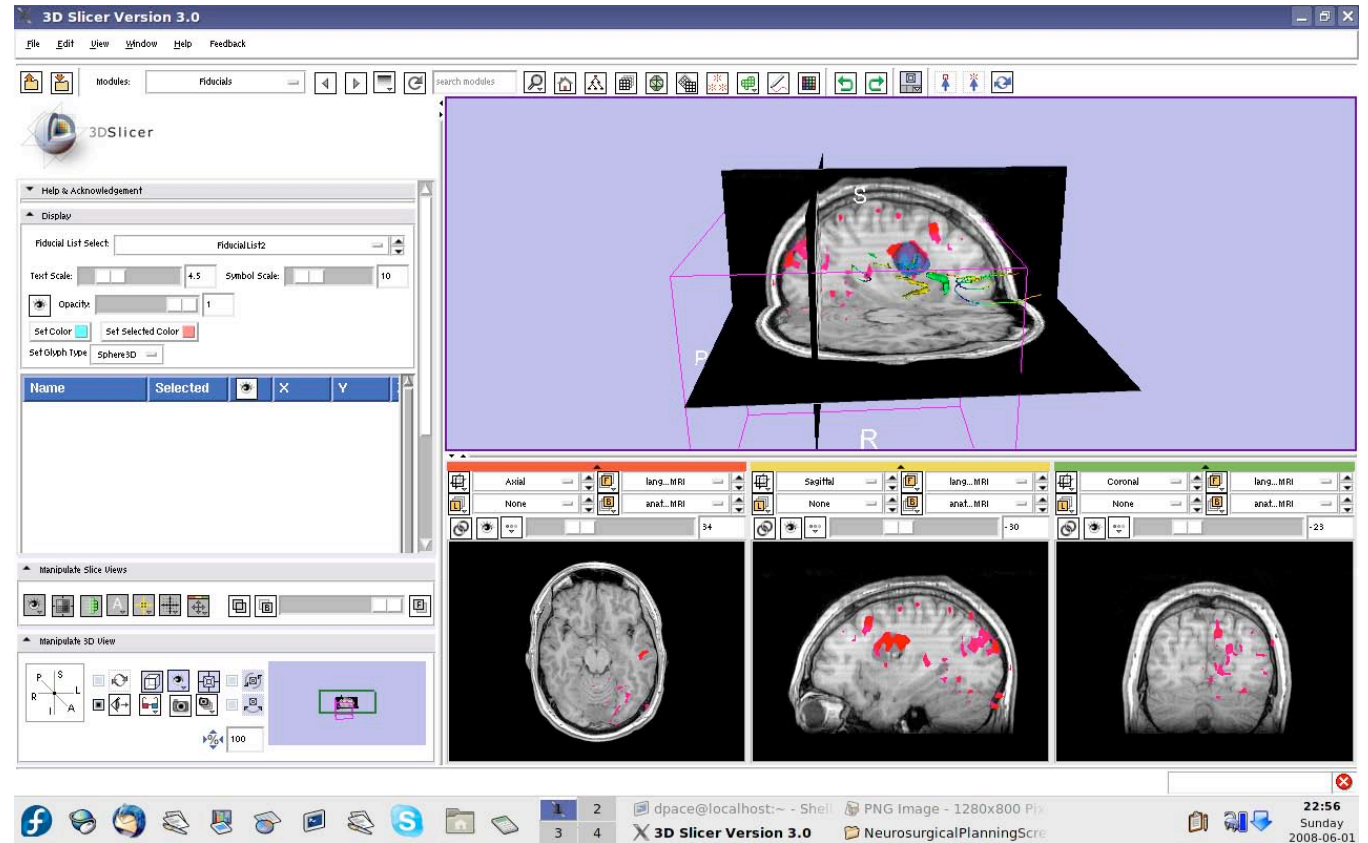
Slice through the sagittal plane until it roughly bisects the tumour volume





Annotate the plan

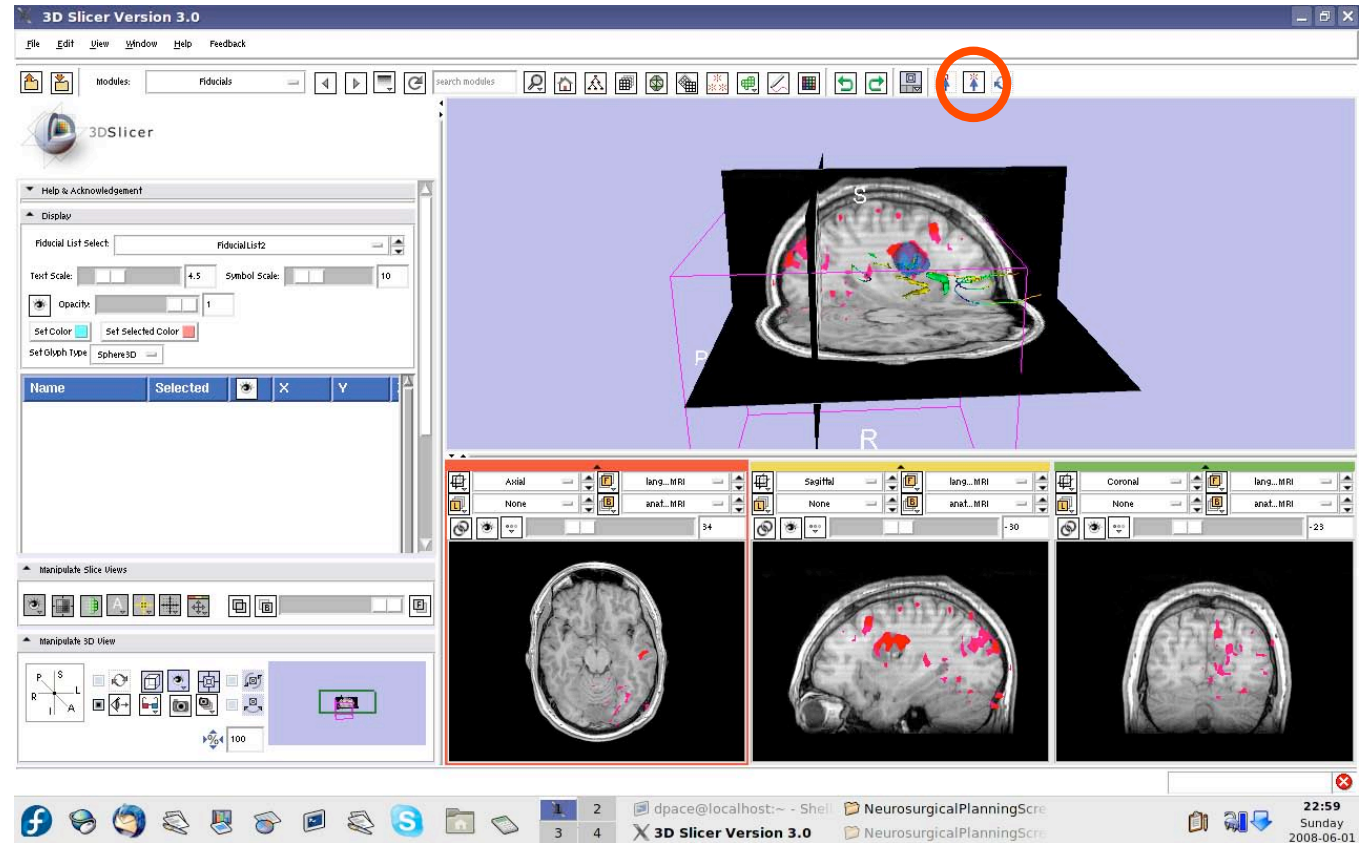Adjust the 3D Viewer to get a view from the right





Annotate the plan

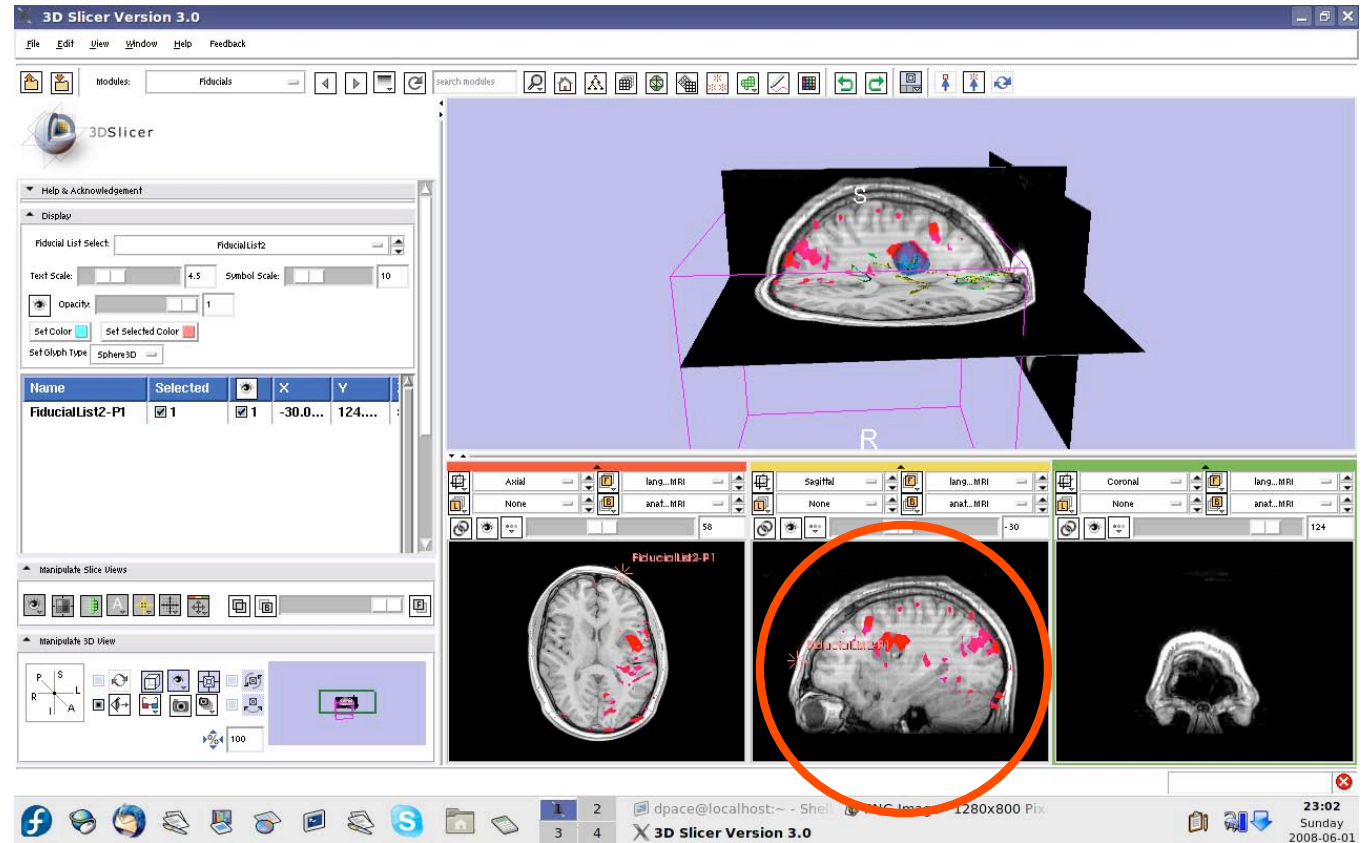
Set the mouse mode to “place items”





Annotate the plan

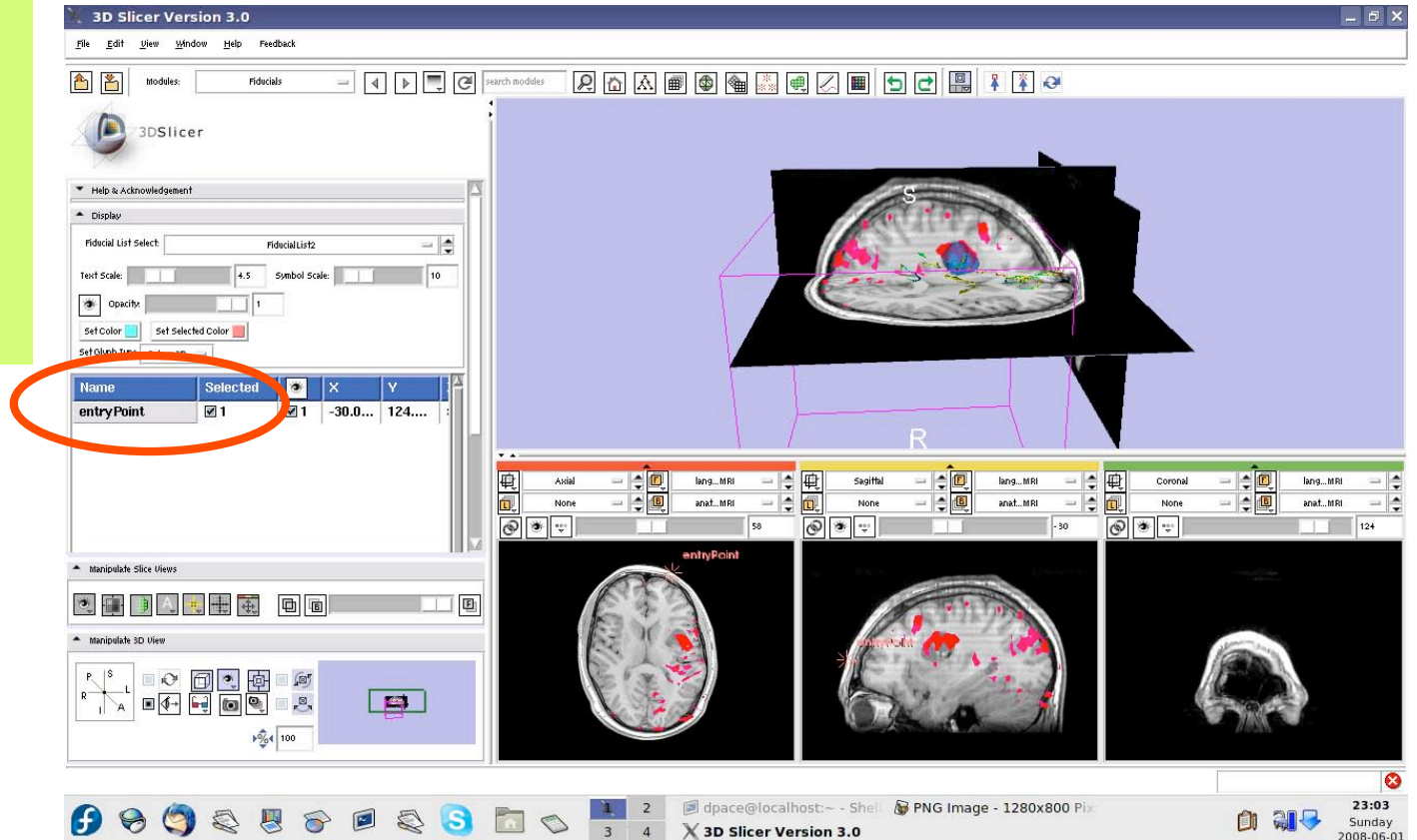
Place a fiducial on the sagittal plane representing the planned entry point for the left frontal craniotomy





Annotate the plan

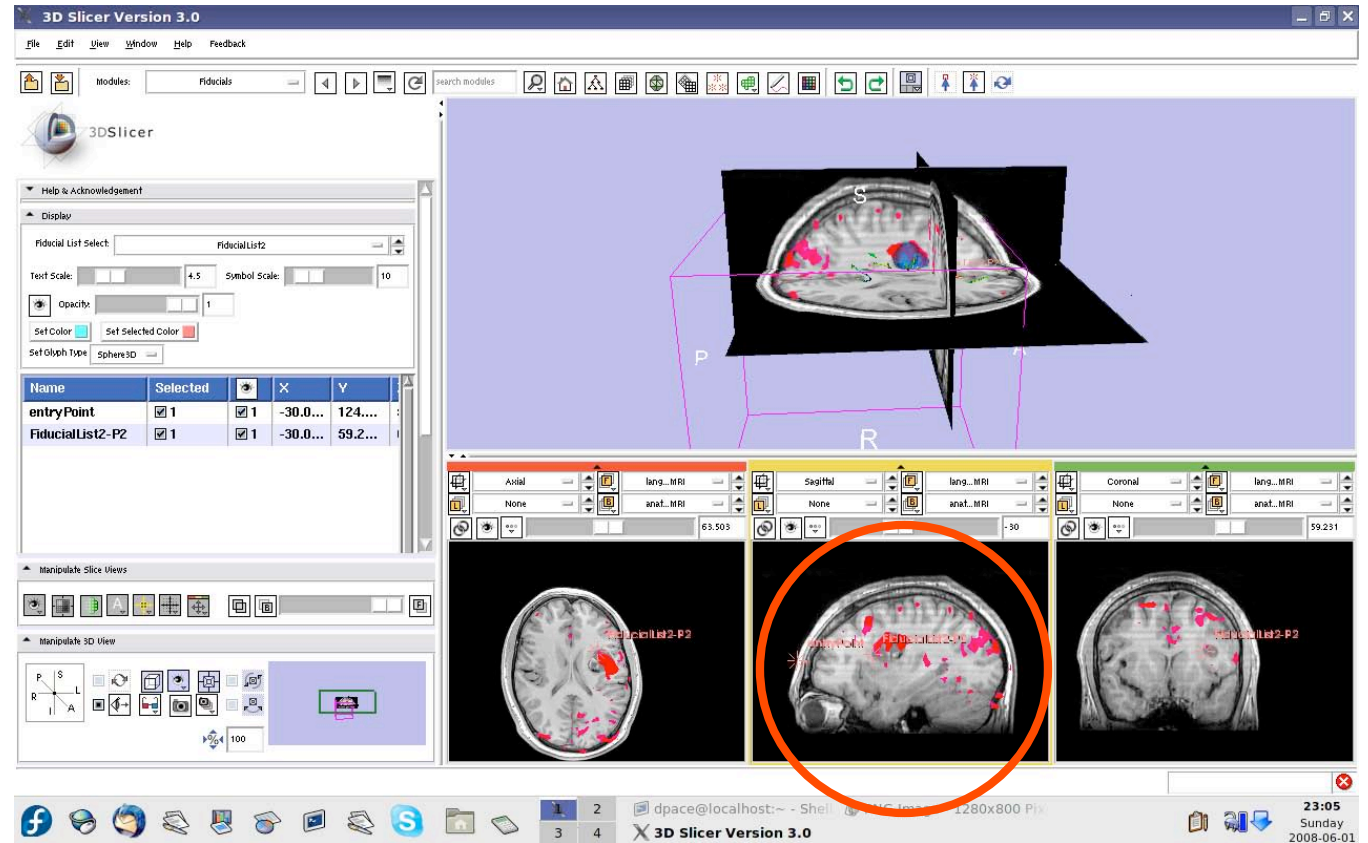
Double-click on the name of the fiducial and change it to "entryPoint"





Annotate the plan

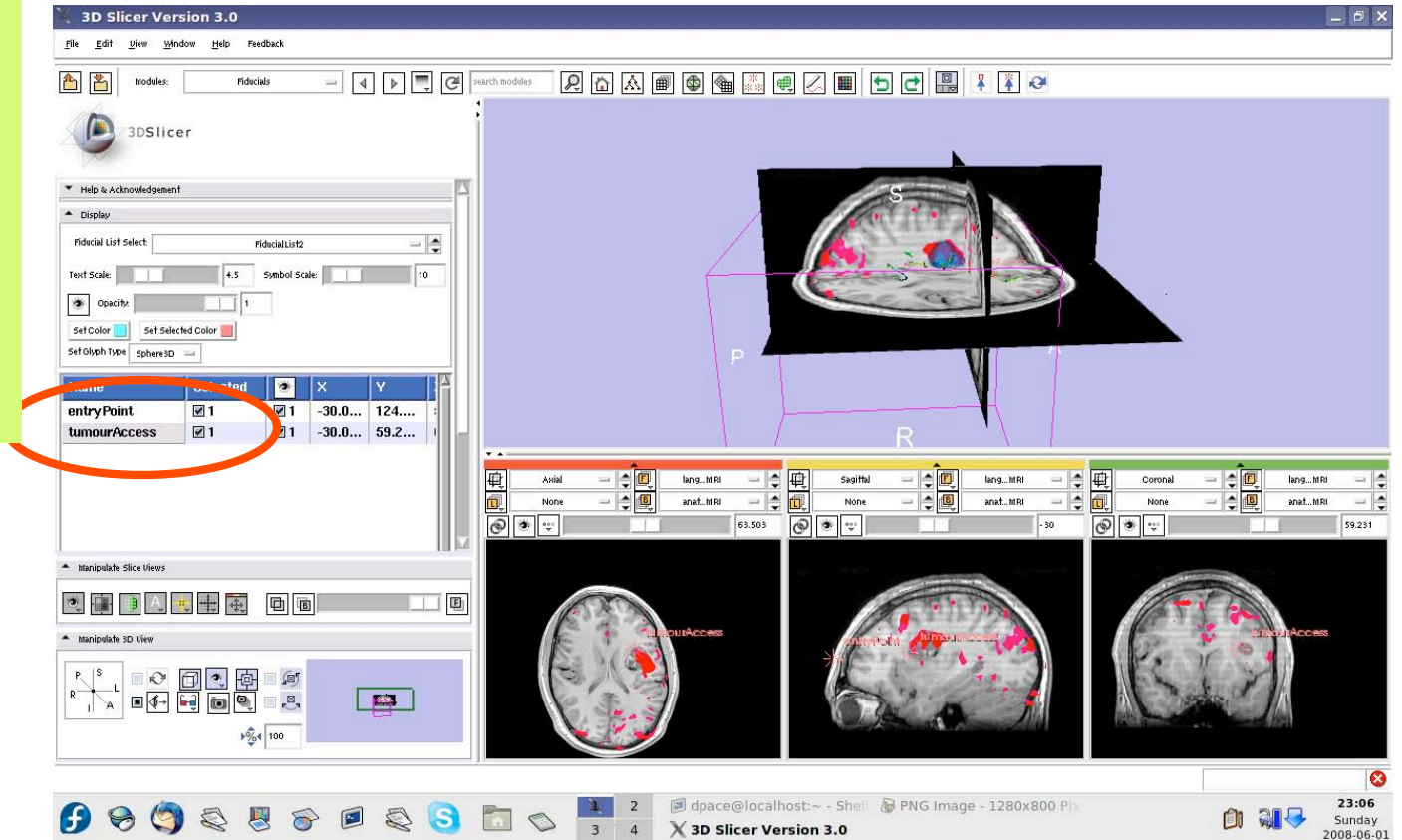
Place a fiducial on the sagittal plane representing the planned access point to the tumour





Annotate the plan

Double-click on the name of the fiducial and change it to “tumour Access”

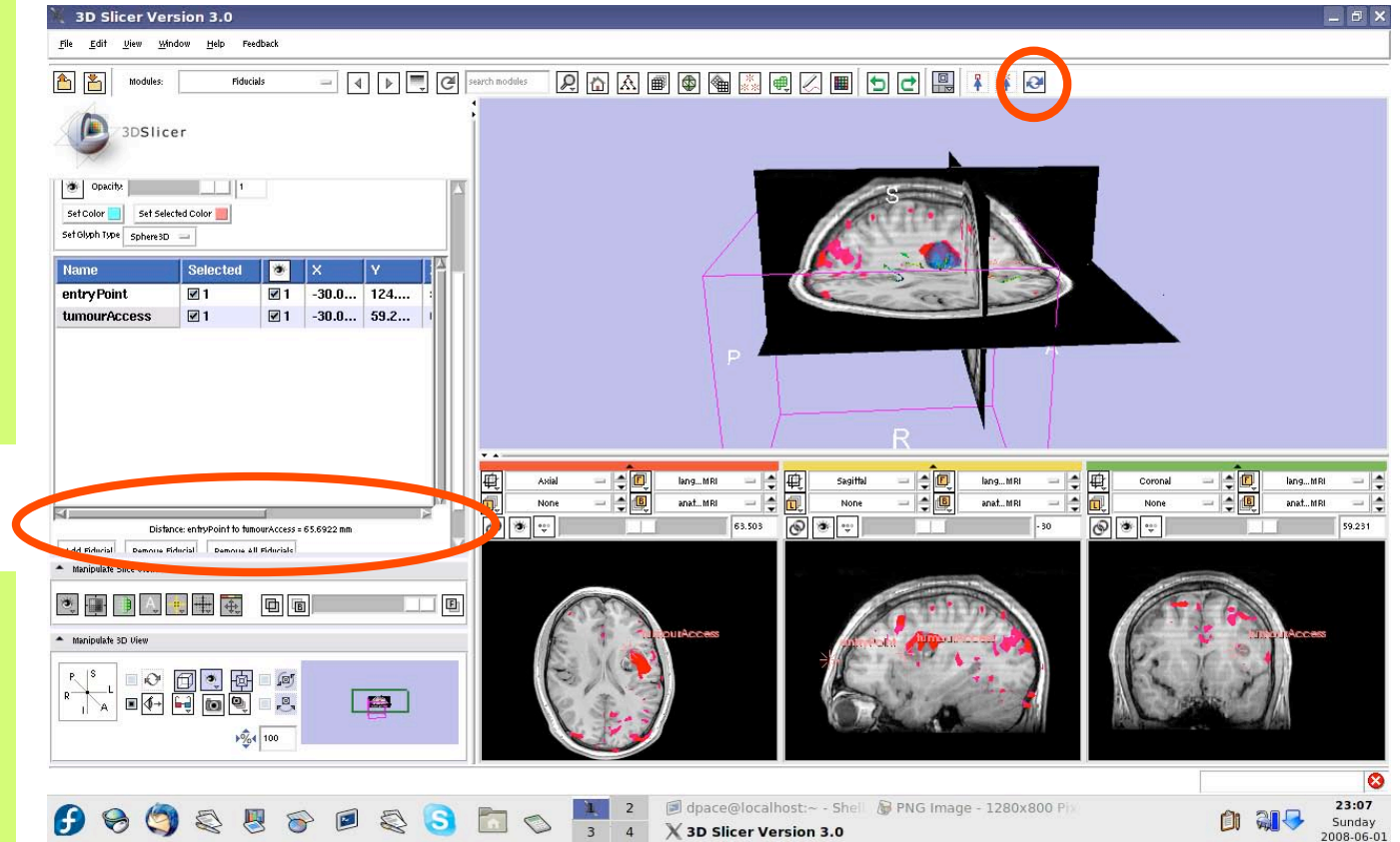




Distance measurements

Scroll down, and note that the distance between the two fiducials is shown

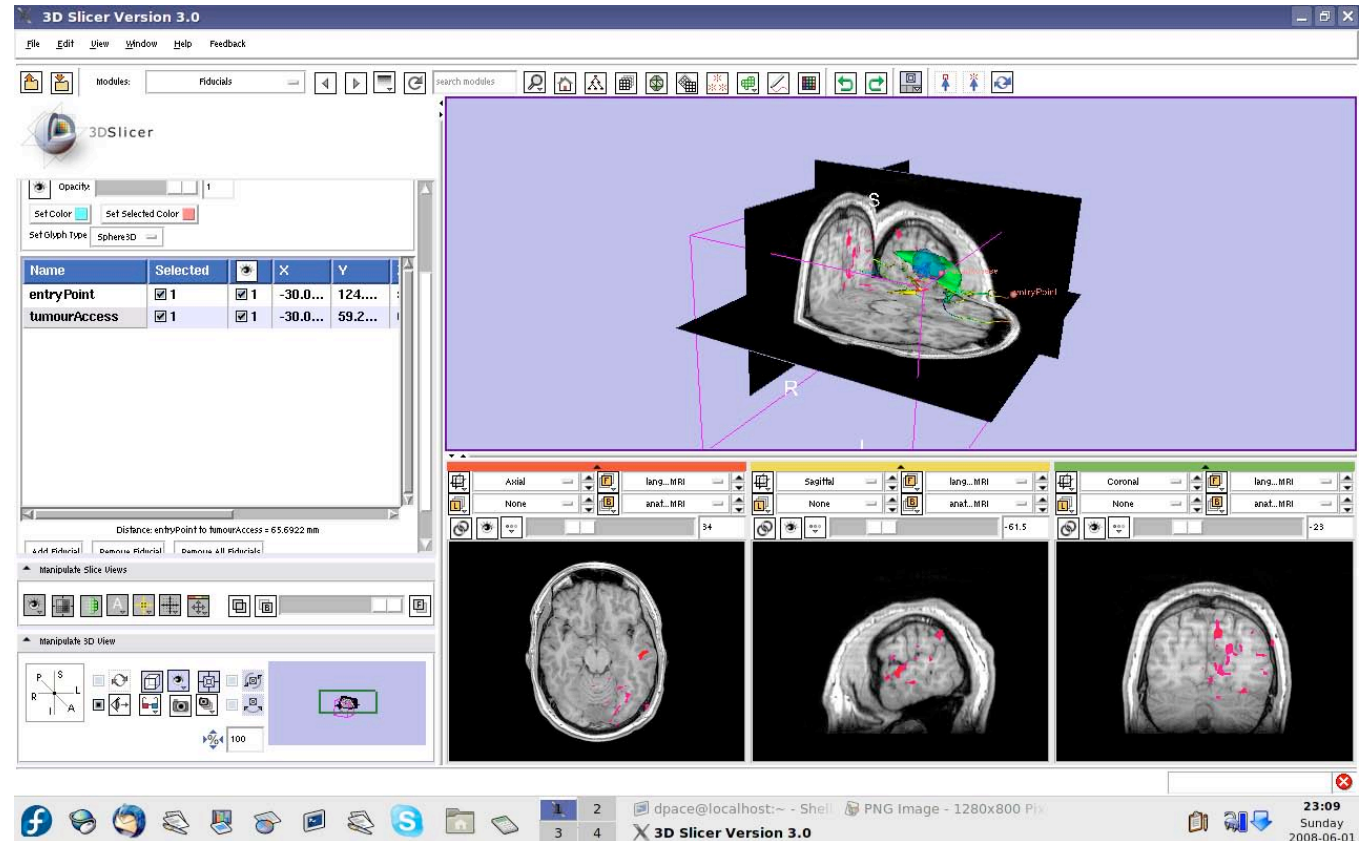
Change the mouse mode to “transform view”





Inspect the final scene

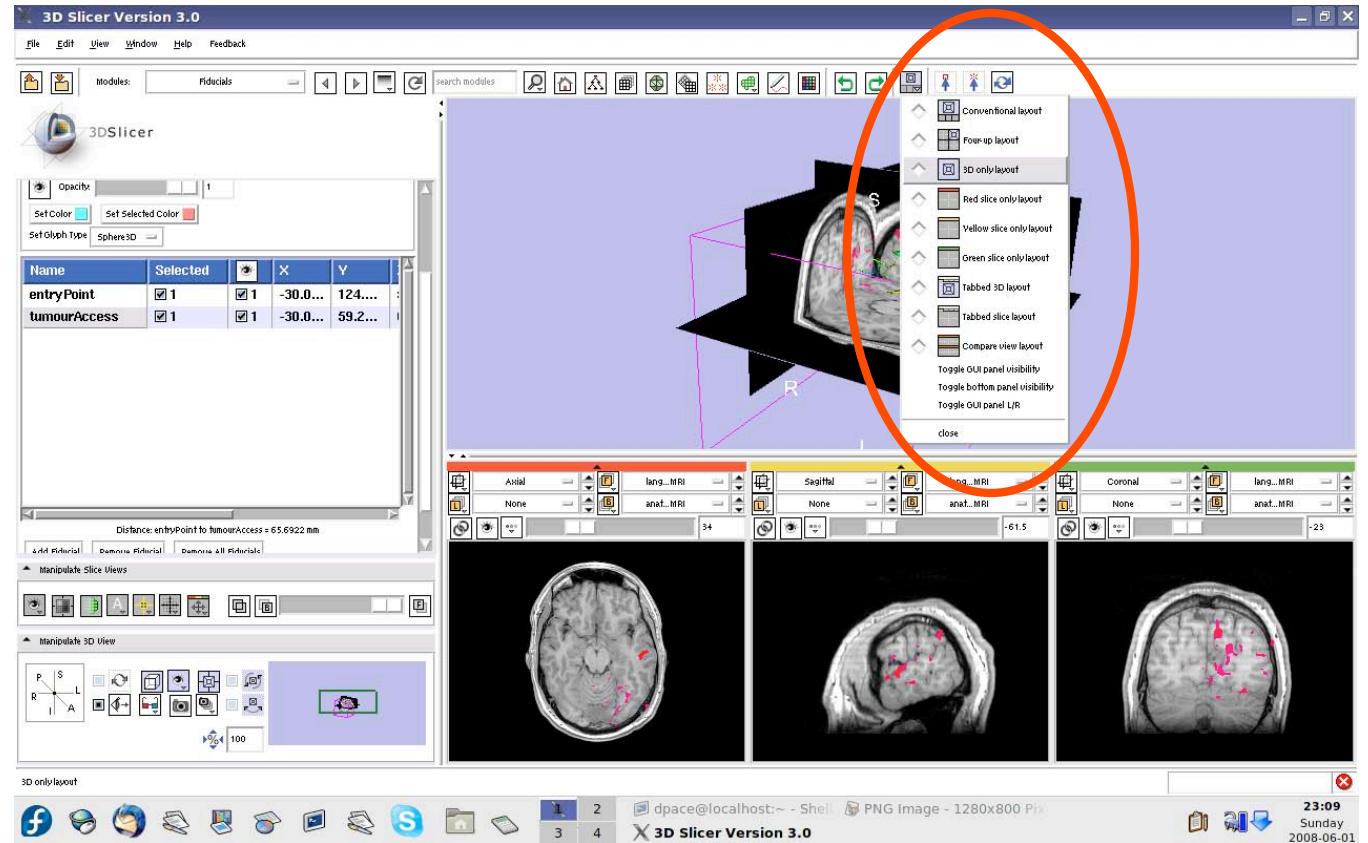
Slice through the image volume to get a good view





Inspect the final scene

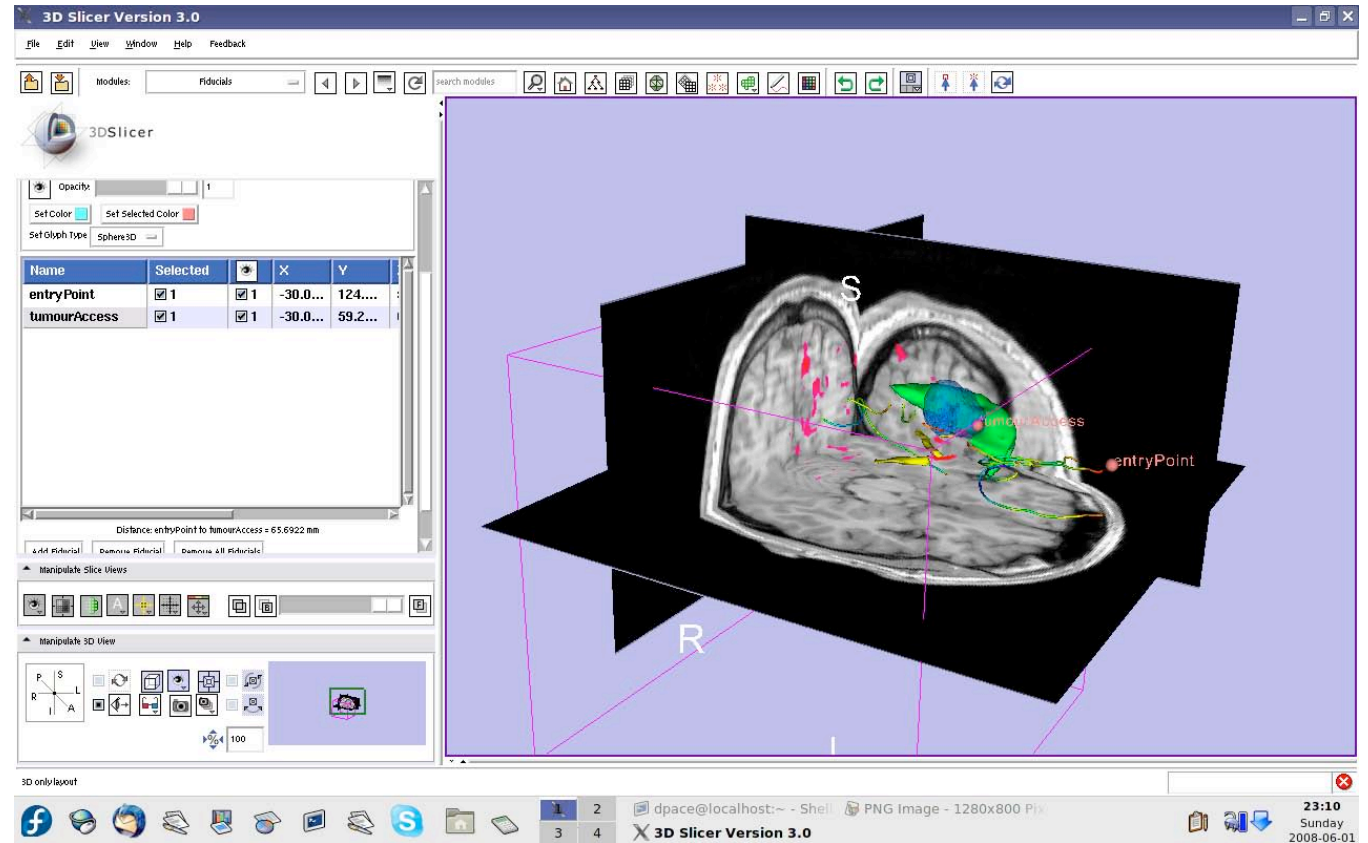
Set the layout to the “3D only layout”





Inspect the final scene

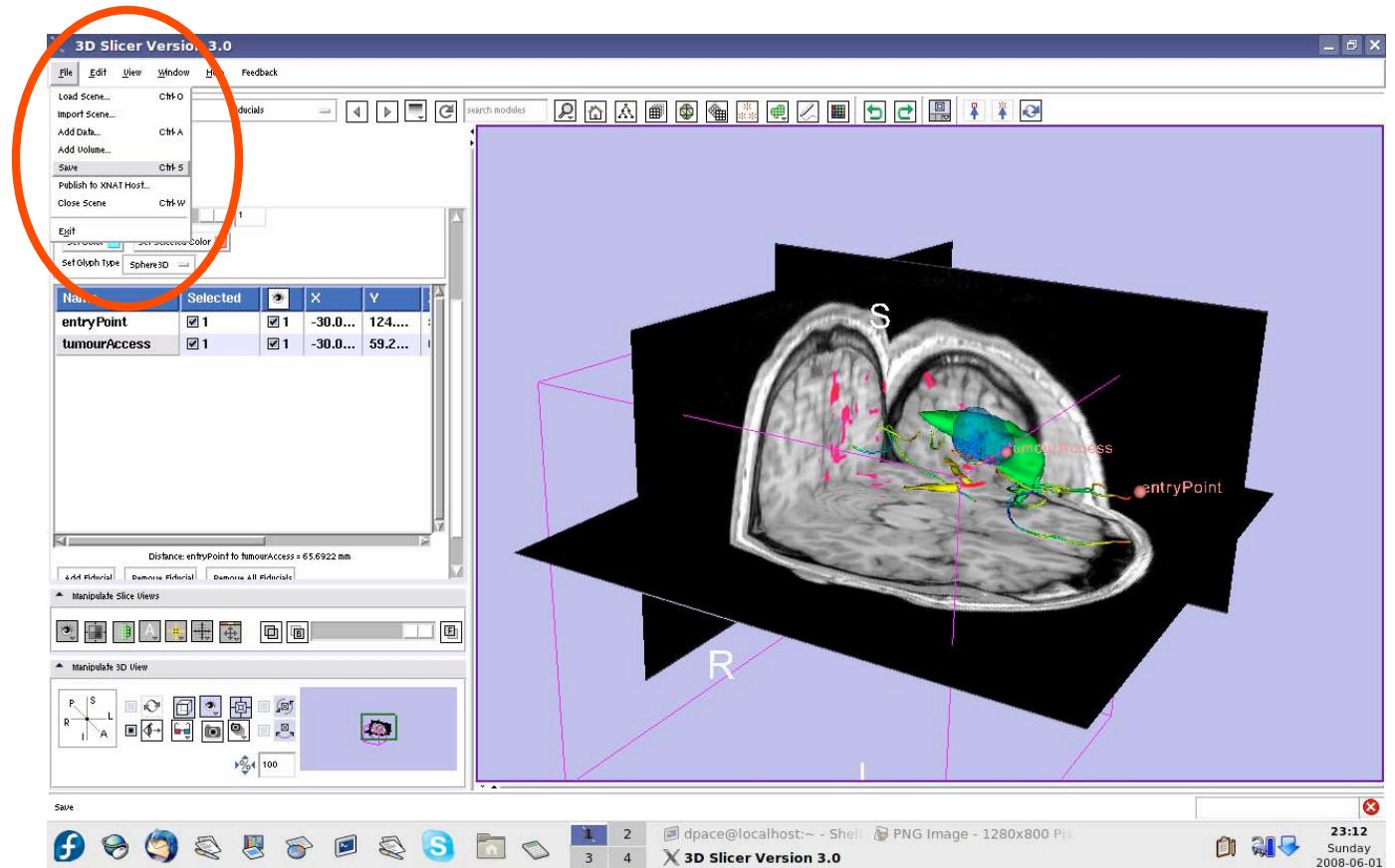
The result of neurosurgical planning





Save the scene

Select File ->
Save

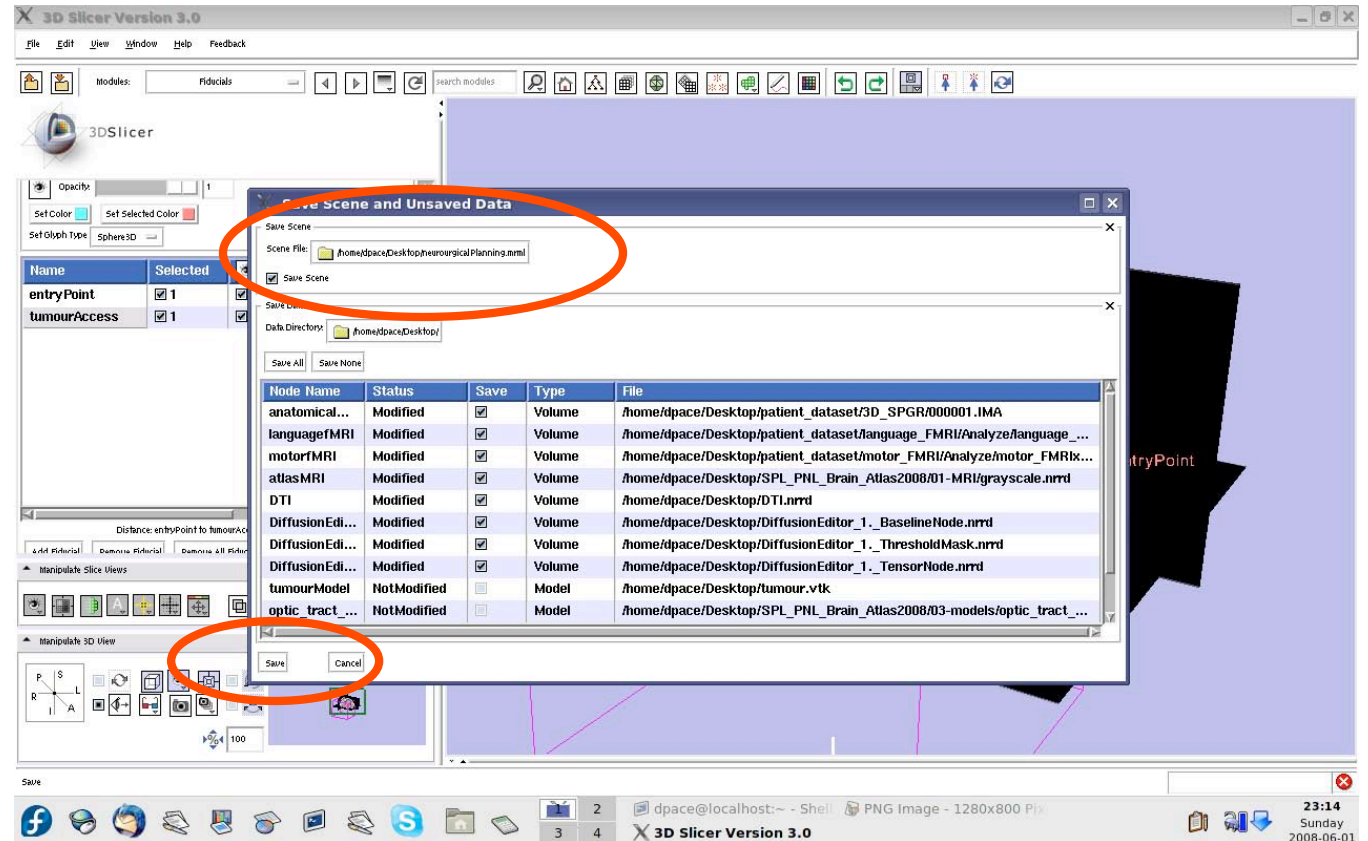




Save the scene

Click on the “Scene File” icon to name the .mrml scene and to specify its directory

Click “Save”





Overview

- **In this tutorial, you learned how to**
 - Register image volumes together
 - Segment and build models of structures of interest
 - Load diffusion weighted images, calculate tensors and perform fiber tractography

in order to build a preoperative neurosurgical plan incorporating

- anatomical MRI
- functional MRI
- a model of the tumour
- brain structure models from a registered atlas
- fiber tractography
- annotated fiducial points



Conclusions

- Slicer3 has extensive support for Image Guided Therapy
- Slicer3 is free open-source software that allows IGT researchers to share algorithms and work within a common framework



For more information...

Image registration:

- Read about the mutual information similarity measure here:

Wells, S. *et al.*, Multi-modal volume registration by maximization of mutual information. *Medical Image Analysis*, 1(1):35-51 (1996).

Collignon, A. *et al.*, Automated multimodality image registration based on information theory. *Proceedings of the International Conference on Information Processing in Medical Imaging*, 263-274 (1995).



For more information...

Model Making:

- Slicer3 uses the marching-cubes algorithm to generate models - read about it here:

Lorensen, W.E. and Cline, H.E. Marching cubes: a high resolution 3D surface construction algorithm. ACM SIGGRAPH Computer Graphics 21(4):163-169, 1987.



For more information...

Diffusion Tensor Imaging:

- A review on DTI:

Le Bihan, D. *et al.*, Diffusion Tensor Imaging: concepts and applications. *Journal of Magnetic Resonance Imaging*, 13:534-546 (2001)

- A review on tractography:

Mori, S. and van Zijl, P.C.M., Fiber tracking: principles and strategies - a technical review. *NMR in Biomedicine*, 15:468-480 (2002)