



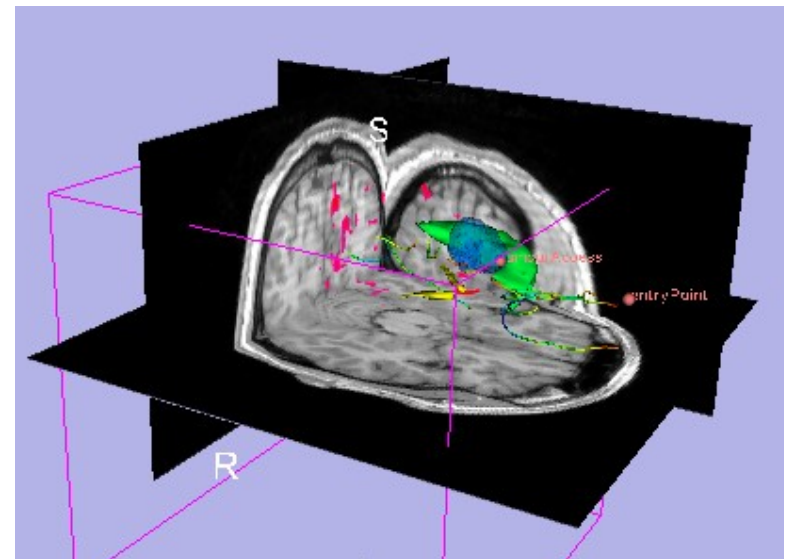
Image Guided Therapy in Slicer3

Planning for Image
Guided Neurosurgery

Danielle Pace, B.CmpH

Isaiah Norton

Haiying Liu





Acknowledgements



National Alliance for Medical Image Computing
NIH U54EB005149



Neuroimage Analysis Center
NIH P41RR013218



Brain Science Foundation



Surgical Planning Laboratory (BWH)
Nobuhiko Hata, Steve Pieper, Ron Kikinis, Haiying Liu, Sonja Pujol,
Randy Gollub, Rodrigo de Luis Garcia, Carl-Fredrik Westin



National Center for Image Guided Therapy
NIH U41RR019703



NEDO Intelligent Surgical Instruments Project
Kiyo Chinzei



Acknowledgements

Thanks to

- **Alexandra Golby**, Department of Neurosurgery, Brigham and Women's Hospital
- **James Miller**, Visualization and Computer Vision, GE Research
- **Kilian Pohl**, Surgical Planning Laboratory, Department of Radiology, Brigham and Women's Hospital and Harvard Medical School
- **Takashi Suzuki**, Faculty of Advanced Techno-Surgery, Institute of Advanced Biomedical Engineering and Science, Tokyo Women's Medical University
- **Stephen Whalen**, Department of Neurosurgery, Brigham and Women's Hospital

for their helpful comments and suggestions

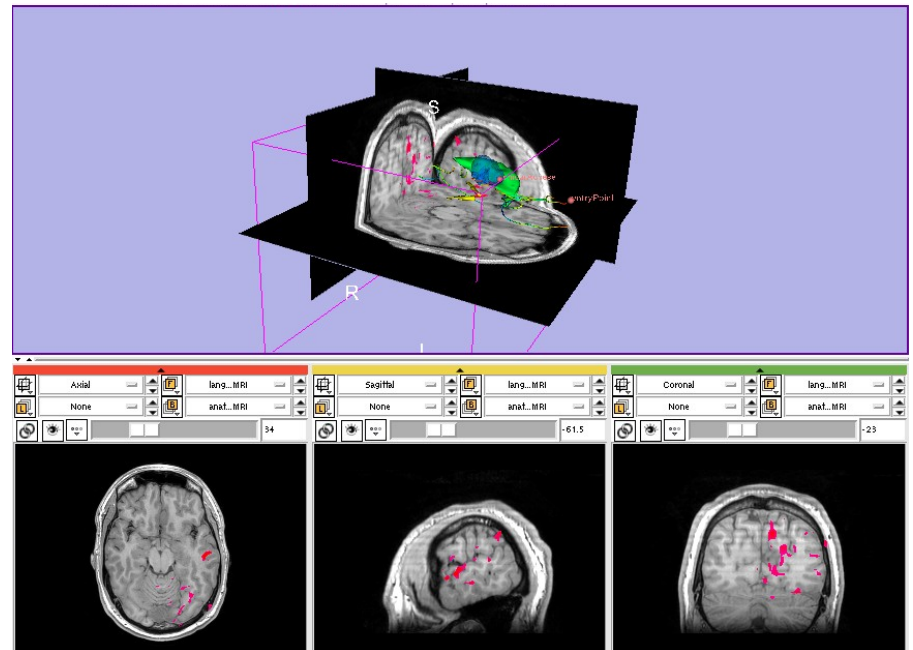


Learning objectives

Following this tutorial, you will be able to perform many common Image Guided Therapy tasks using Slicer3, including:

- image registration
- model making
- DTI tractography

using the example of preoperative planning for image guided neurosurgery





Material

This course requires the installation of the Slicer3 software and the training datasets accessible at the following locations:

- Slicer3 software and building instructions:
<http://www.slicer.org/pages/Downloads>
- Patient dataset, SPL-PNL brain atlas, and three pre-computed MRML scenes
[http://wiki.na-mic.org/Wiki/index.php/IGT:
ToolKit/Neurosurgical-Planning](http://wiki.na-mic.org/Wiki/index.php/IGT:ToolKit/Neurosurgical-Planning)

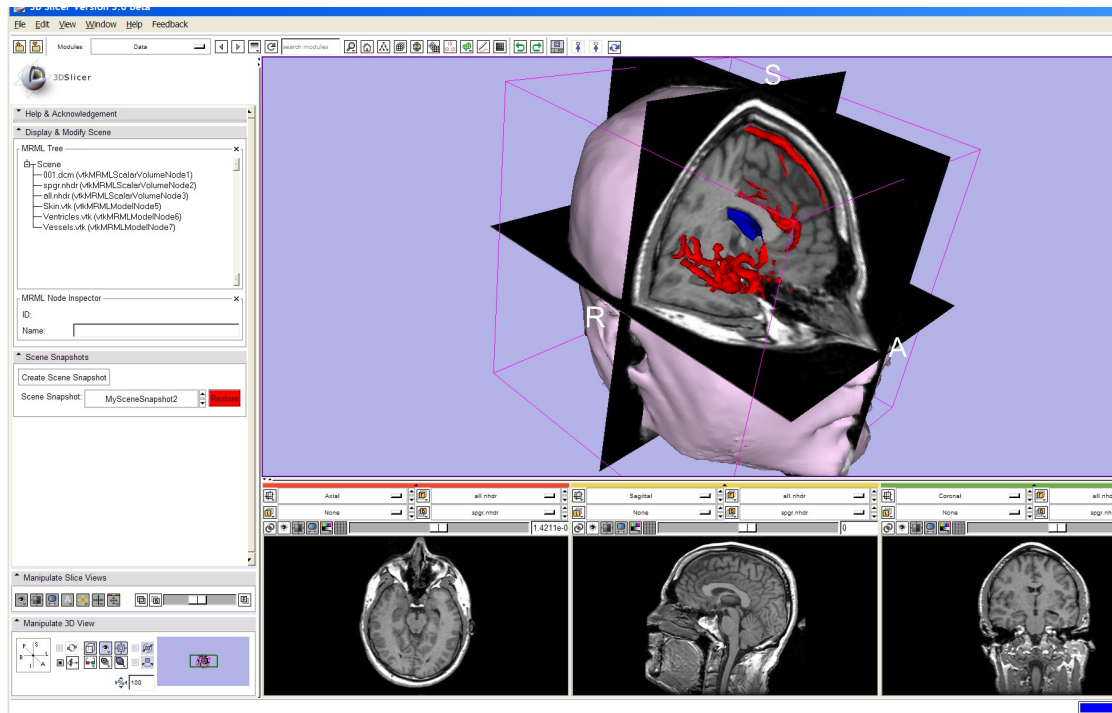
Disclaimer: It is the responsibility of the user of 3D Slicer to comply with both the terms of the license and with the applicable laws, regulations and rules.



Prerequisites

- Data Loading and Visualization in Slicer3:

http://wiki.na-mic.org/Wiki/index.php/Slicer:Workshops:Slicer3_Training





3D Slicer

- Integrates algorithms and utilities for medical image computing research and Image Guided Therapy into a single framework
- Is both an end-user application and a platform for research
- The precompiled program and the source code are both freely downloadable

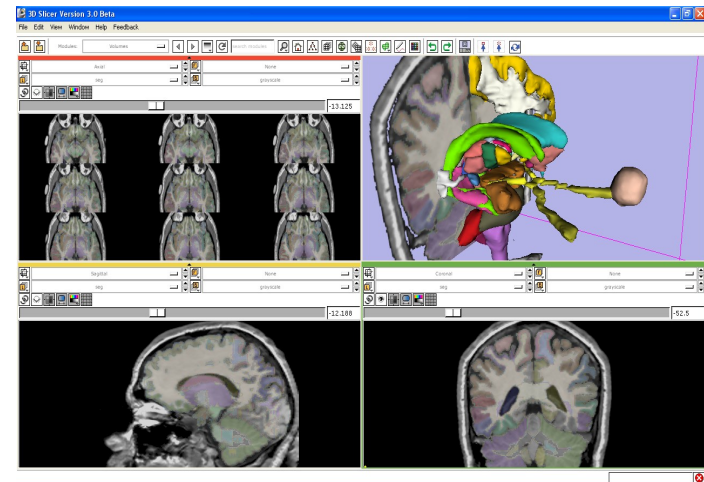
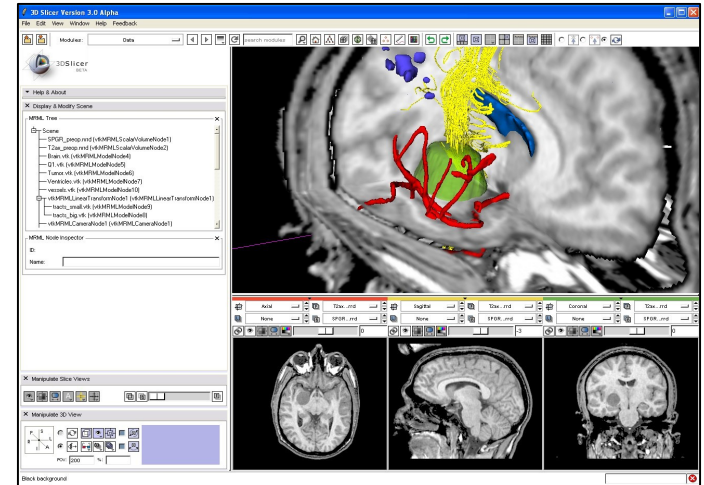




Image Guided Therapy (IGT) in Slicer3

Slicer3 has extensive support for IGT, including:

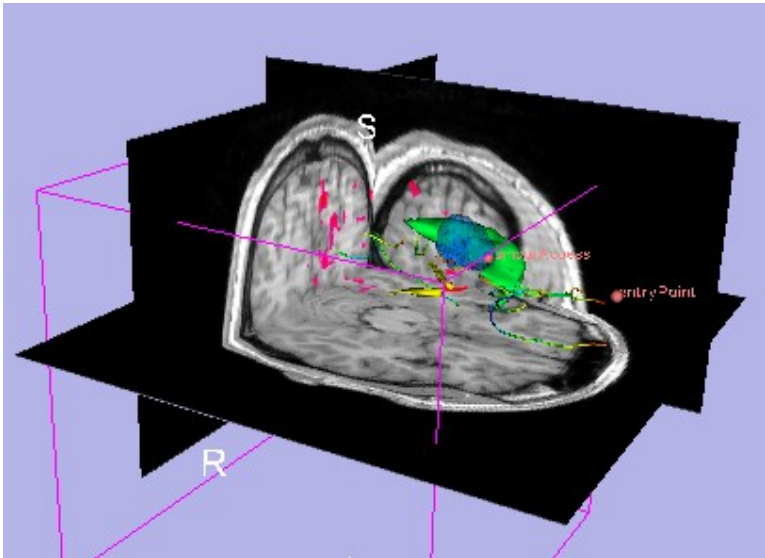
- Visualization
- Registration
- Segmentation
- Model making
- Diffusion Tensor Imaging
- Quantification
- Filtering
- Interfacing to imaging devices, trackers and medical robots

**Focus of
this tutorial**



The goal of neurosurgical planning

- Prior to surgery:
 - Integrate image information from multiple sources, including anatomical MRI, functional MRI and diffusion tensor imaging
 - Highlight structures of interest
 - Determine the best surgical approach

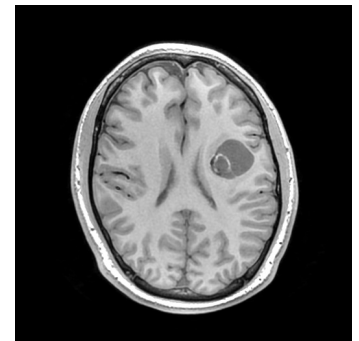




Clinical Case - brain tumour resection

- Imaging showed a large lesion in the left frontal region of the brain, predicted to be a glioma (brain tumour originating from glial cells)
- Preoperative imaging included 3D SPGR MRI, T2-weighted MRI and FLAIR MRI, language and motor functional MRI (fMRI) imaging, and diffusion tensor imaging (DTI)
- fMRI showed speech areas close to the lesion
- Surgical procedure: left frontal craniotomy and tumour resection

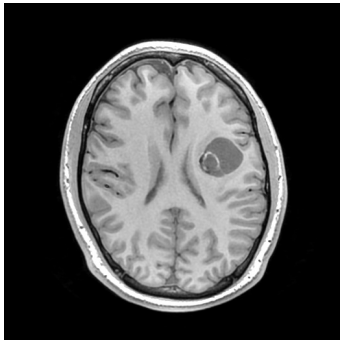
See the [clinical_background](#) file within the patient dataset for more information



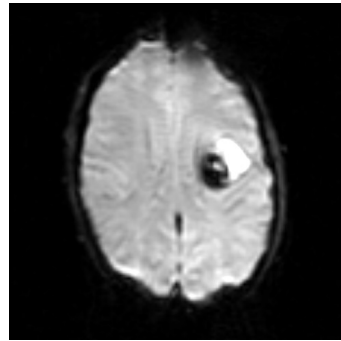


Tutorial datasets

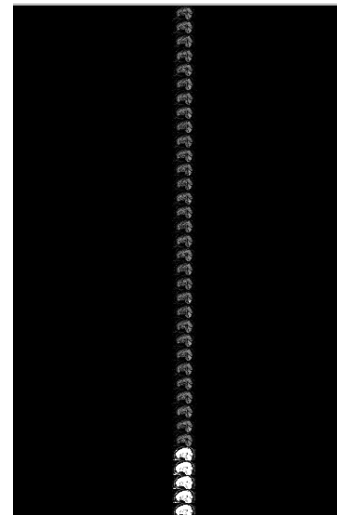
- Three clinical datasets from a single patient with a large tumour in the left frontal region
- SPL-PNL brain atlas (based on a single healthy patient)



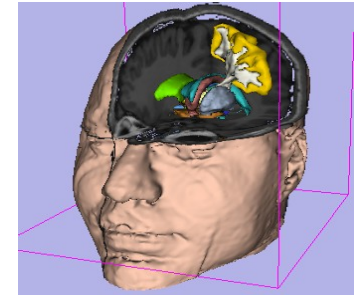
**SPGR MRI
(anatomical)**



**Language
fMRI**



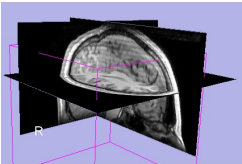
**Diffusion
Weighted
Images**



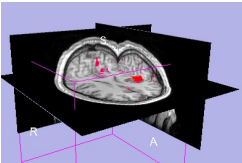
**SPL-PNL
brain atlas**



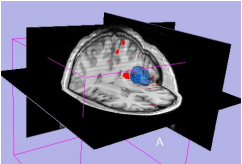
Overview



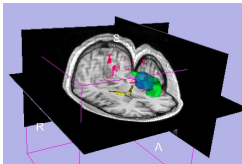
1. Loading and visualizing anatomical MRI data



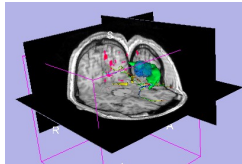
1. Incorporating fMRI data using image registration and thresholding



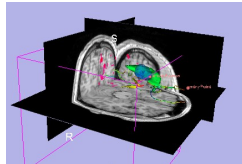
1. Creating a 3D model of the tumour volume



1. Predicting the locations of brain structures using image registration and a brain atlas



1. Incorporating brain fiber tractography from diffusion weighted images



1. Annotating the preoperative plan and saving the scene



Anatomical imaging

- **Utility of anatomical imaging in IGT:**
 - Visualize brain structures of interest, such as the lesion
 - Perform measurements on structures of interest
 - Provide context for the rest of the scene



Anatomical imaging

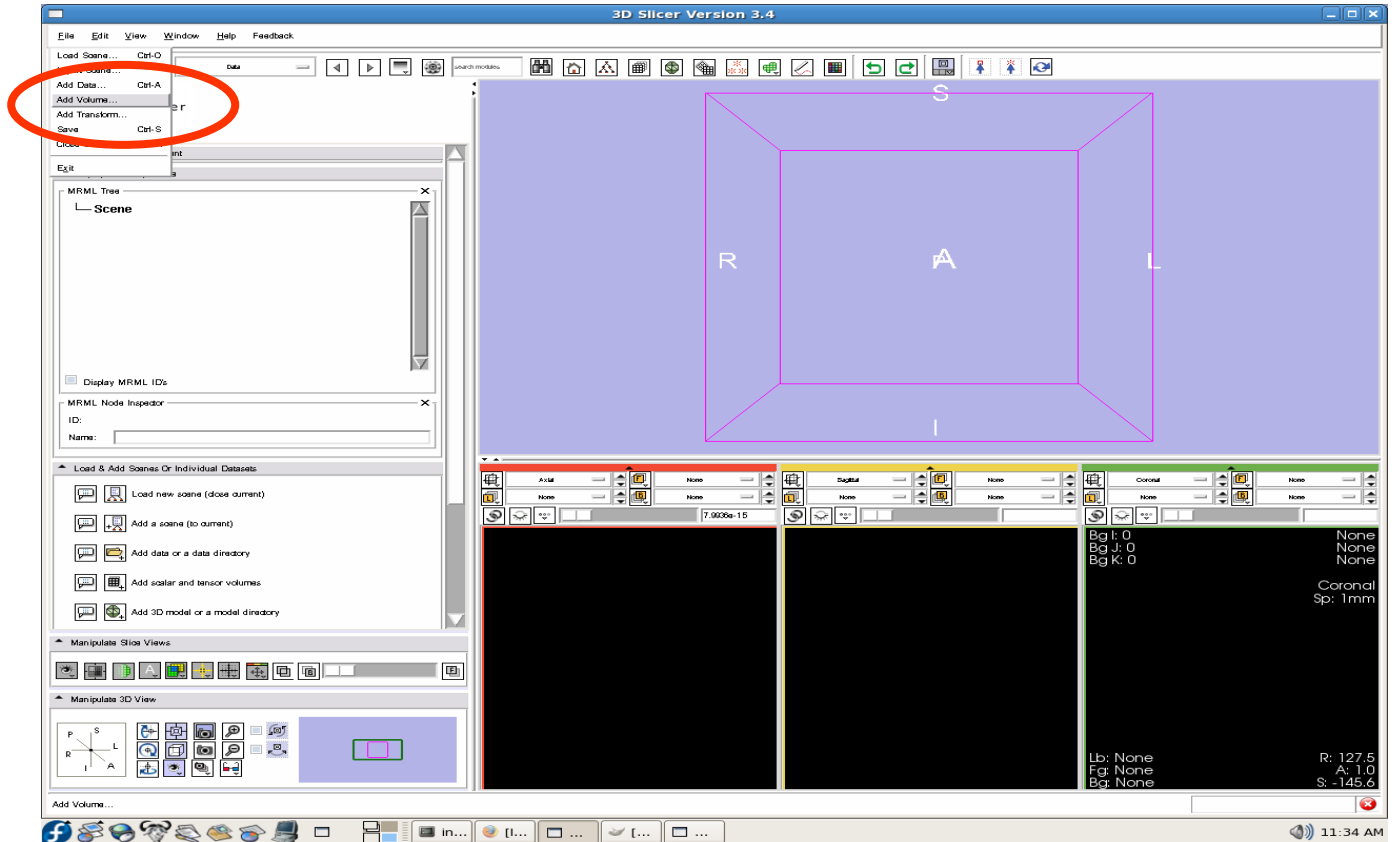
- **Steps involved in this section:**

Load anatomical MRI from patient dataset



Load the anatomical MRI data

Select
“Add
Volume”
from the
File menu

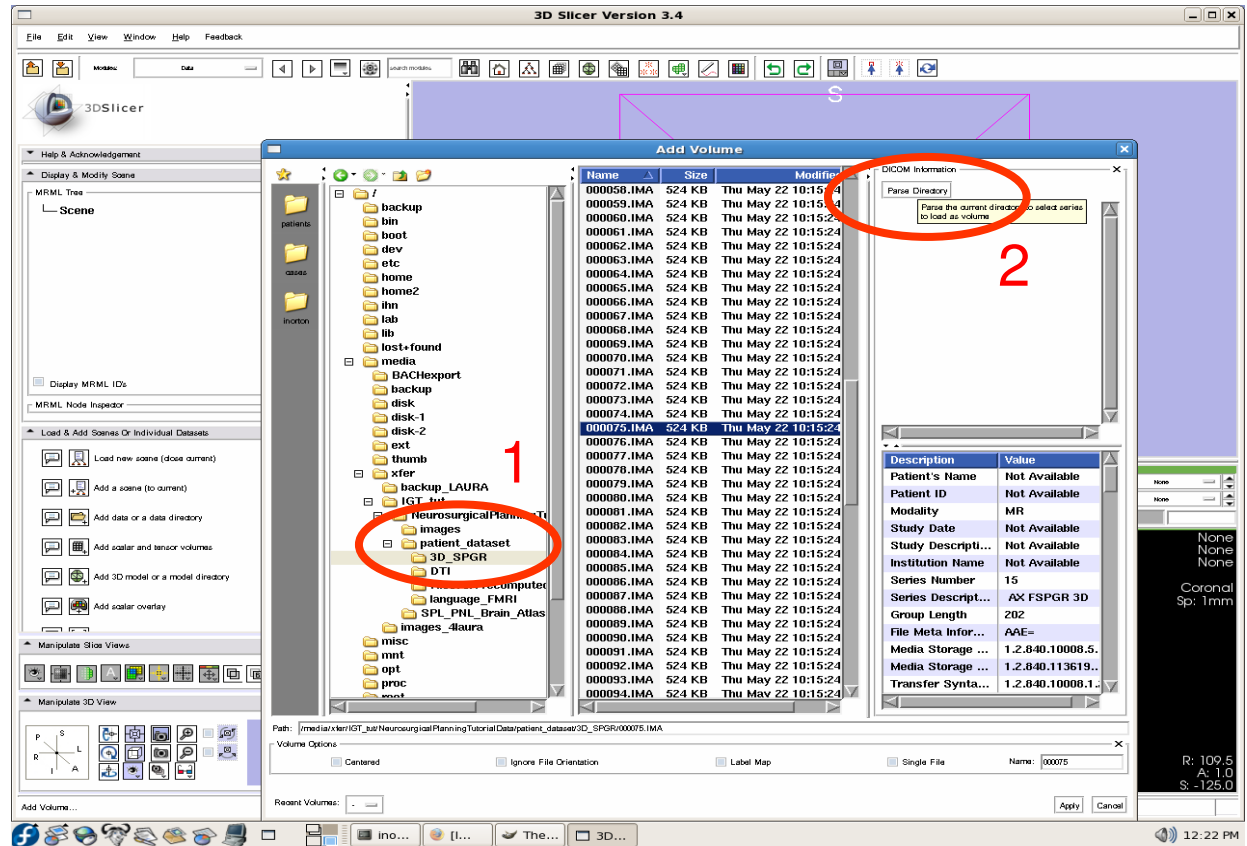




Load the anatomical MRI data

Select the “3D_SPGR” folder under patient_data set

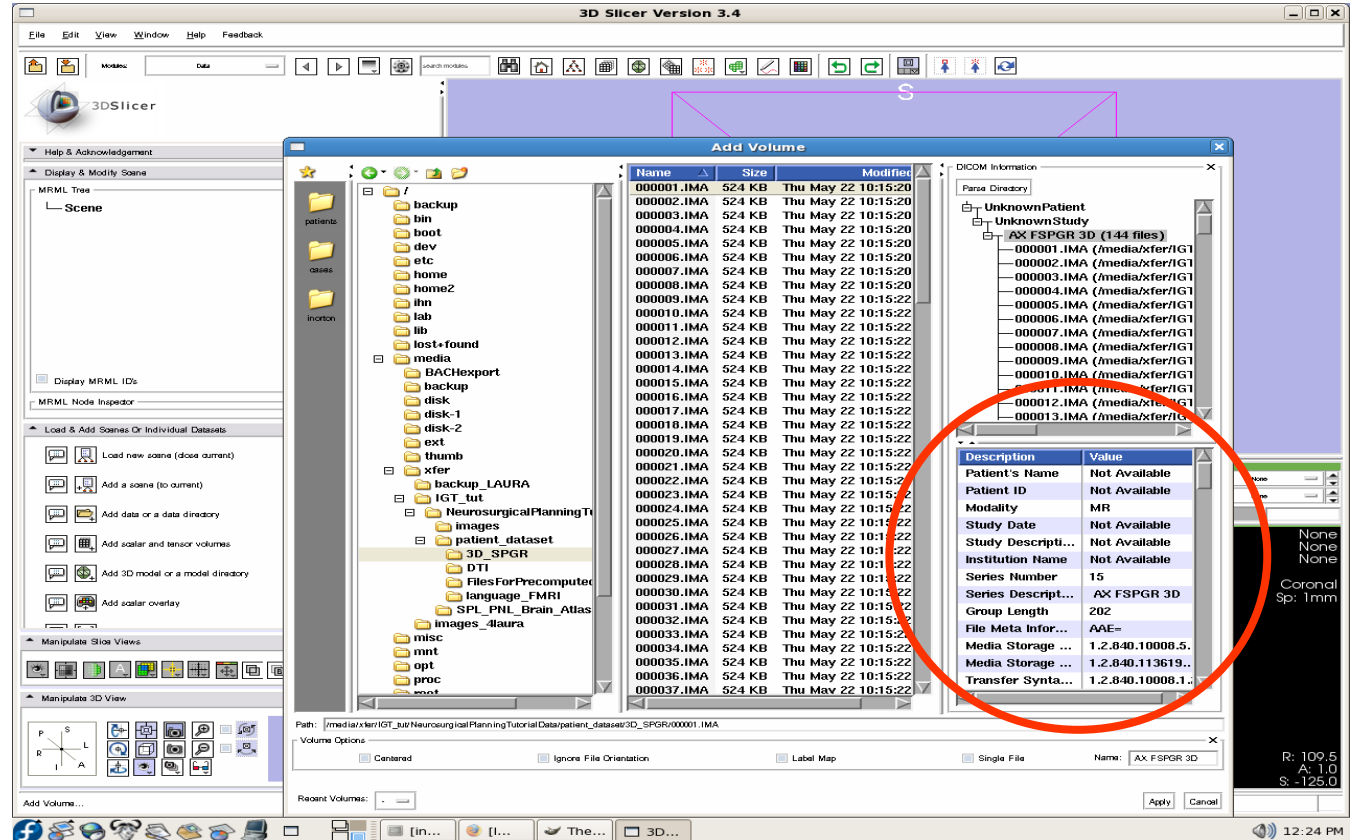
Click “Parse Directory”





Load the anatomical MRI data

Note the DICOM fields at right, displaying patient information and scan parameters.

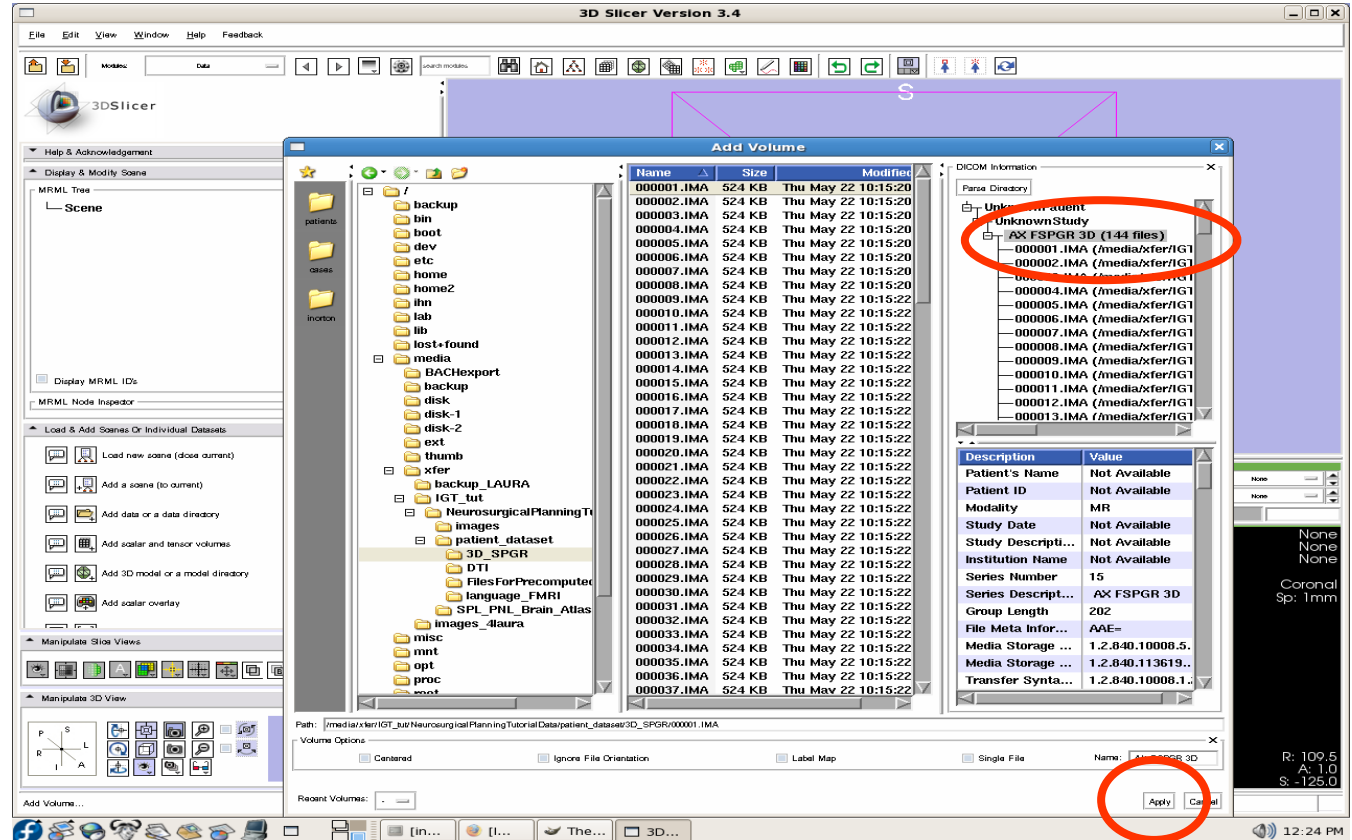




Load the anatomical MRI data

Select
“AX
FSPGR
3D”

Click
“Apply” to
load the
file.





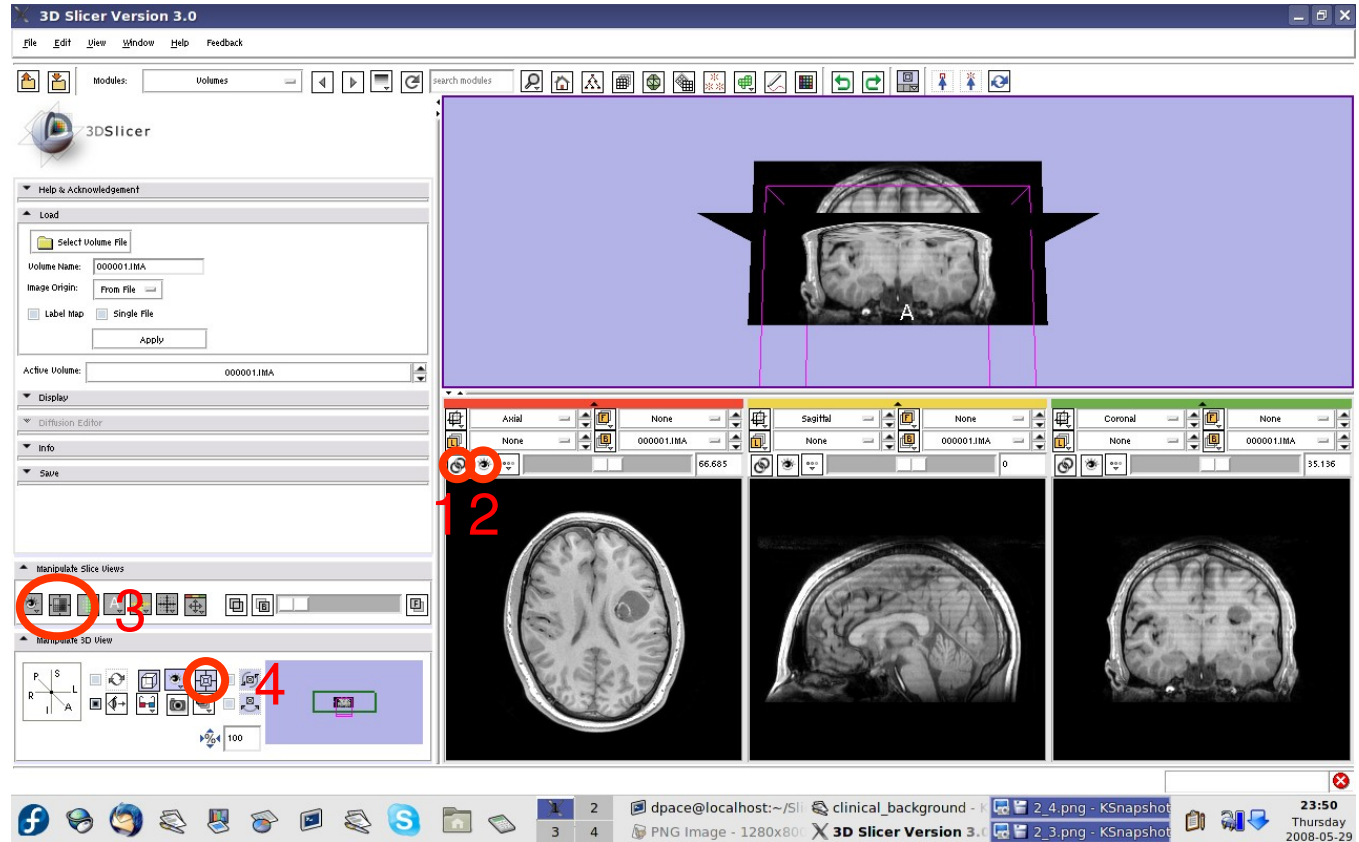
Load the anatomical MRI data

Click on the “link” button

Click on the “visibility” button

Click on the “fit to window” button

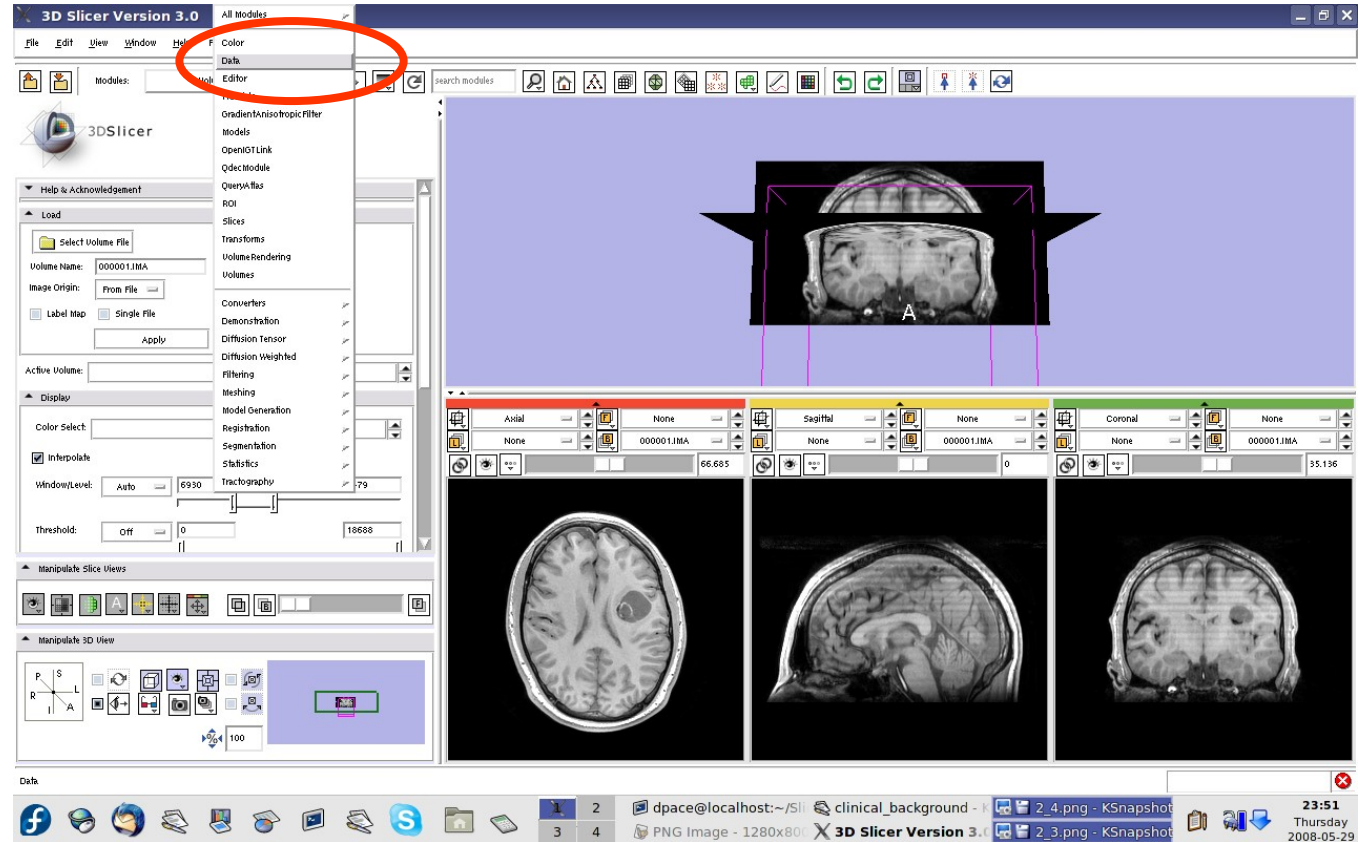
Click on the “center 3D view” button





Load the anatomical MRI data

Open the Data module



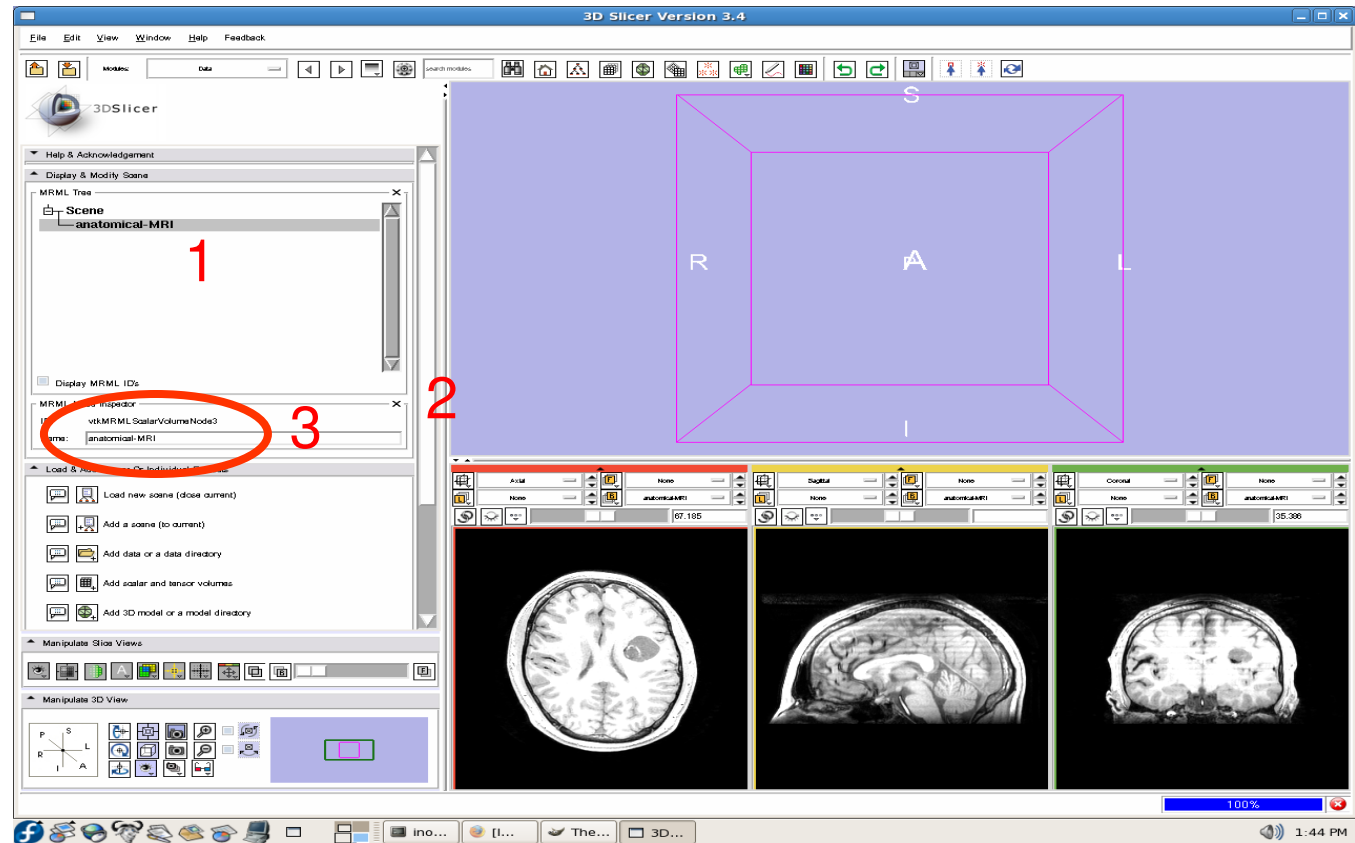


Load the anatomical MRI data

Click on the “AX SPGR 3D” node

Expand the “Node Inspector”,

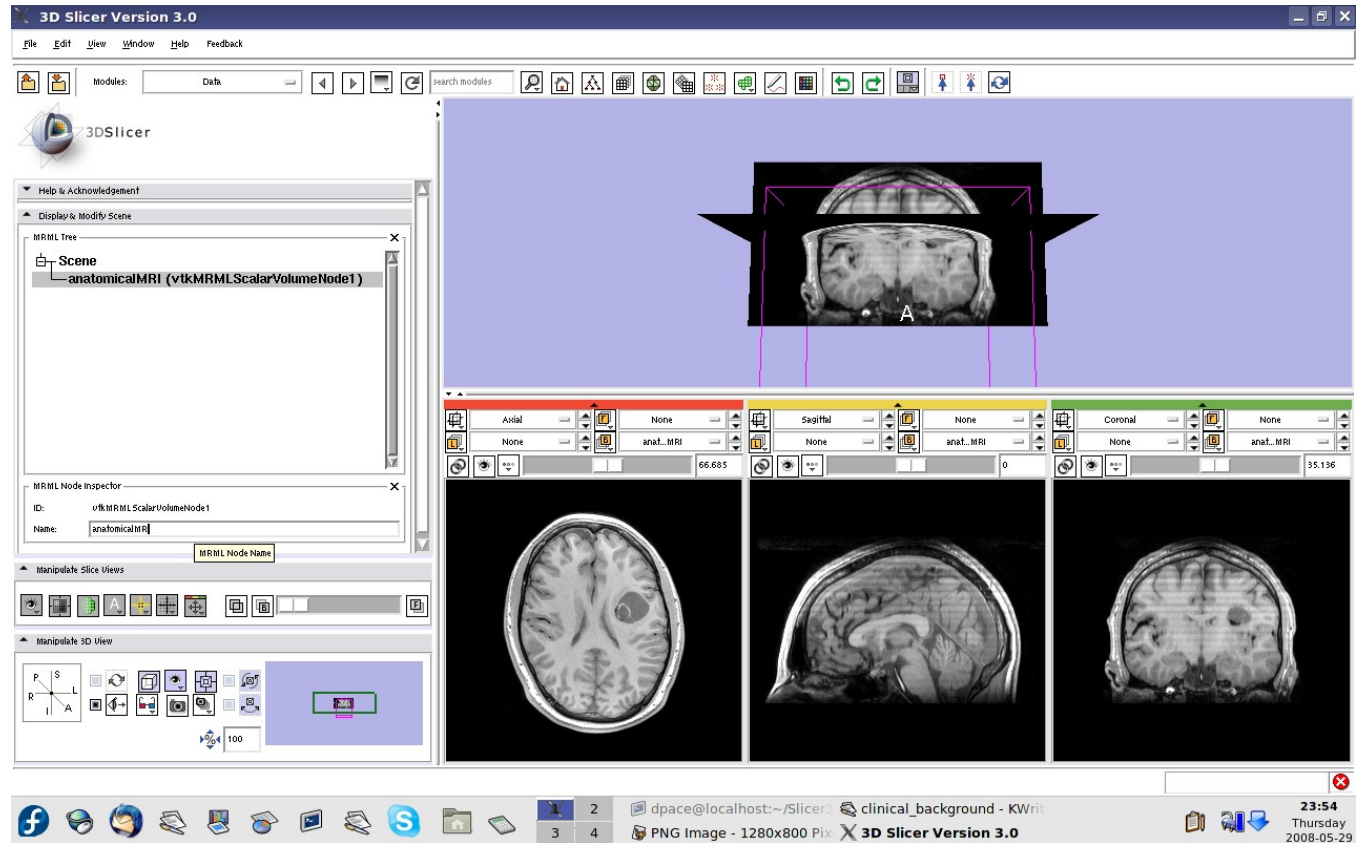
enter “anatomical-MRI” and press Enter





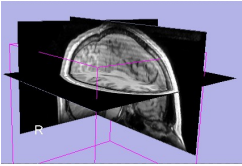
Load the anatomical MRI data

Observe that the name of the node is changed in the MRML tree

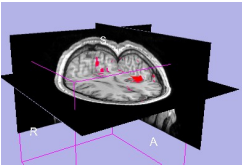




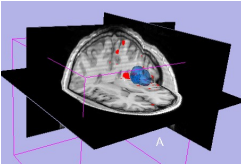
Overview



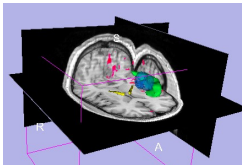
1. Loading and visualizing anatomical MRI data



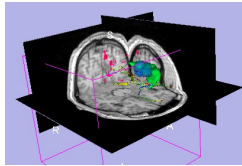
1. **Incorporating fMRI data using image registration and thresholding**



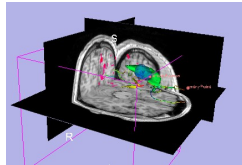
1. Creating a 3D model of the tumour volume



1. Predicting the locations of brain structures using image registration and a brain atlas



1. Incorporating brain fiber tractography from diffusion weighted images



1. Annotating the preoperative plan and saving the scene

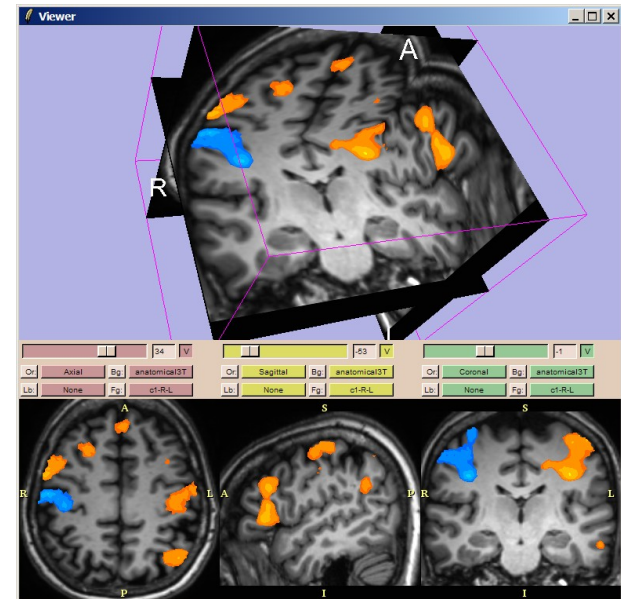


Functional MRI (fMRI)

- **fMRI:**

- Measures the blood oxygen level in each part of the brain while the patient performs a task, such as a speech or motor task
- Statistical techniques are used determine which brain regions are active during the task
- This statistical pre-processing has already been done using SPM

(<http://www.fil.ion.ucl.ac.uk/spm/>)



SPM



Functional MRI (fMRI)

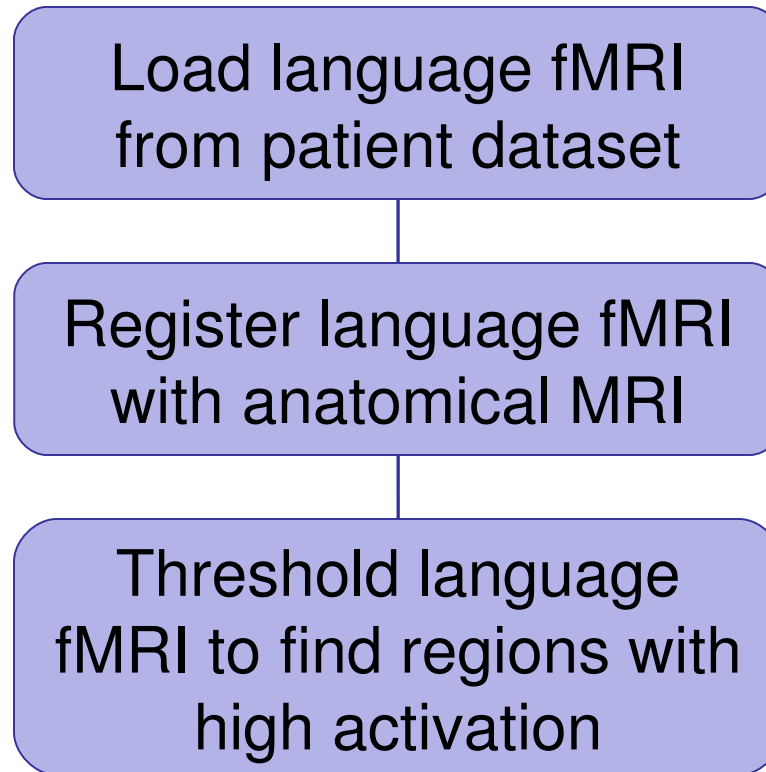
- **Utility of functional MRI in IGT:**

- Damage to regions of the brain important for language or movement could result in problems with speech, reading or movement
- Knowing where these regions are allows us to modify our surgical plan so that we avoid them (as much as possible)



Functional MRI (fMRI)

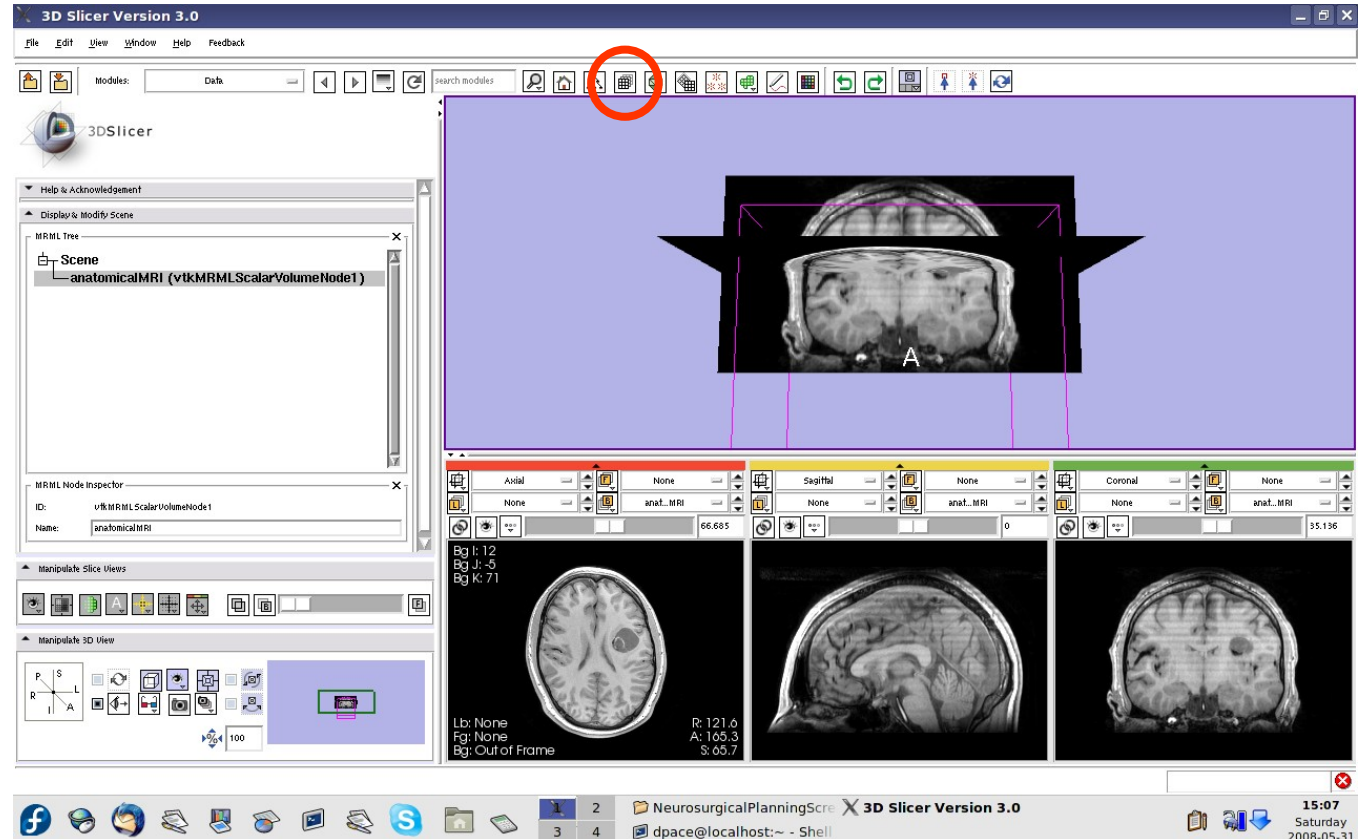
- **Steps involved in this section:**





Load the language fMRI data

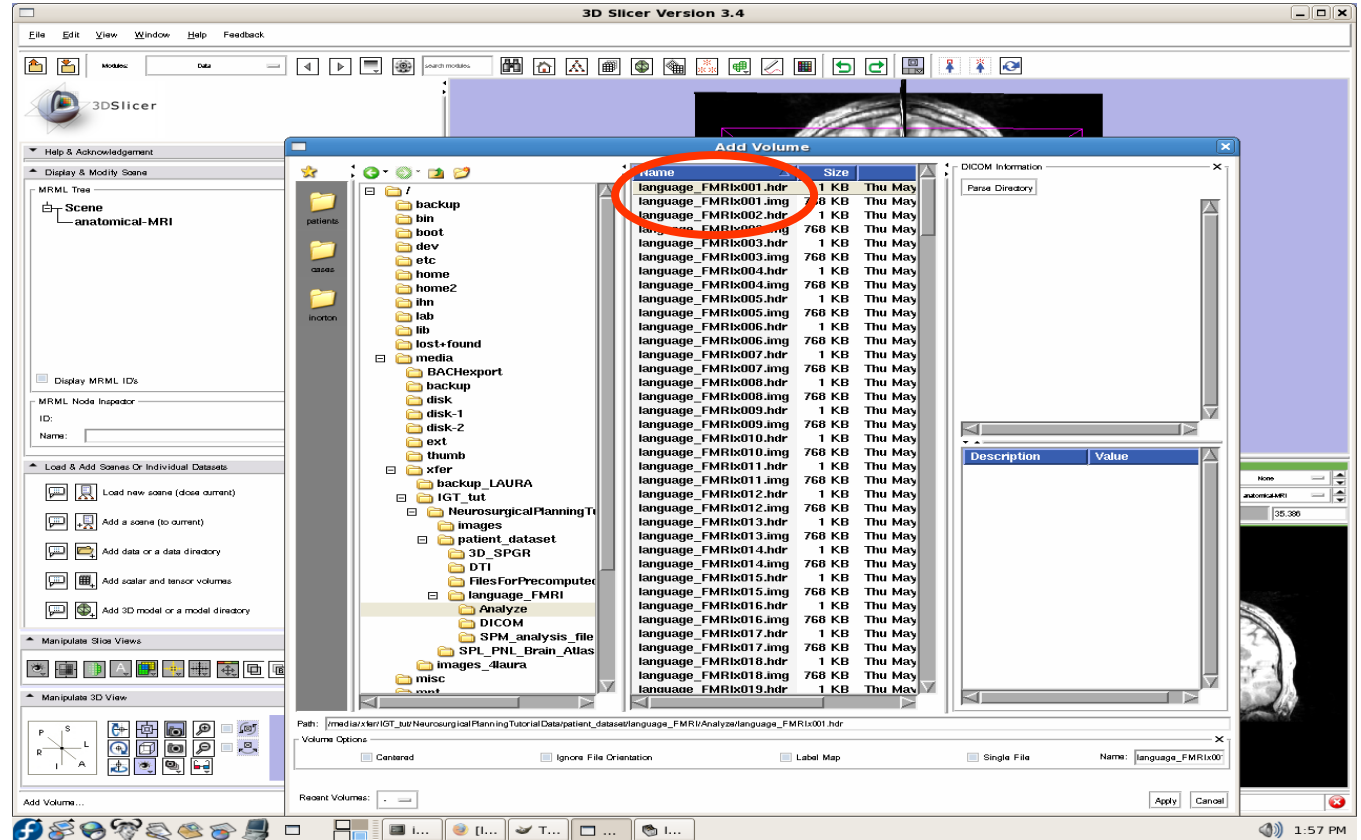
Open the Volumes module





Load the language fMRI data

Click on the first .hdr image in the Analyze folder within the language_FMRI folder of the patient dataset,



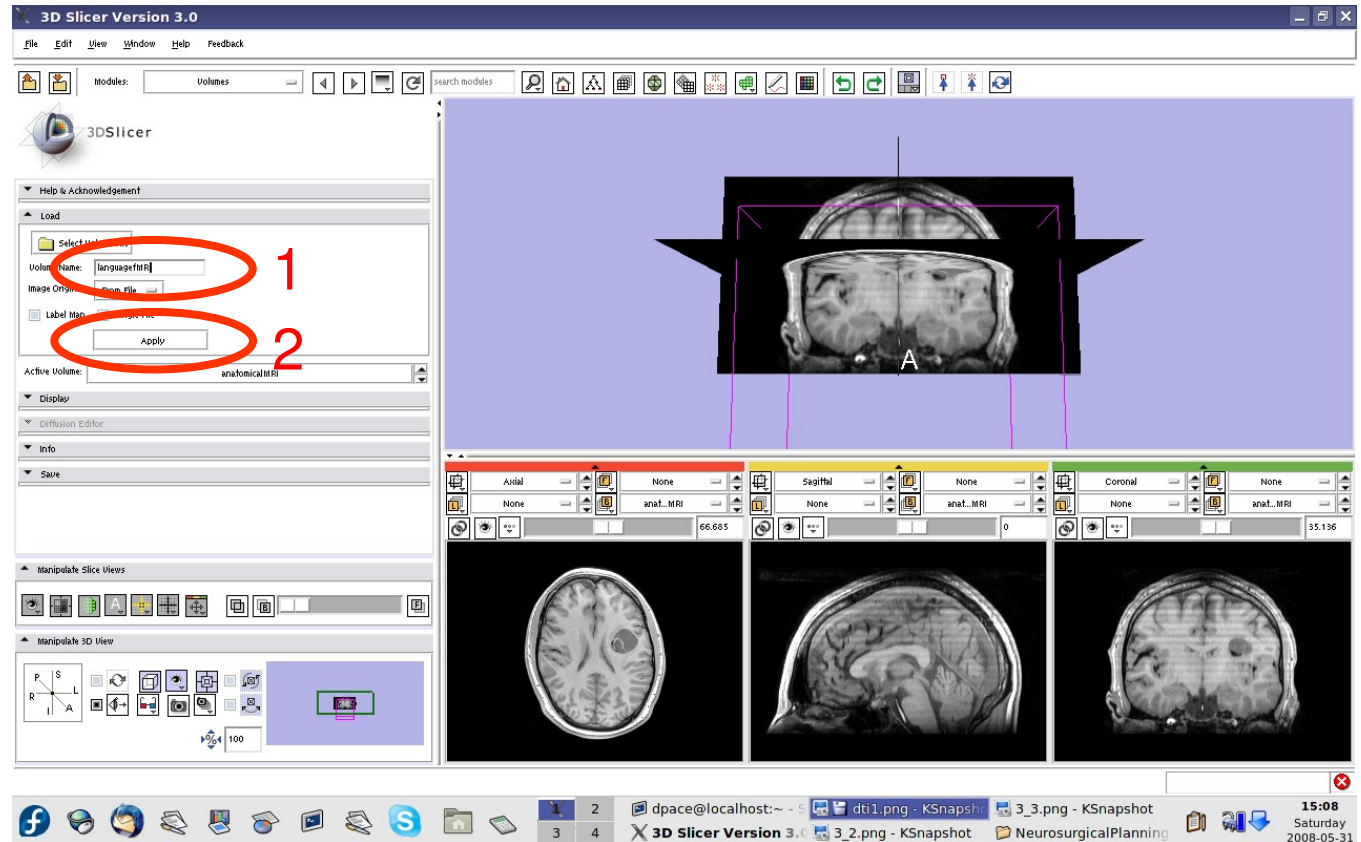


Load the language fMRI data

Set the Volume Name to languagefMRI

Keep the image origin set to “From File”

Click on “Apply”



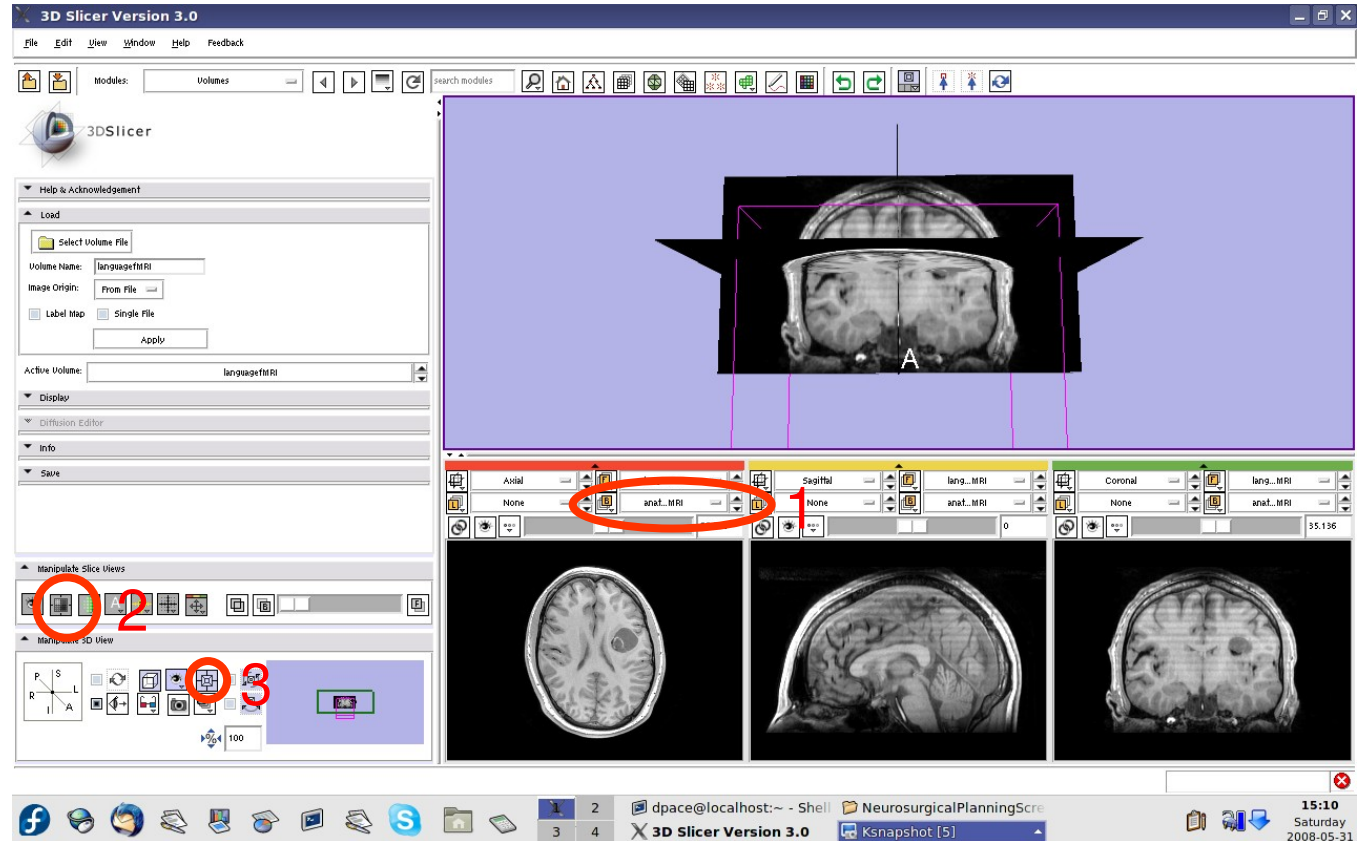


Load the language fMRI data

Set the background volume to anatomicalMRI

Click on the “fit to window” button

Click on “Center 3D View” button.

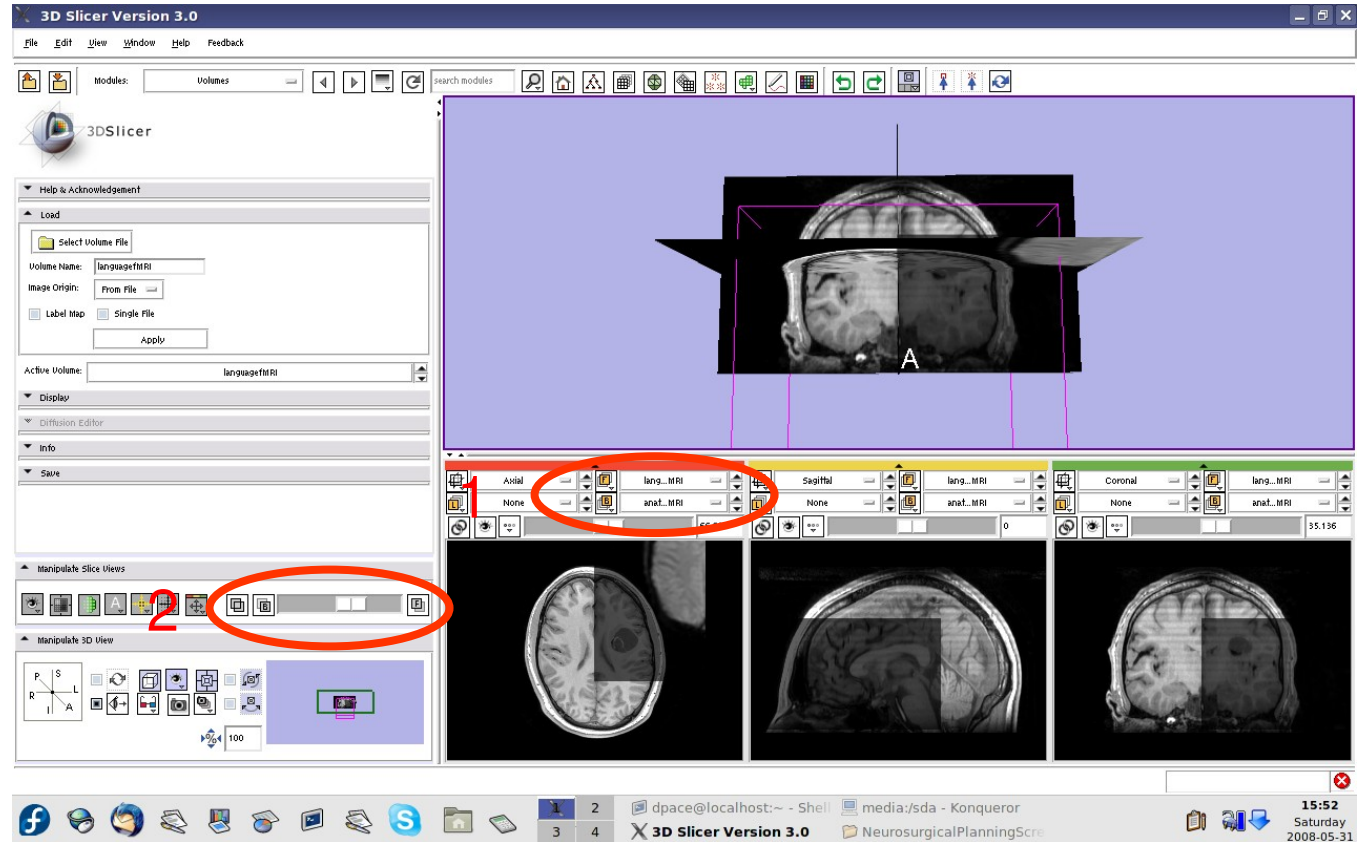




Load the language fMRI data

Set anatomical MRI to background and language fMRI to foreground

Scale the opacities to see both the foreground and background layers





Load the language fMRI data

Note that the image volumes are not aligned

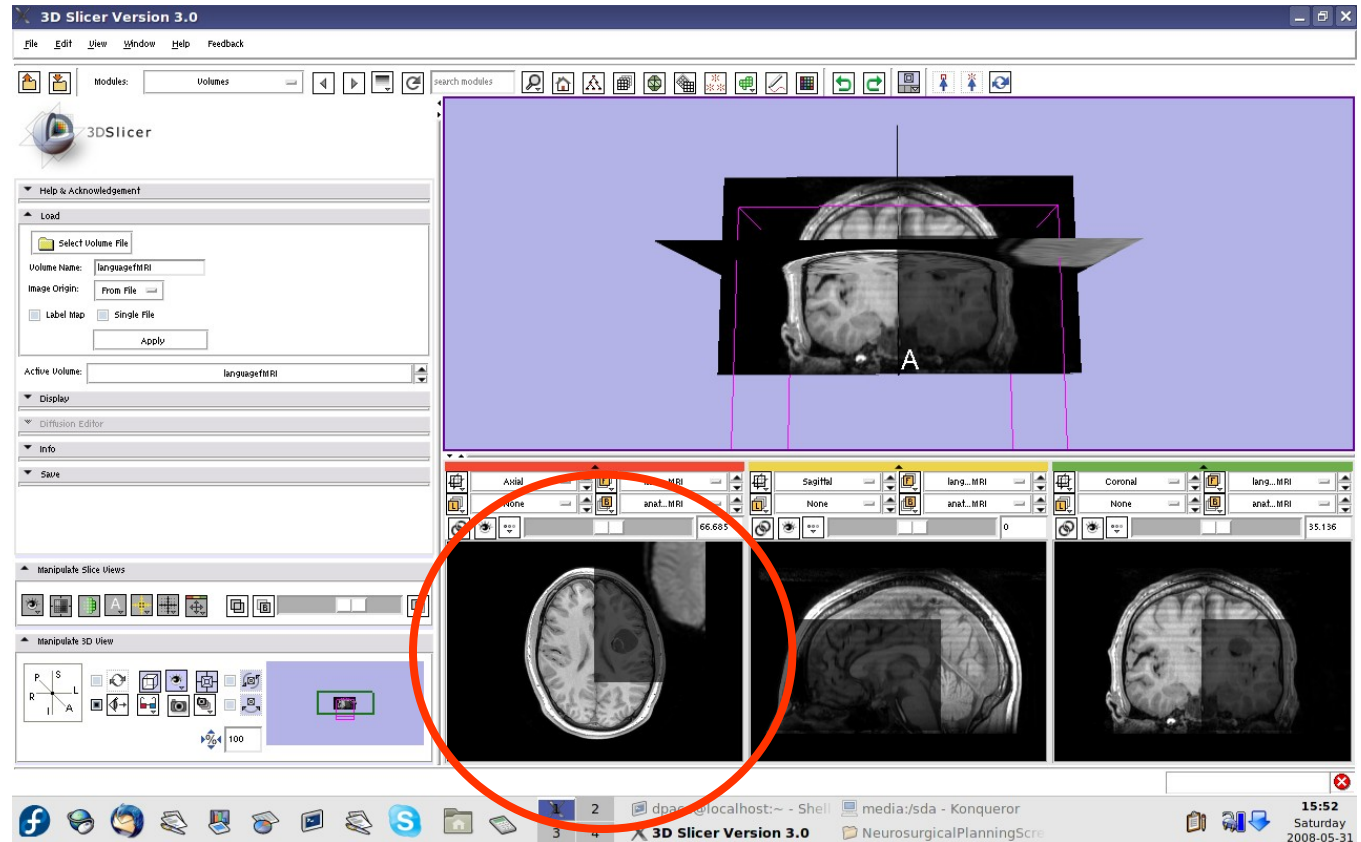
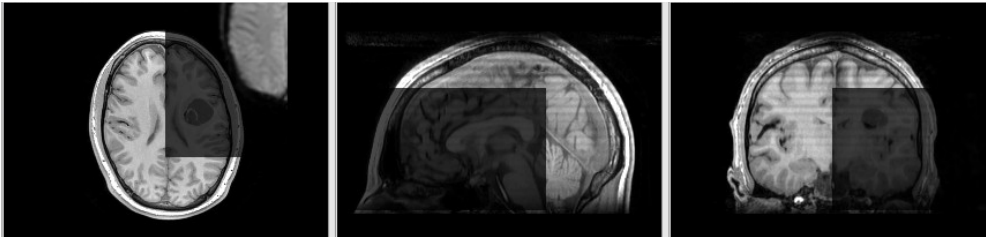
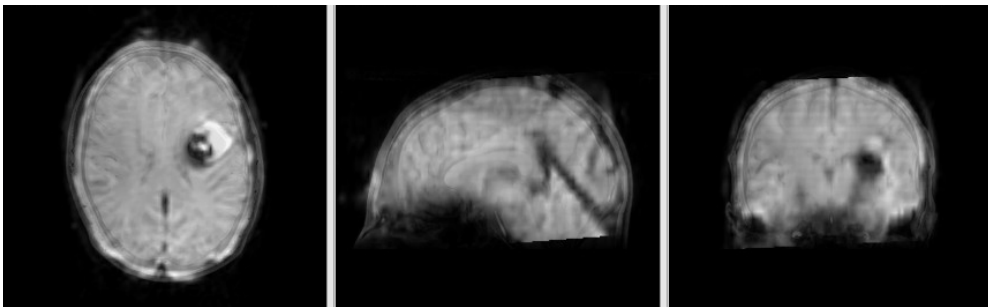




Image-to-Image registration



The anatomical MRI and functional MRI image volumes are **not aligned**



The anatomical MRI and functional MRI image volumes **overlap**

Image registration aligns two images together with the goal of making the corresponding anatomy overlap



Image-to-image registration

- **Steps involved in image registration:**

Initial manual transformation

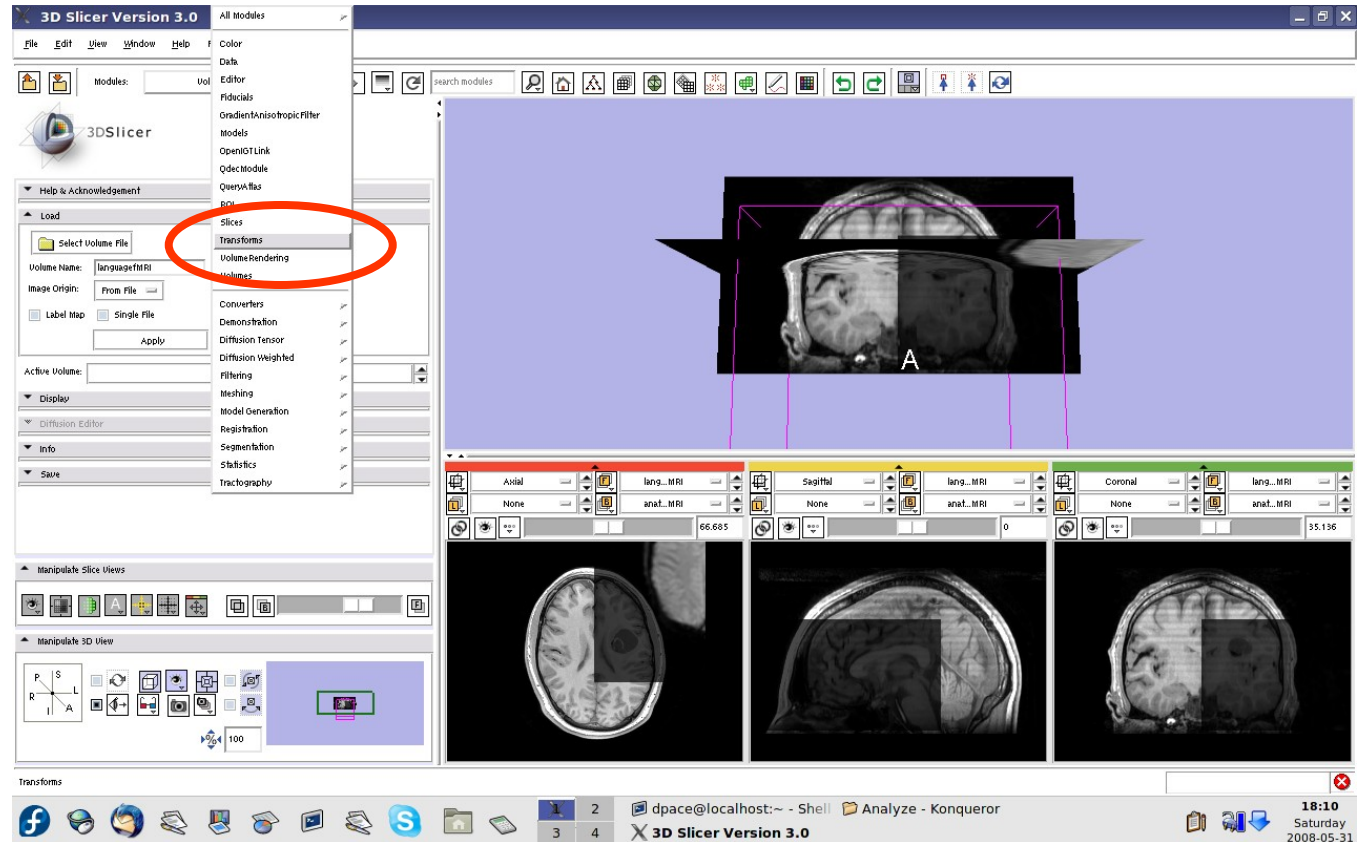
Automatic affine registration

- An affine transformation estimates the rotation, translation, scale and shear needed to align the **moving** image with the **fixed** image
- Slicer's affine registration module uses **mutual information** to estimate the similarity between two images



Initial manual transformation

Open the Transforms module

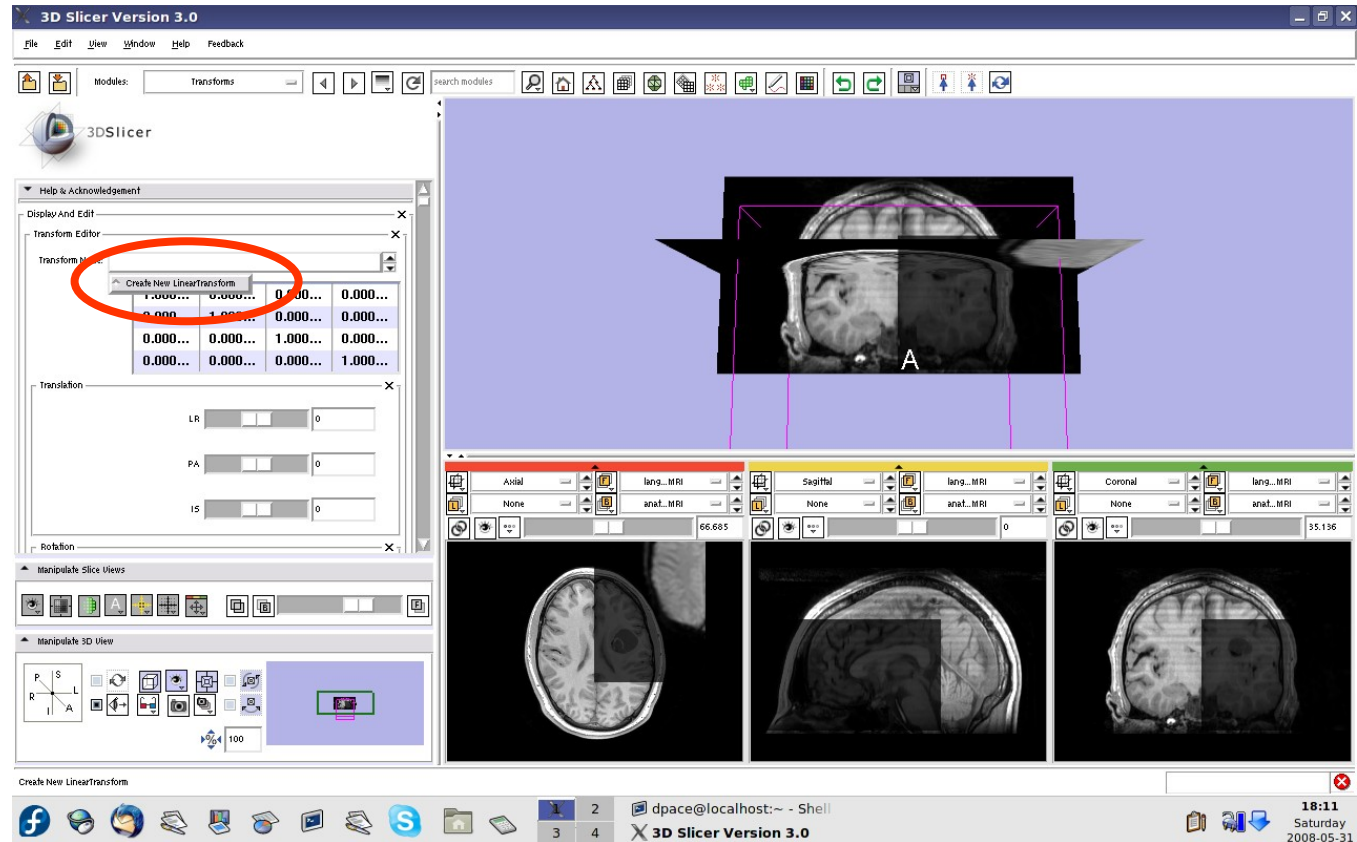




Initial manual transformation

Create a new linear transform

The new transform is initialized to the identity matrix

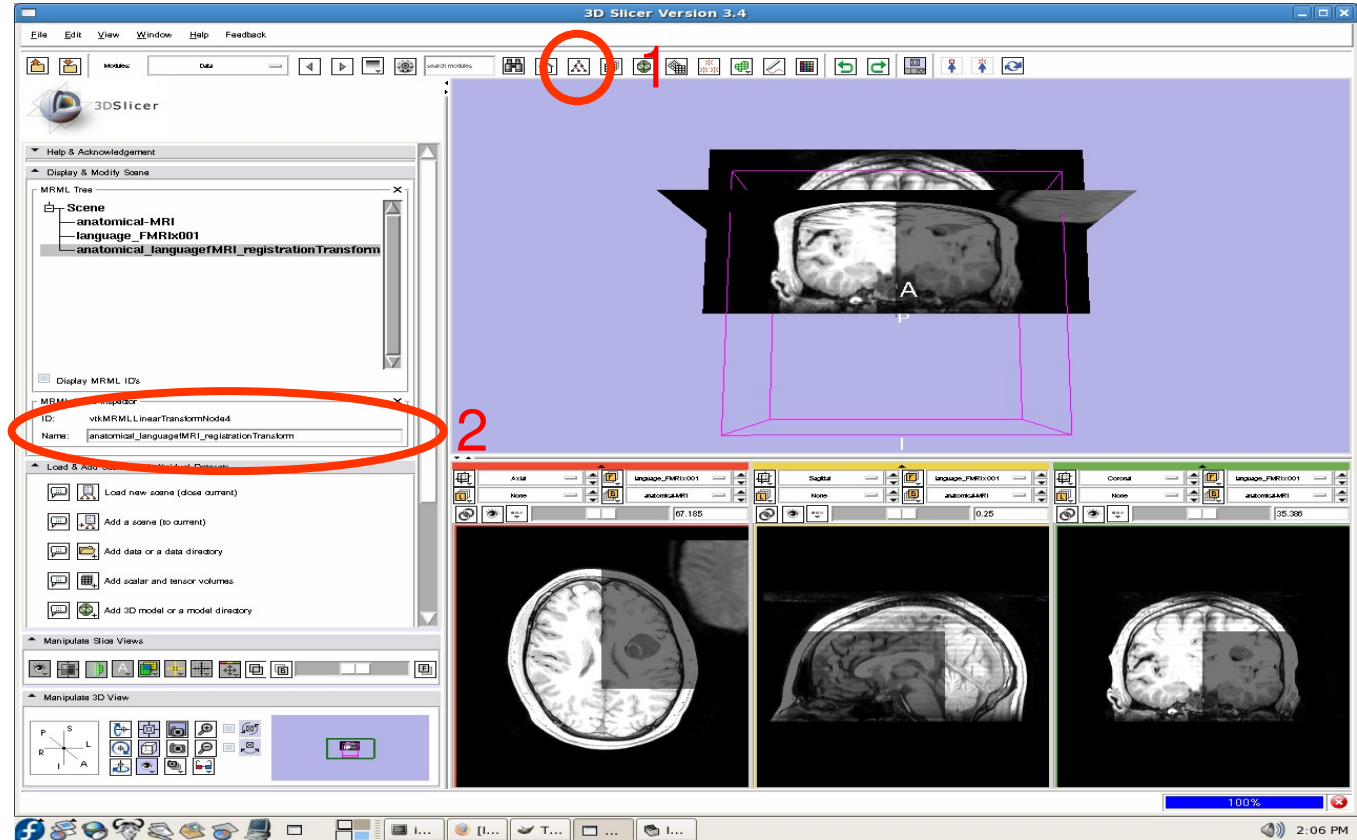




Initial manual transformation

Open the Data module

Change the name of the transform to “anatomical_languagefMRI_registrationTransform”

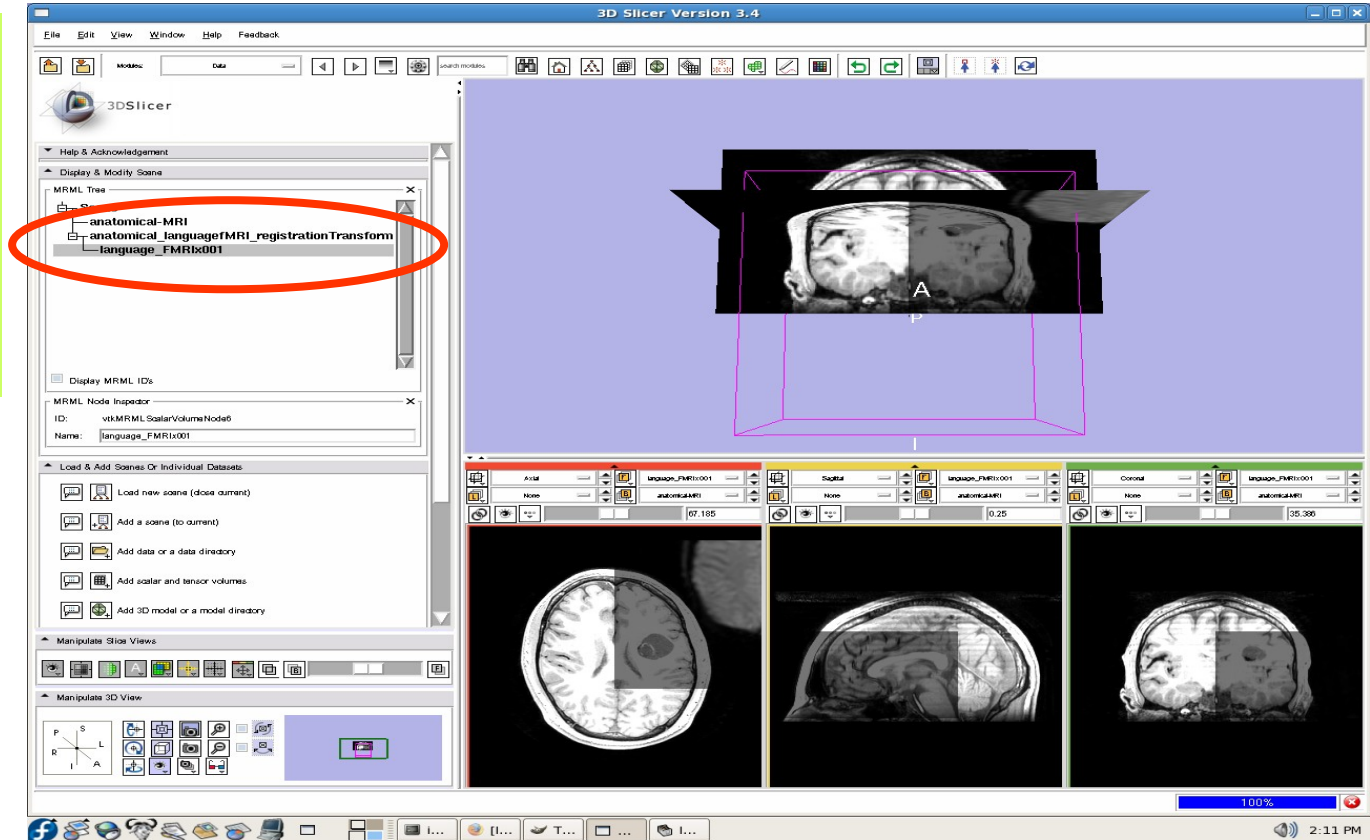




Initial manual transformation

Drag the languagefMRI node under the transform node

Now any changes to the transform node are applied to the language fMRI image volume

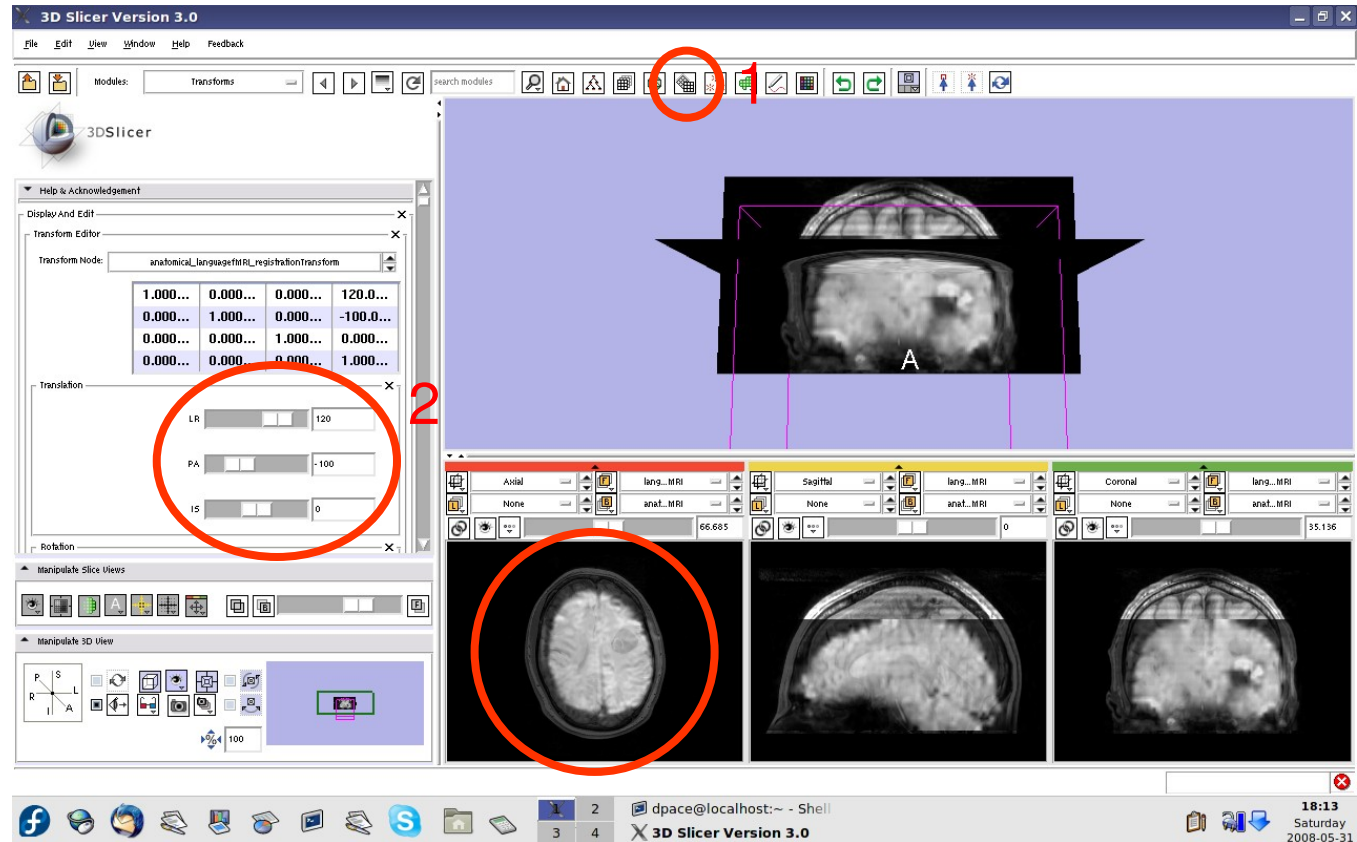




Initial manual transformation

Open the Transforms module

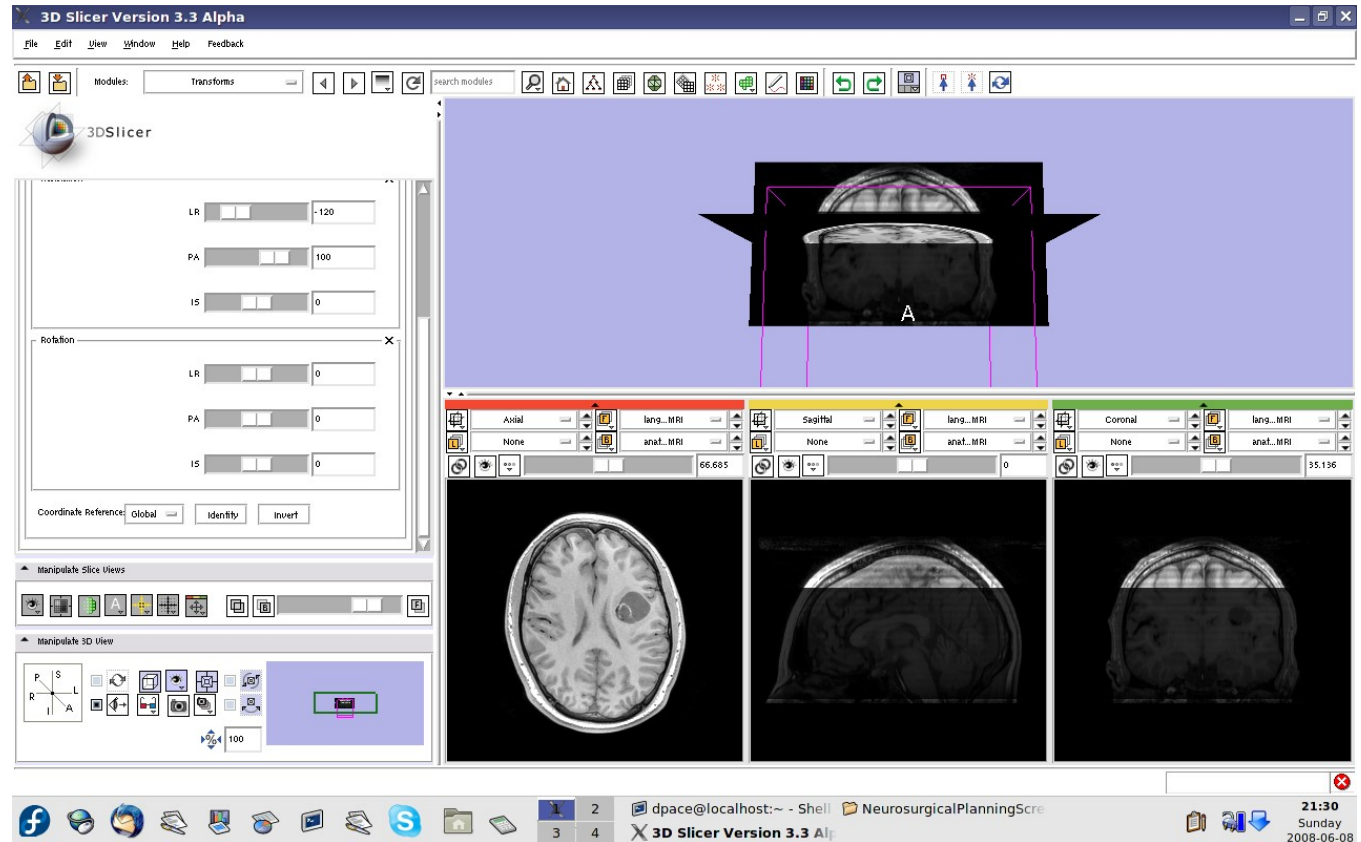
Adjust the translation components to roughly align the two image volumes in the **axial** plane





Initial manual transformation

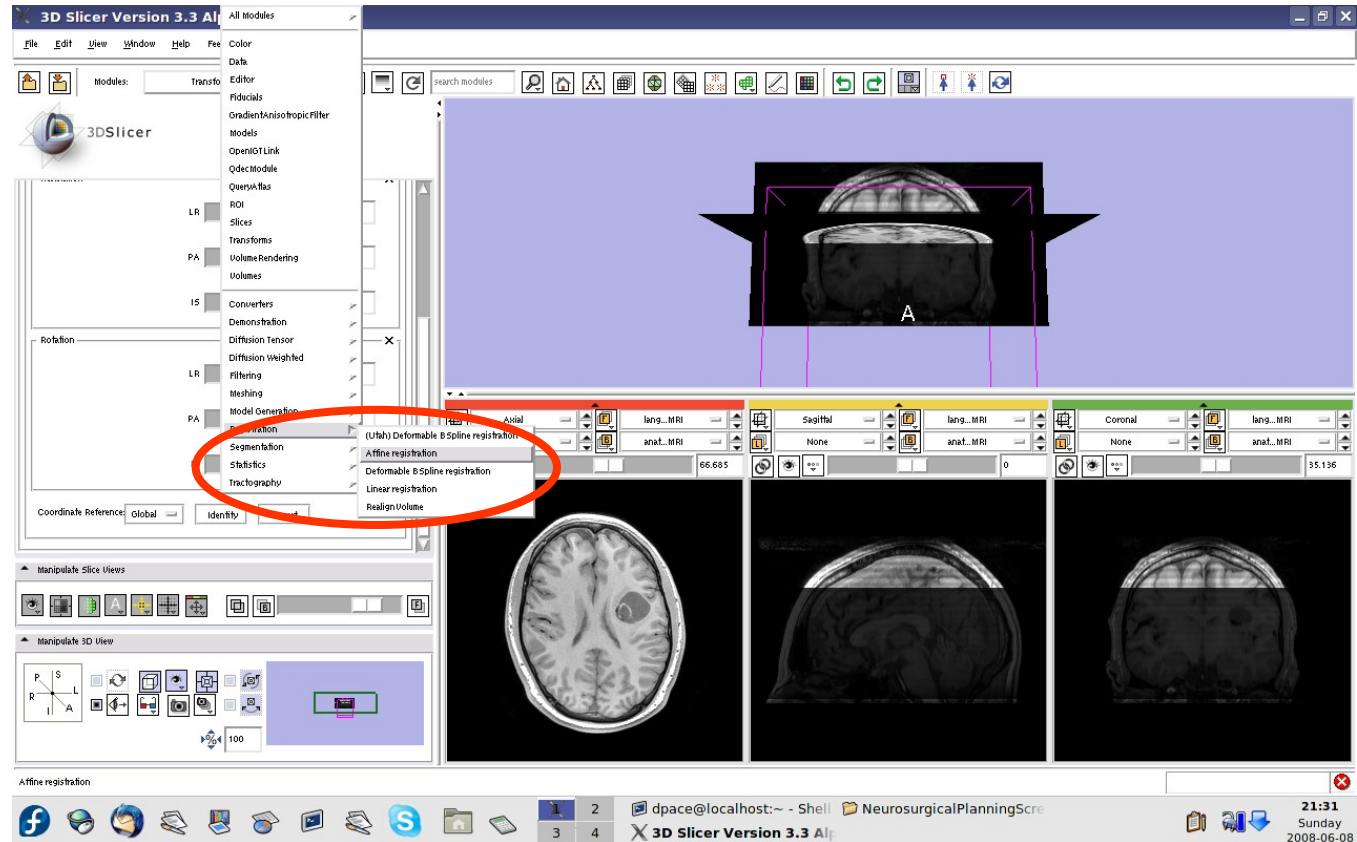
This initial transformation matrix “pushes” the language fMRI image onto the anatomical MRI image.





Automatic affine registration

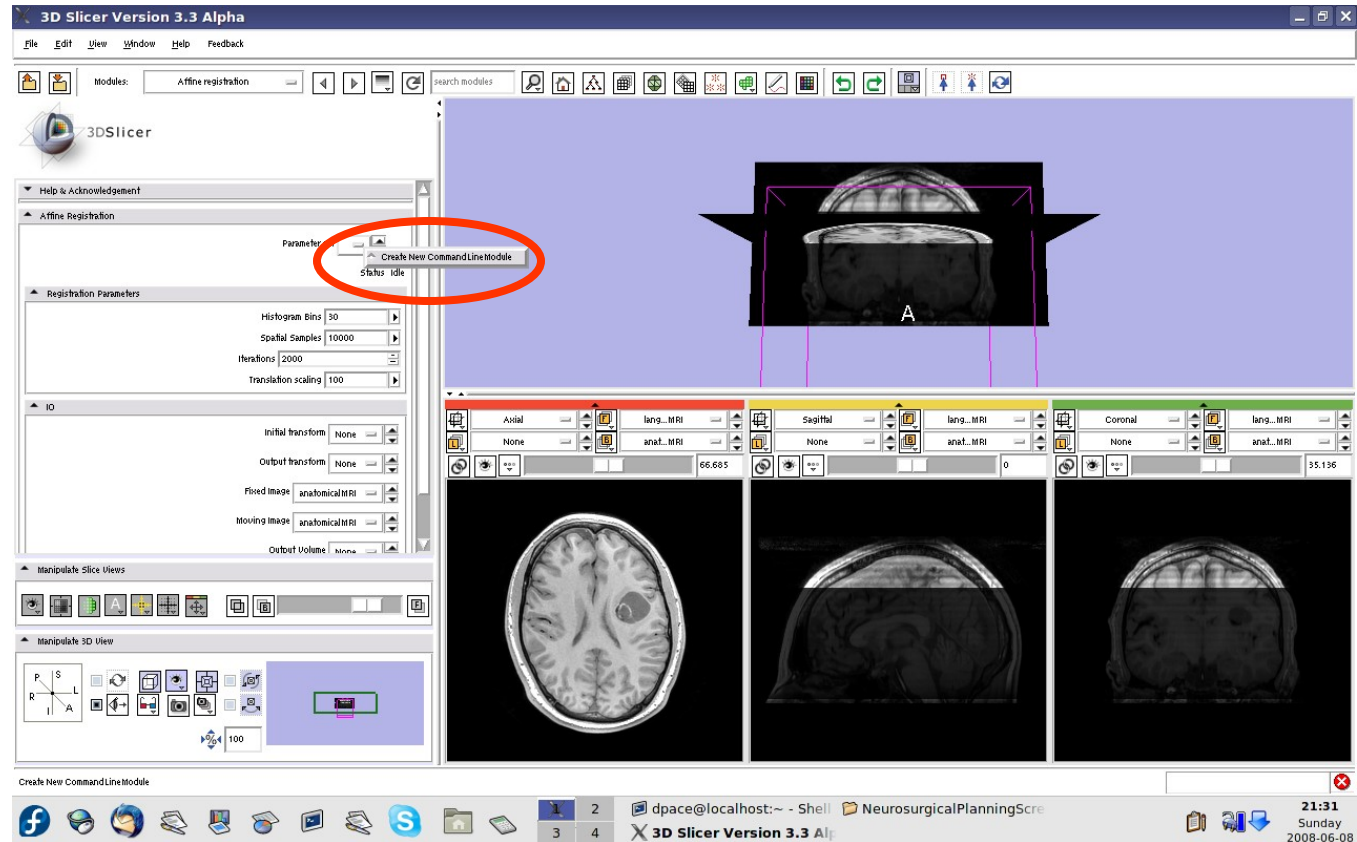
Open the
Affine
Registration
module





Automatic affine registration

Note that the Affine registration module supports multiple sets of parameters for repeated use. To create a new set, select “Create new CommandLineModule”

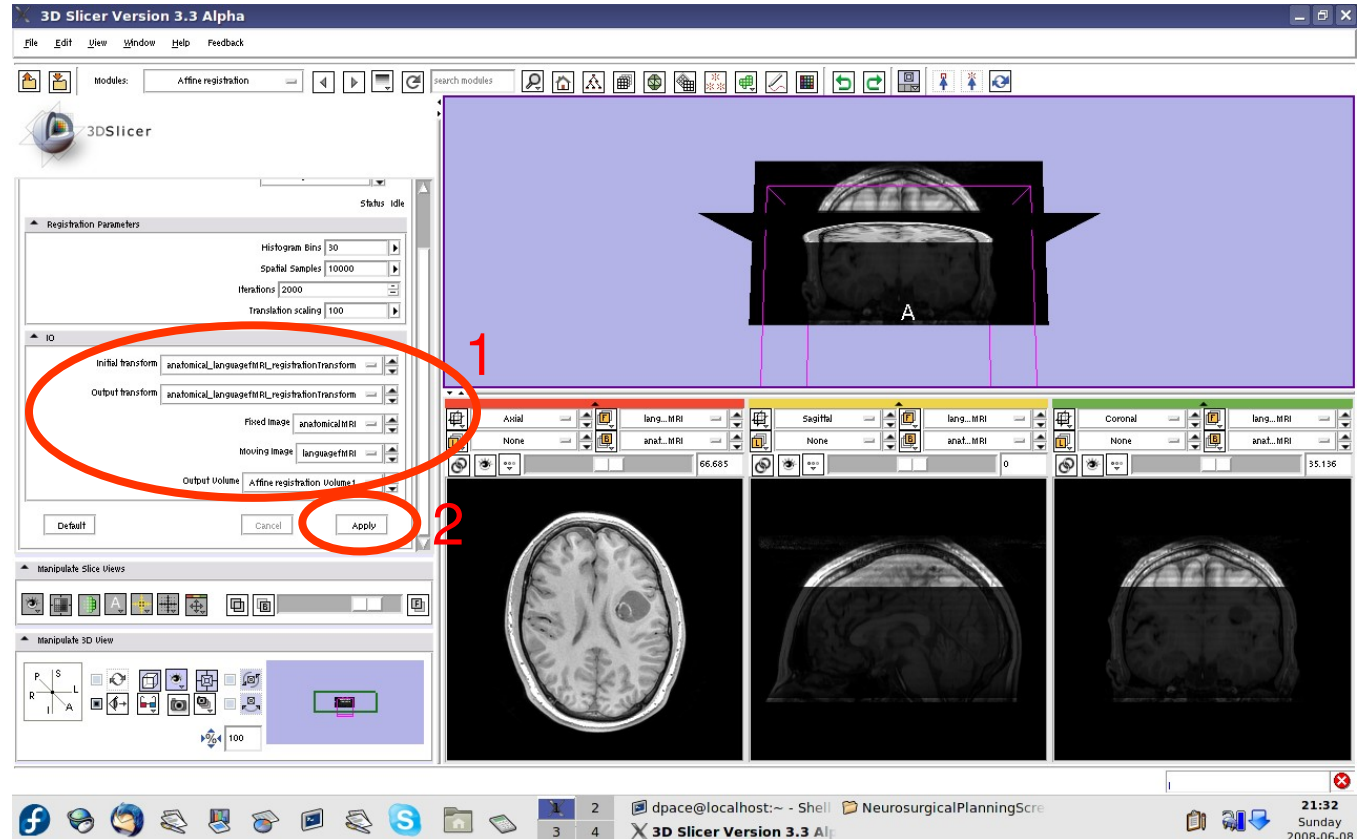




Automatic affine registration

- Initial transform = anatomical_language fMRI_registration Transform
- Output transform = anatomical_language fMRI_registration Transform
- Fixed Image = anatomicalMRI
- Moving Image = languagefMRI
- Output Volume = Create New Volume

Click “Apply”

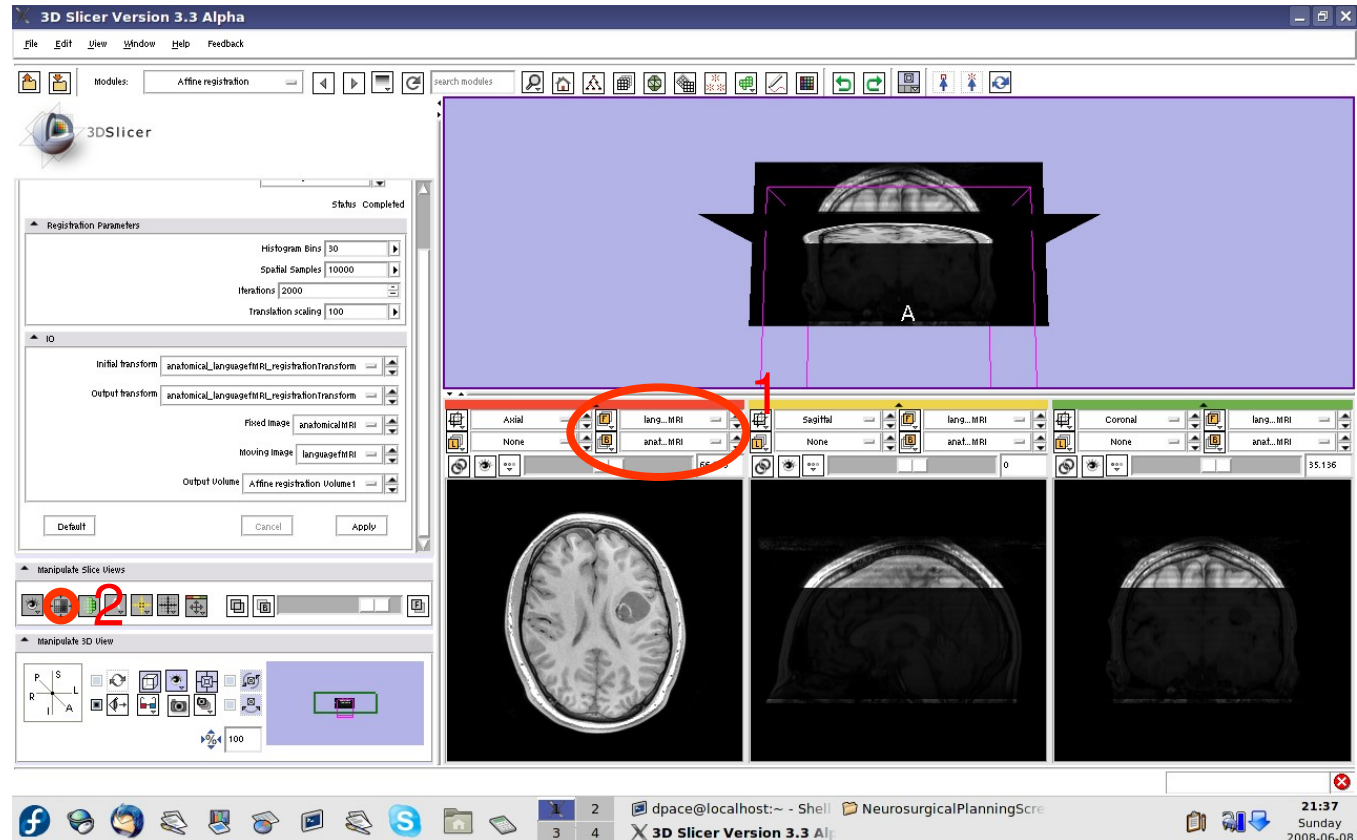




Automatic affine registration

Set the foreground to languagefMRI, and the background to anatomicalMRI

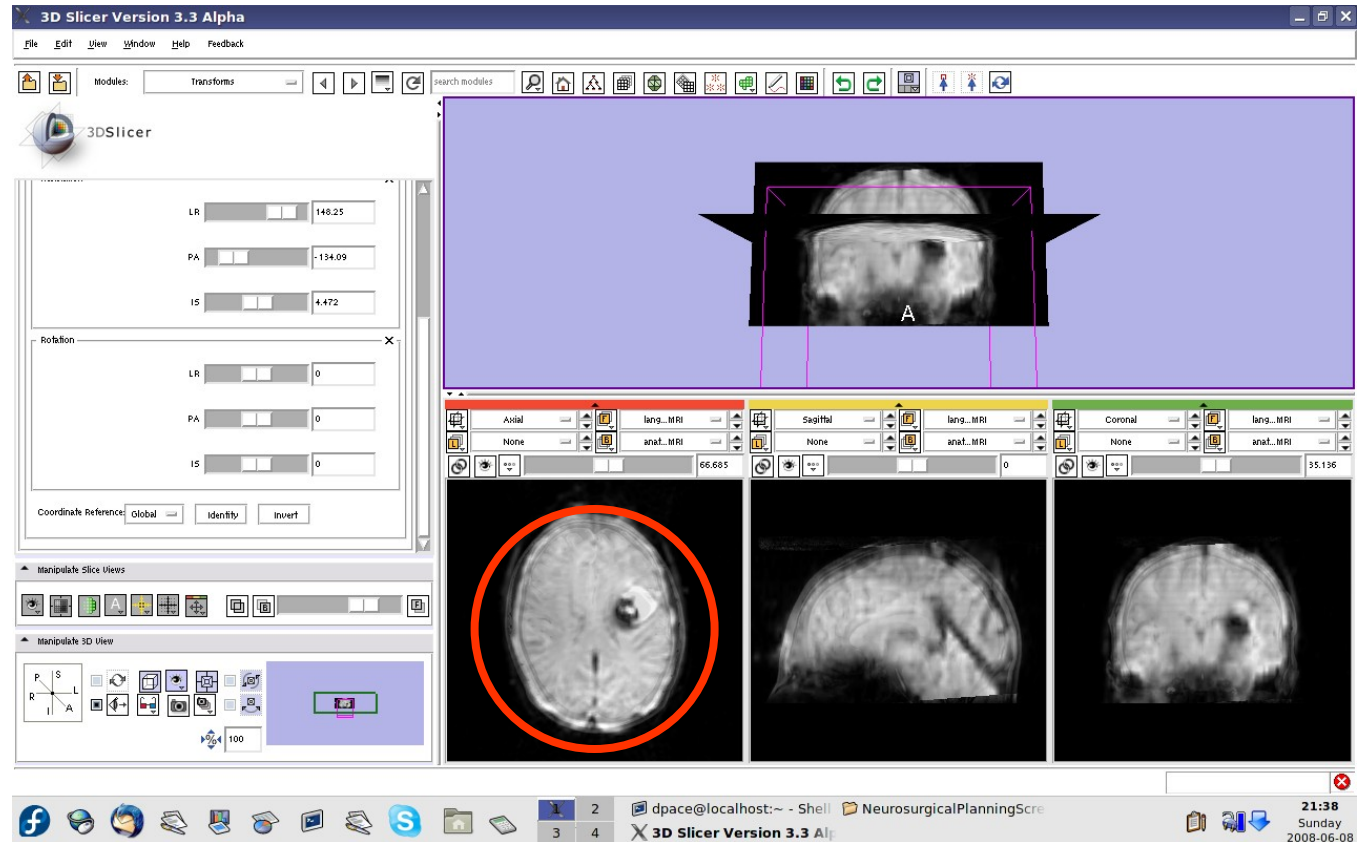
Click on the “fit to window” button





Automatic affine registration

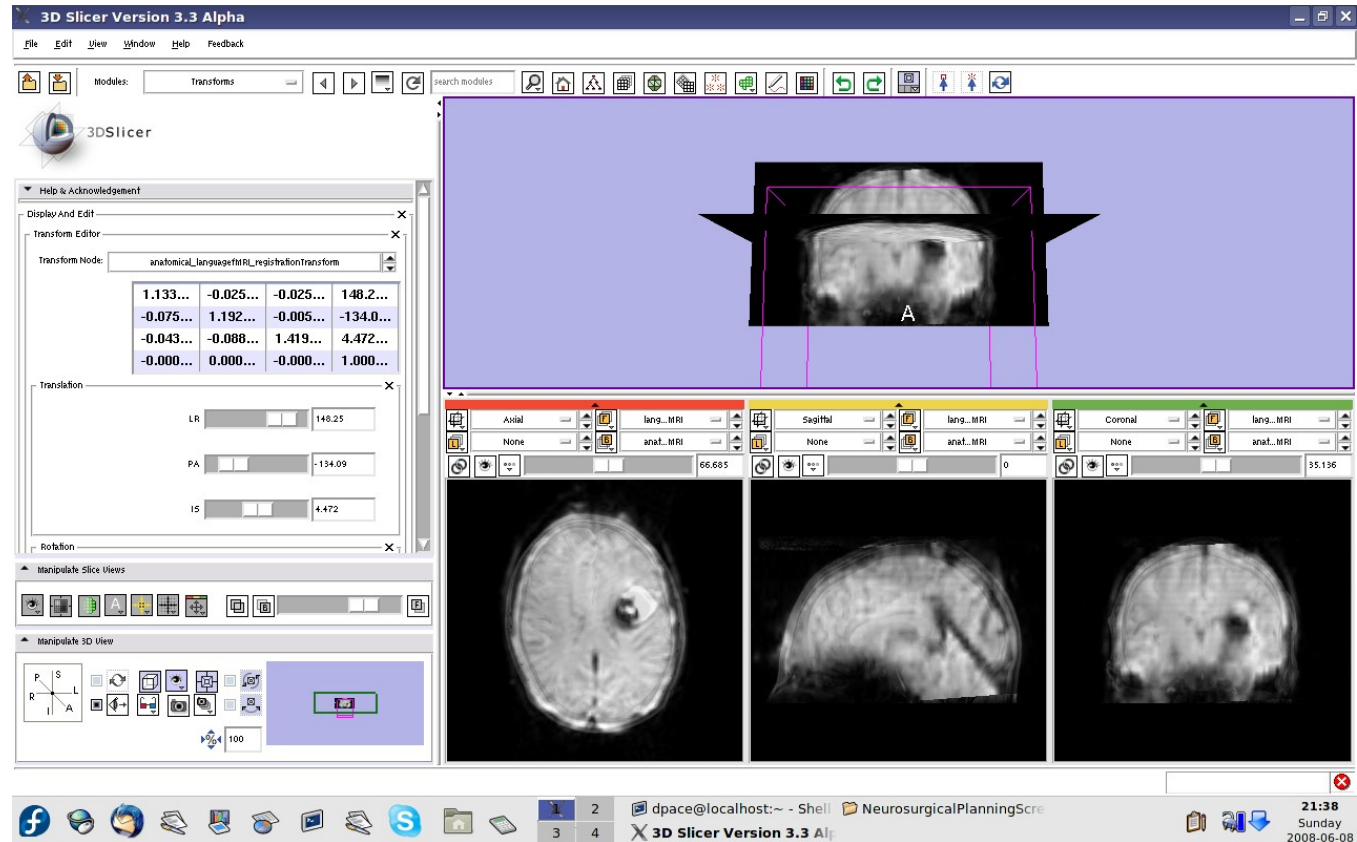
The transform now sets the moving image (languagefMRI) in alignment with the fixed image (anatomical MRI)





Automatic affine registration

Click on the transform node to see that the matrix has changed

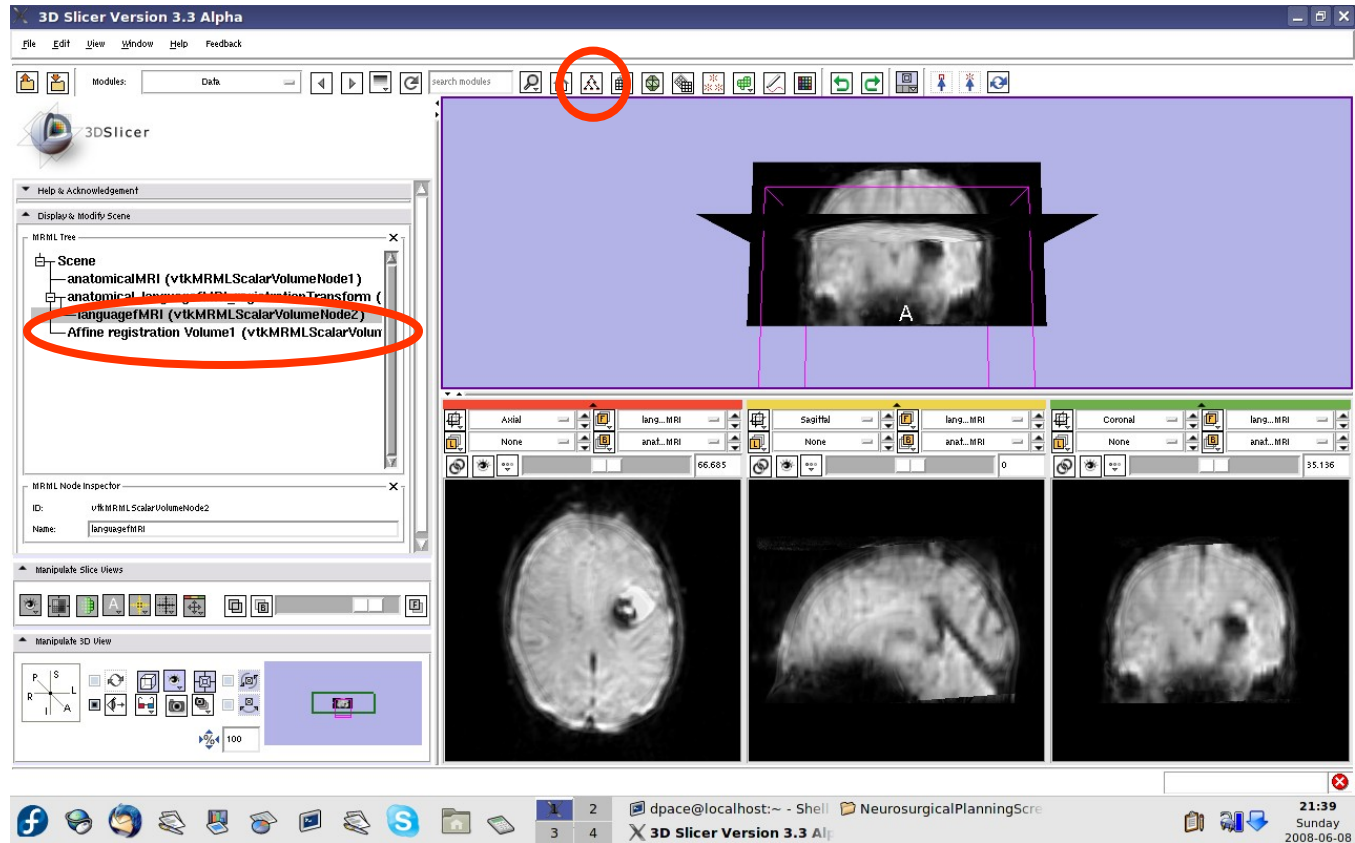




Automatic affine registration

Open the Data module

The new volume in the MRML scene is the **resampled** moving image (the language fMRI)

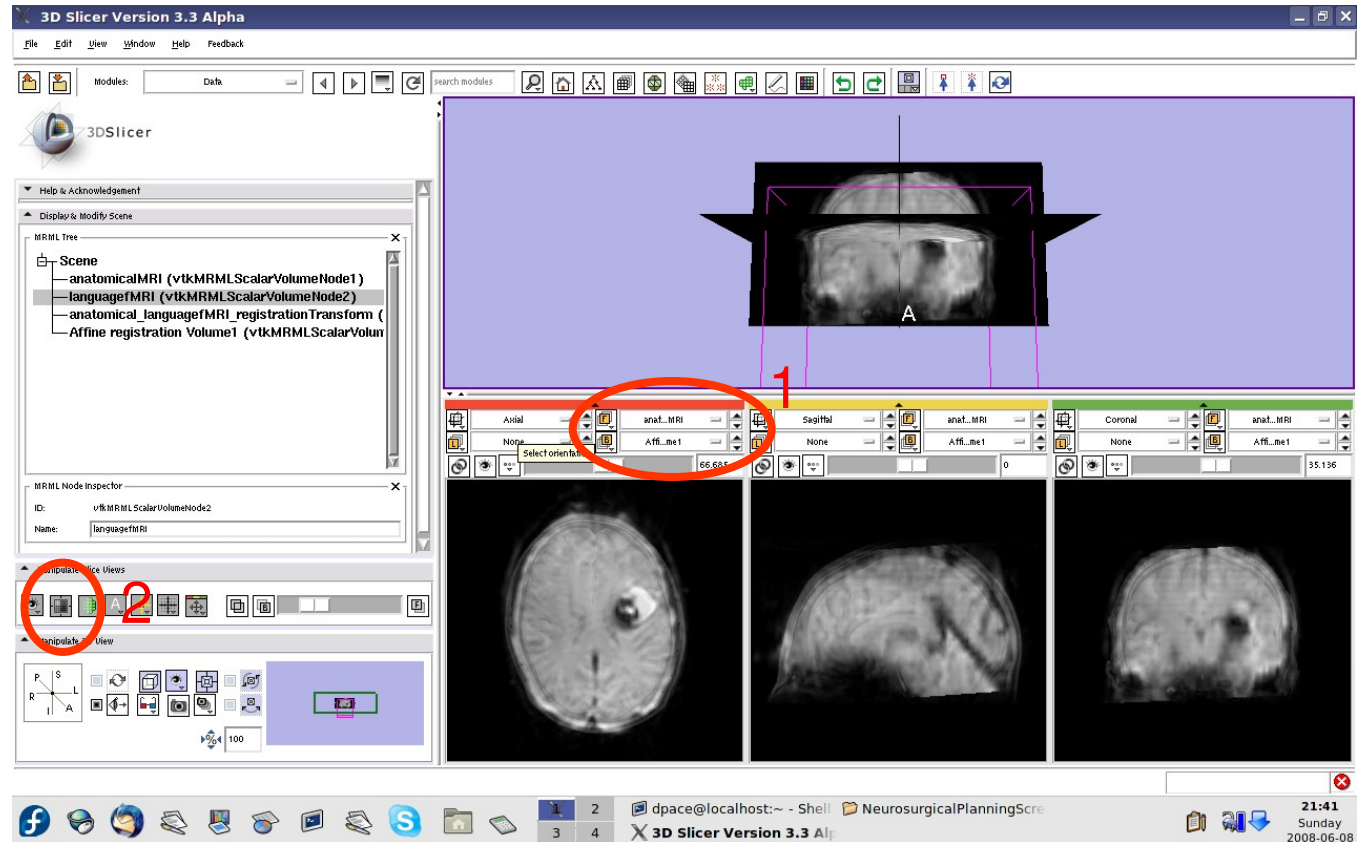




Automatic affine registration

Set the foreground to anatomical MRI and the background to Affine registration Volume1

Click on the “fit to window” button

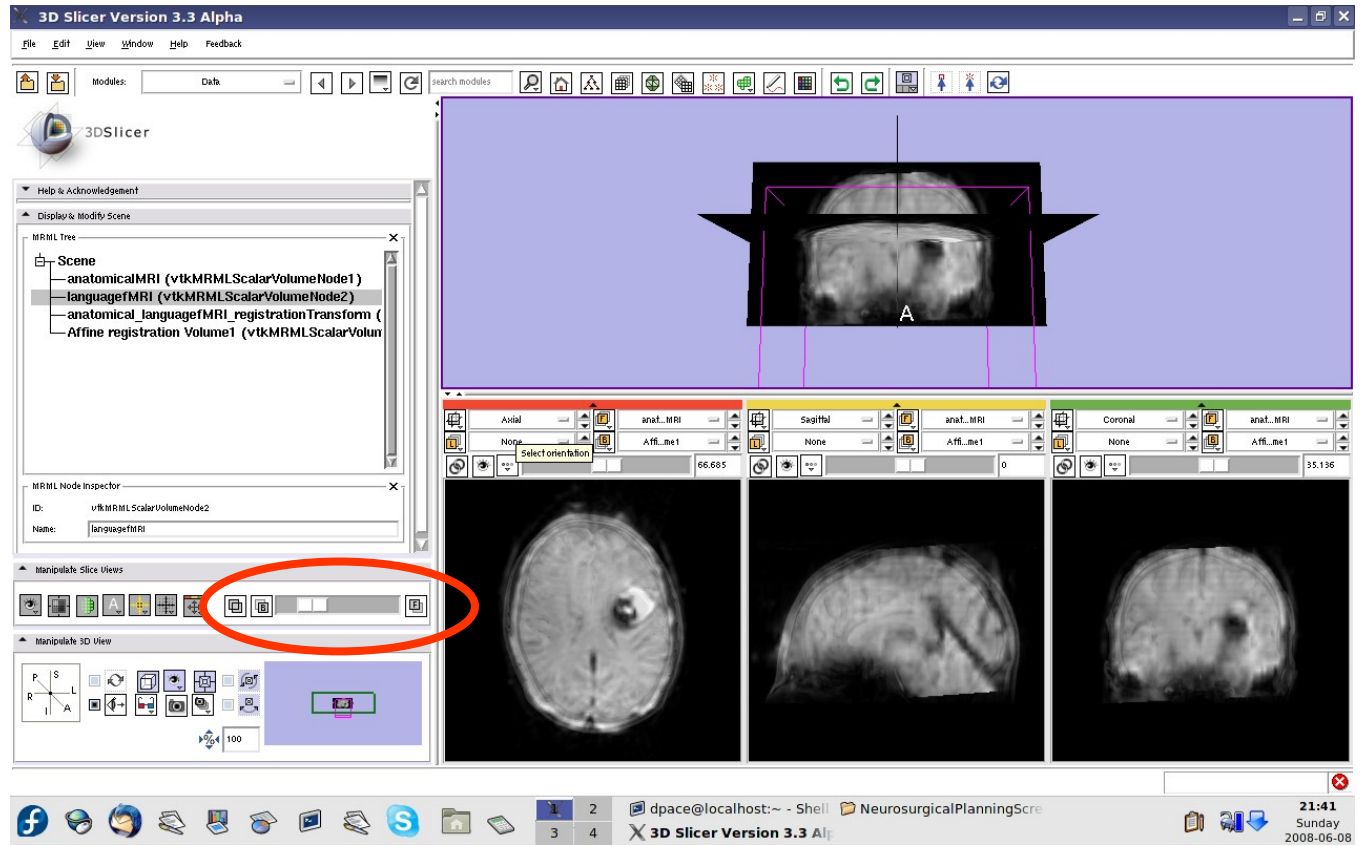




Automatic affine registration

Scale the opacities to see that the images are aligned

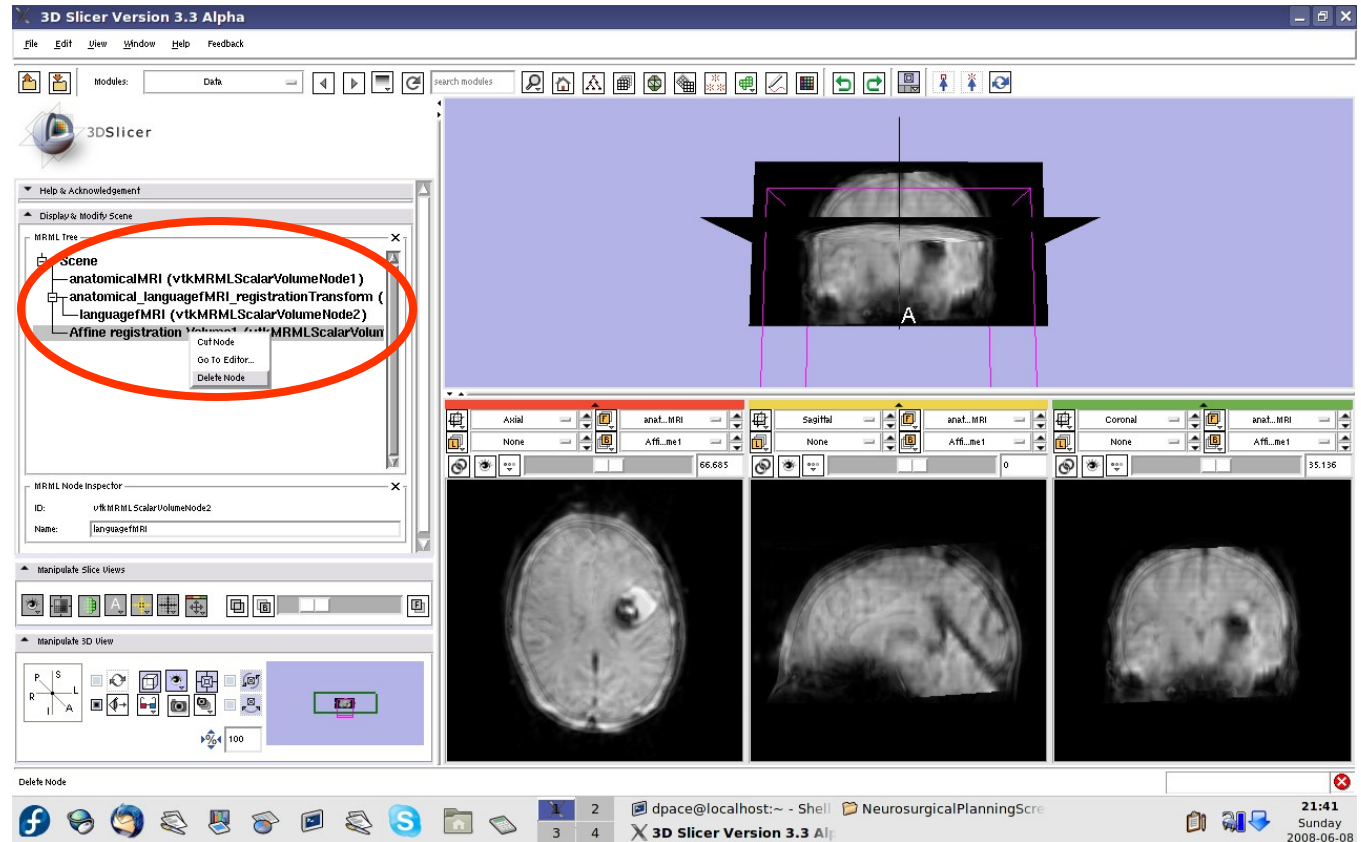
The new image is the moving image (language fMRI) transformed and resampled to align with the fixed image (anatomical MRI)





Automatic affine registration

Right-click on the Affine registration Volume1 node and select "Delete node"





Threshold image intensity

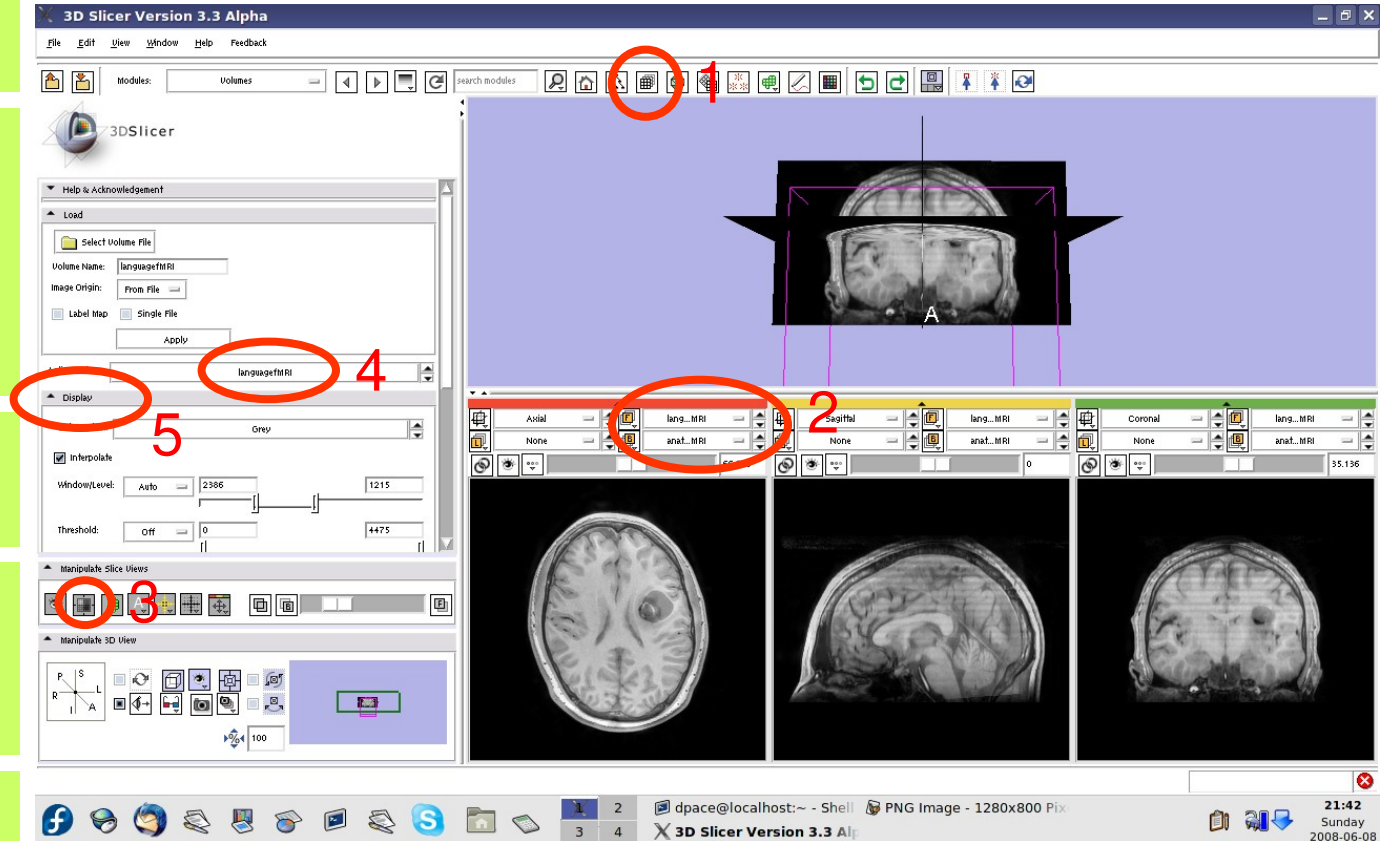
Open the Volumes module

Set the foreground to languagefMRI, and the background to anatomicalMRI

Click on the “fit to window” button

Set the active volume to languagefMRI

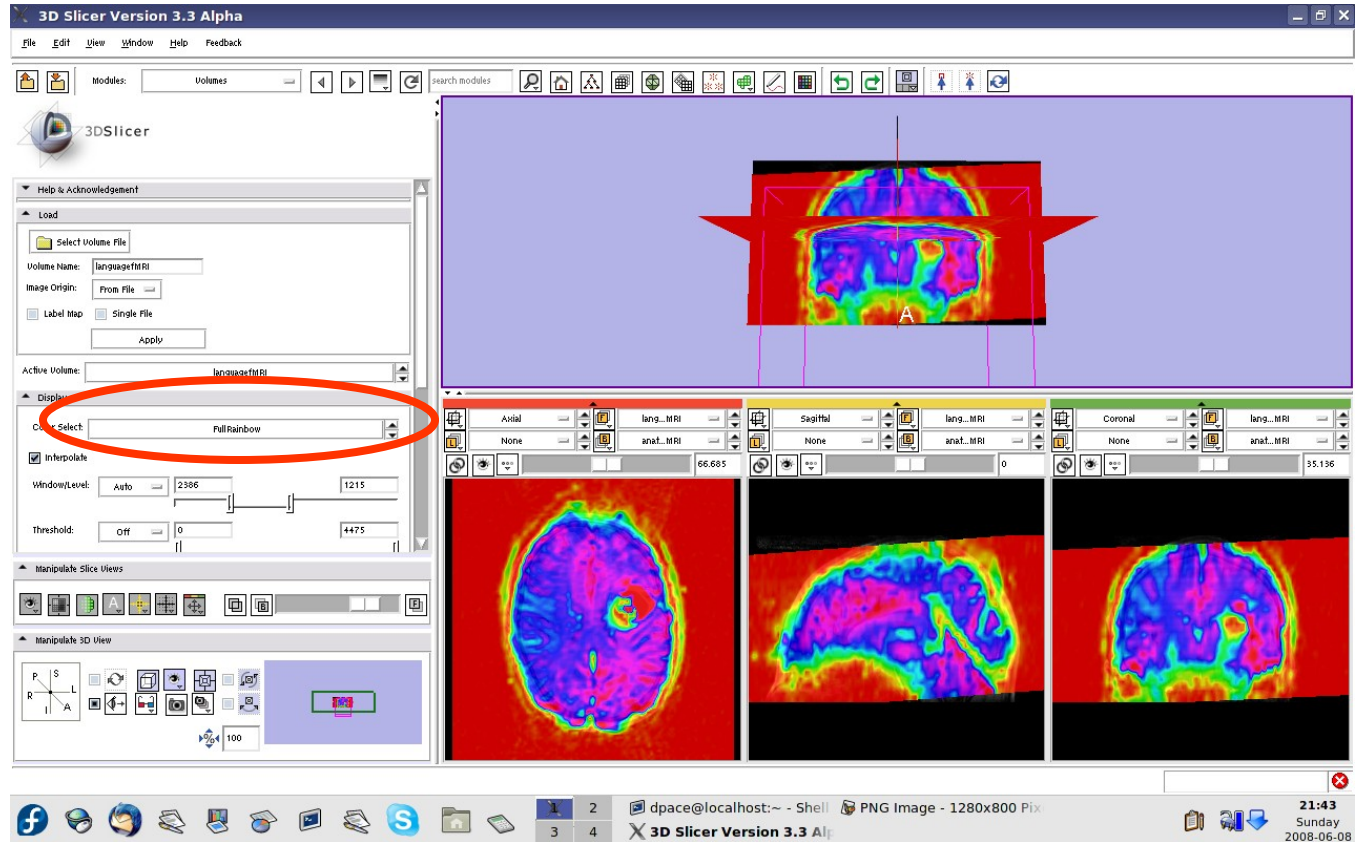
Expand the Display pane





Threshold image intensity

Set the Color to FullRainbow

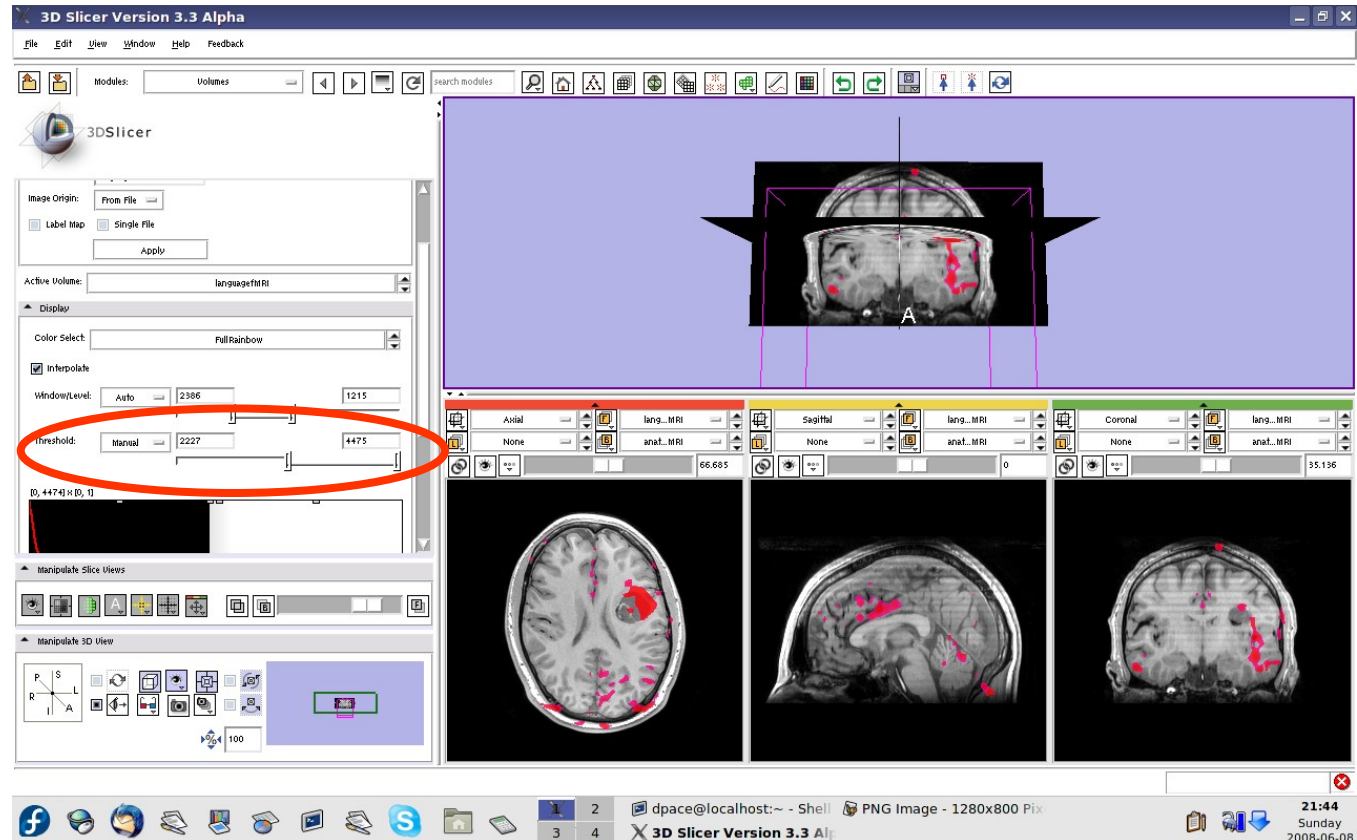




Threshold image intensity

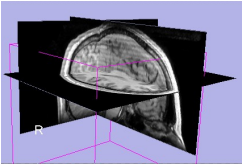
Set the threshold to Manual and adjust to highlight only high-intensity regions

Note that there are speech activation regions close to the tumour

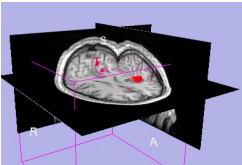




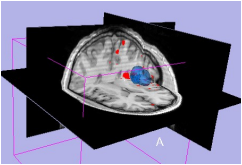
Overview



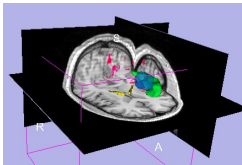
1. Loading and visualizing anatomical MRI data



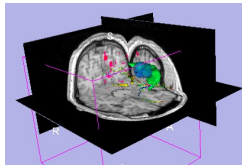
1. Incorporating fMRI data using image registration and thresholding



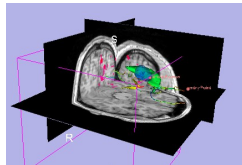
1. **Creating a 3D model of the tumour volume**



1. Predicting the locations of brain structures using image registration and a brain atlas



1. Incorporating brain fiber tractography from diffusion weighted images



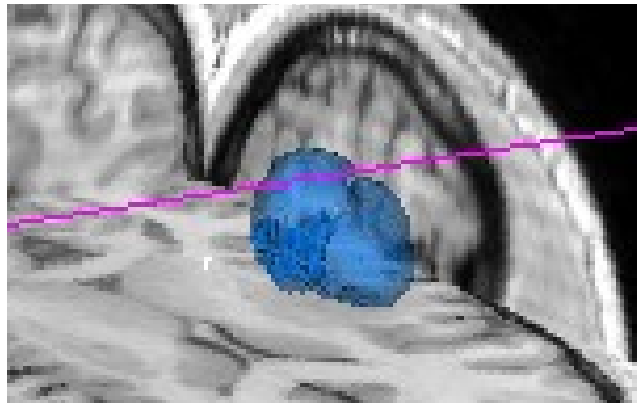
1. Annotating the preoperative plan and saving the scene



Model Making in Slicer3

- **Utility of model making in IGT:**

- View the structure as a complete unit (instead of slice by slice)
- Perform measurements, such as volume measurements, that can be difficult to perform on the image volume itself





Model Making in Slicer3

- **Steps involved in this section:**

Place a seed point on the tumour in the anatomical MRI

Segment the tumour volume in the anatomical MRI

Create the tumour model using Slicer3's ModelMaker

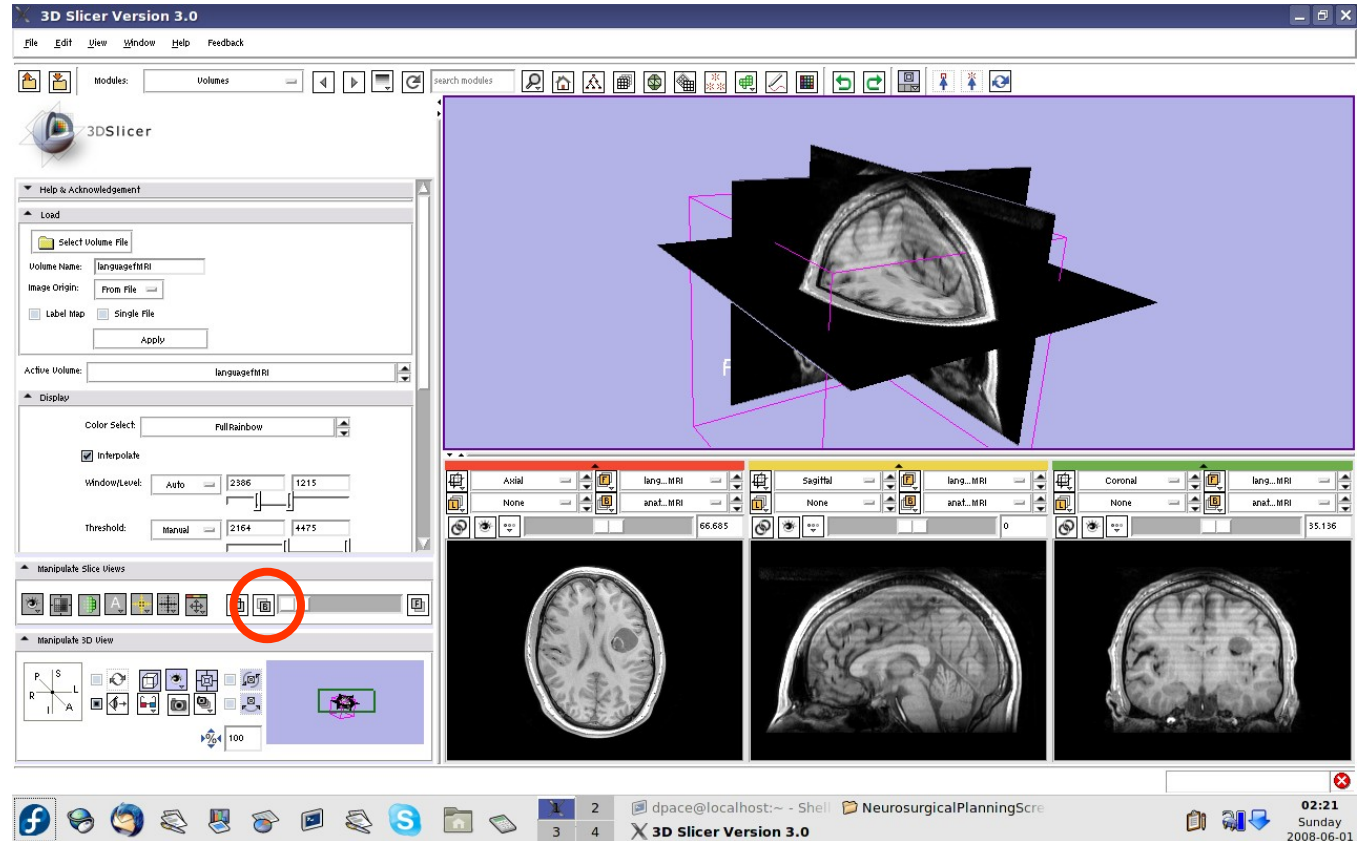
Change the tumour model's appearance

Save the tumour model



Place the seed point

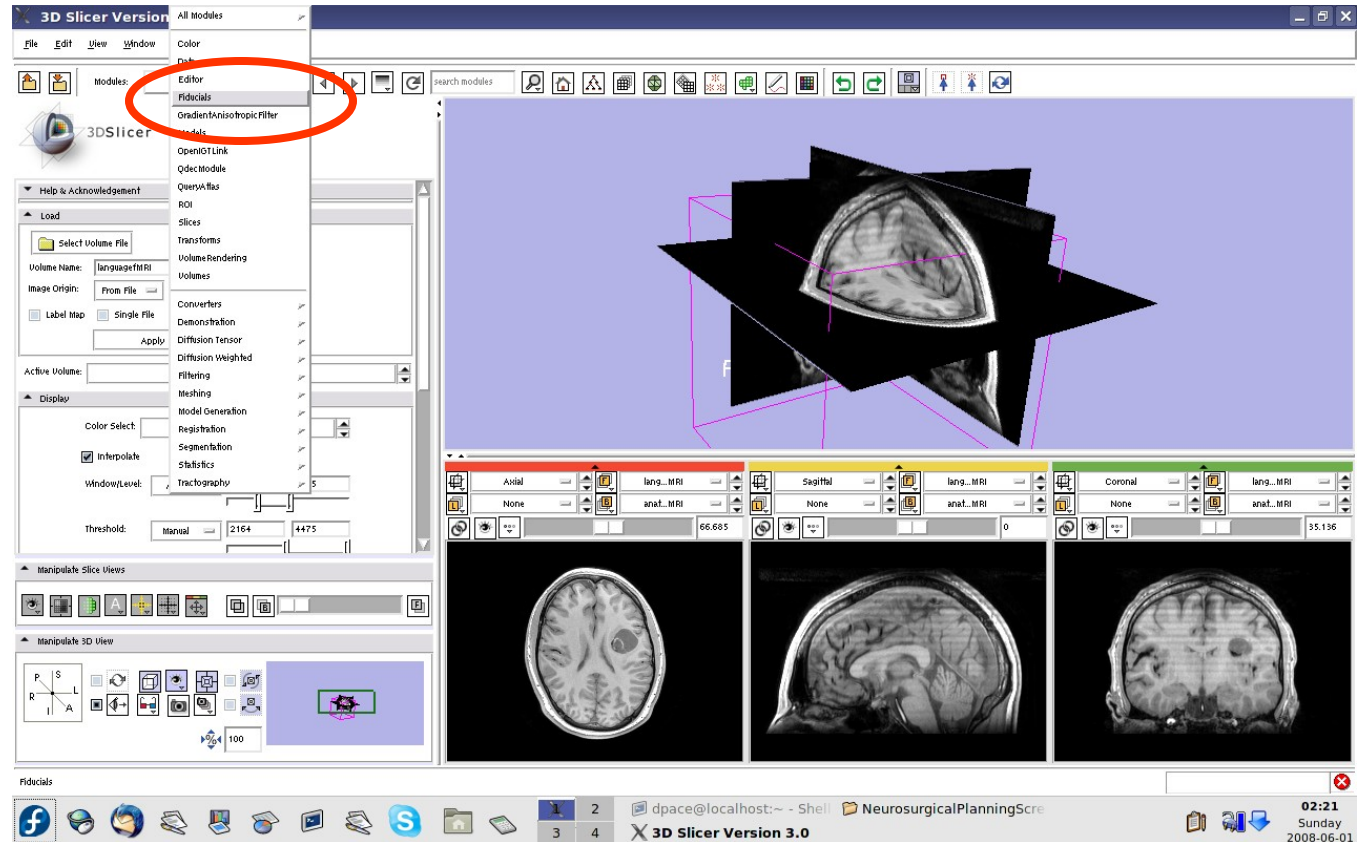
Click on the Background layer button to show the anatomical MRI alone





Place the seed point

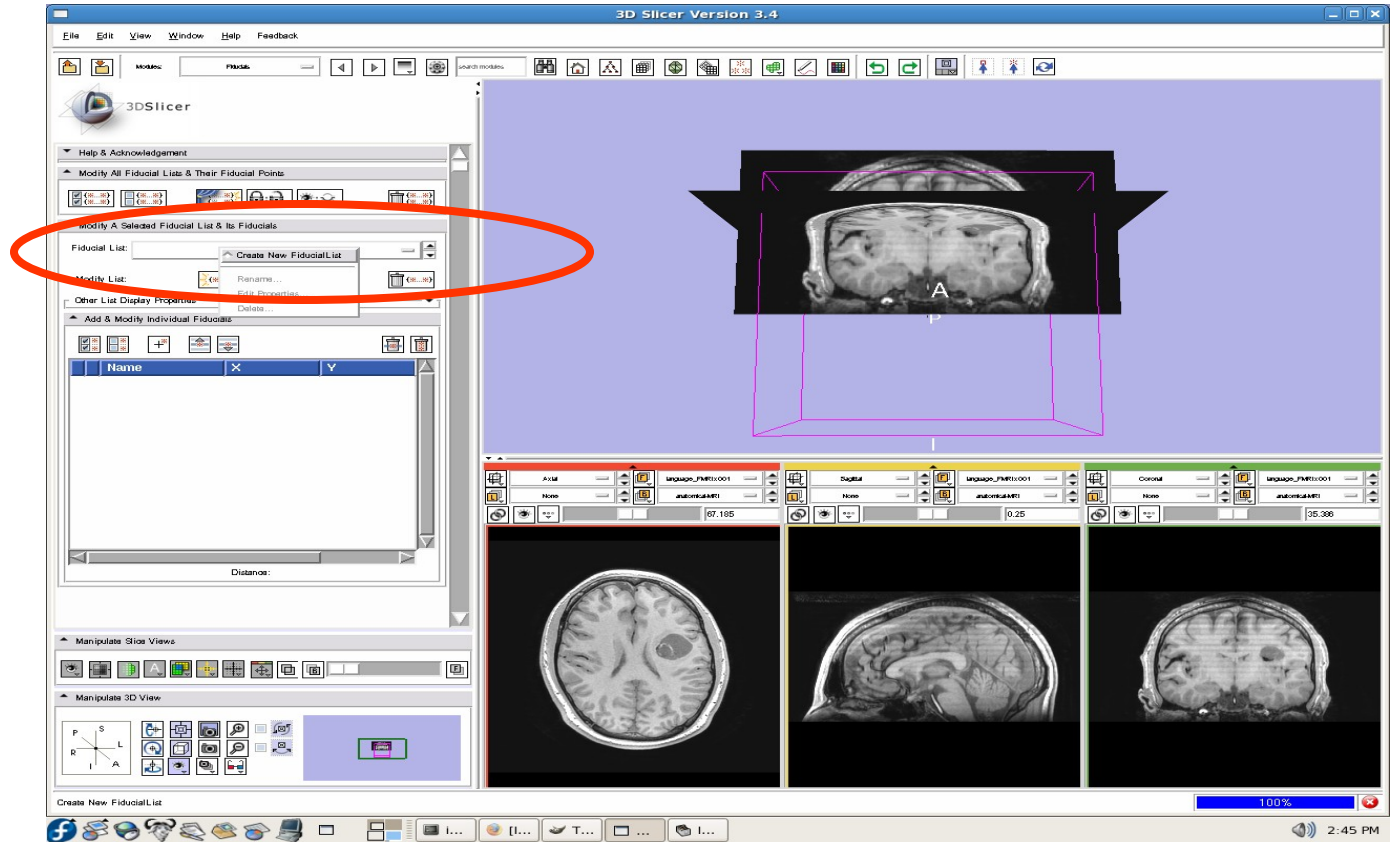
Open the Fiducials module





Place the seed point

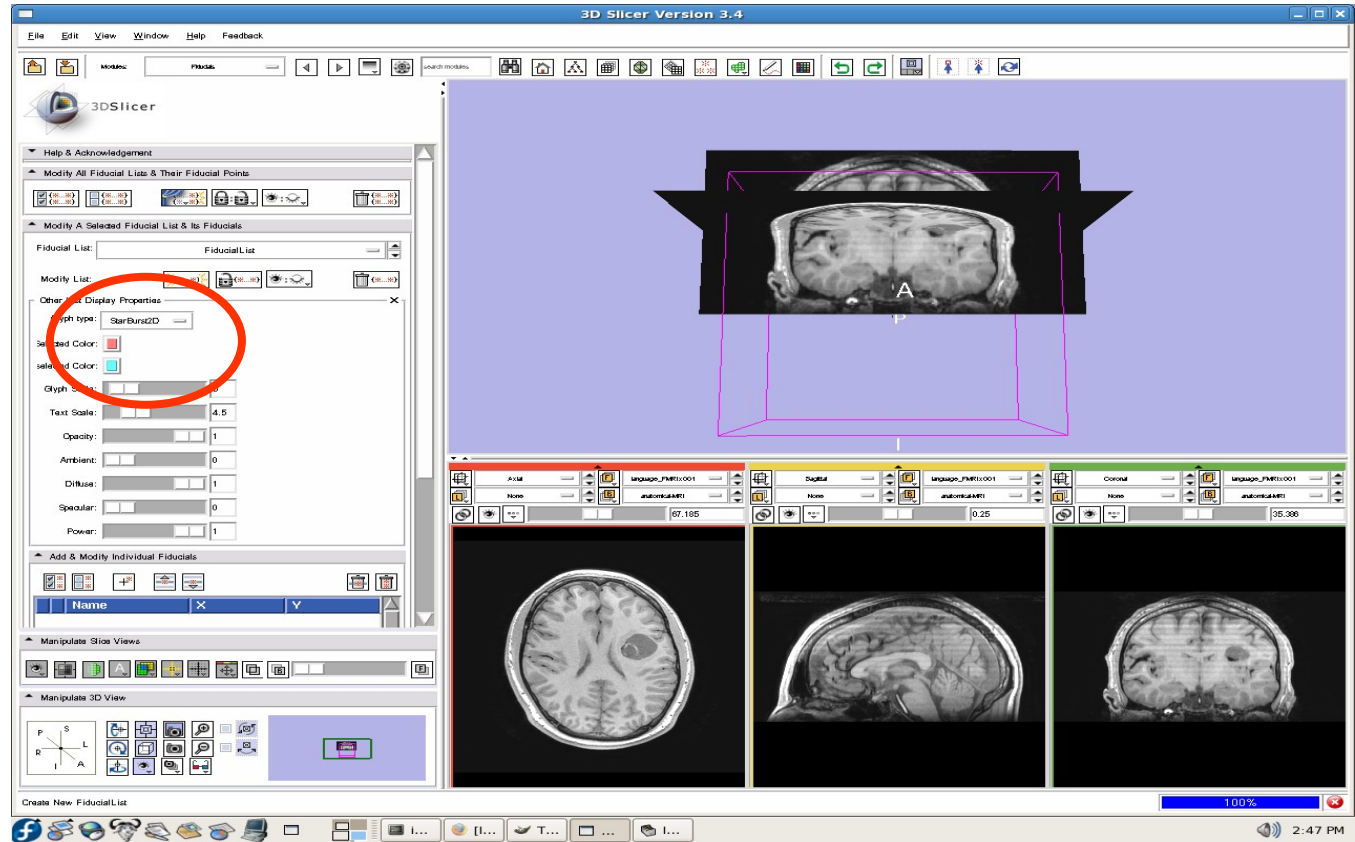
Create a new Fiducial List





Place the seed point

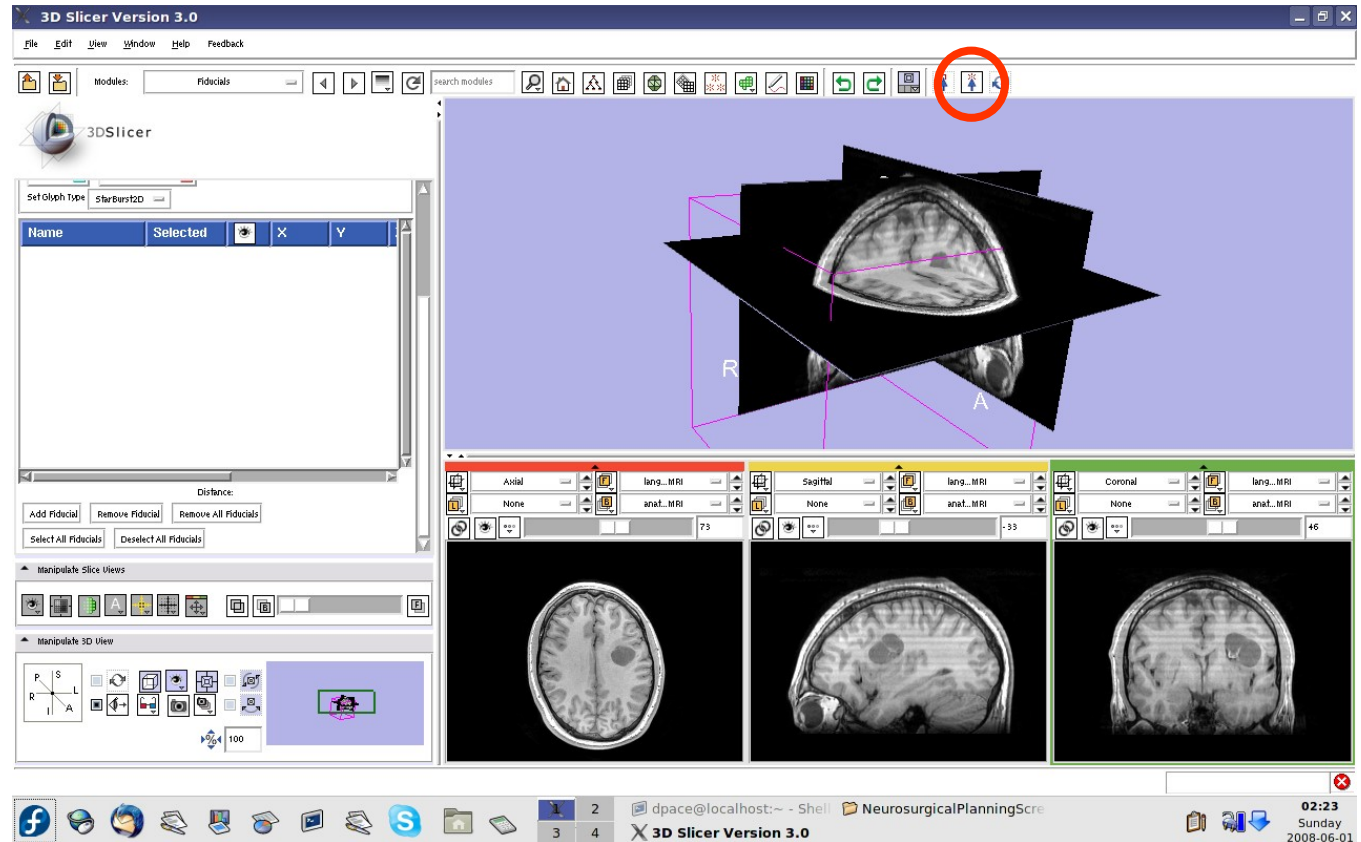
Expand
“Other
Display List
Properties.”
Controls
include
fiducial
color
(default:
pink), and
shape
(starburst)





Place the seed point

Set the mouse mode to “place items”

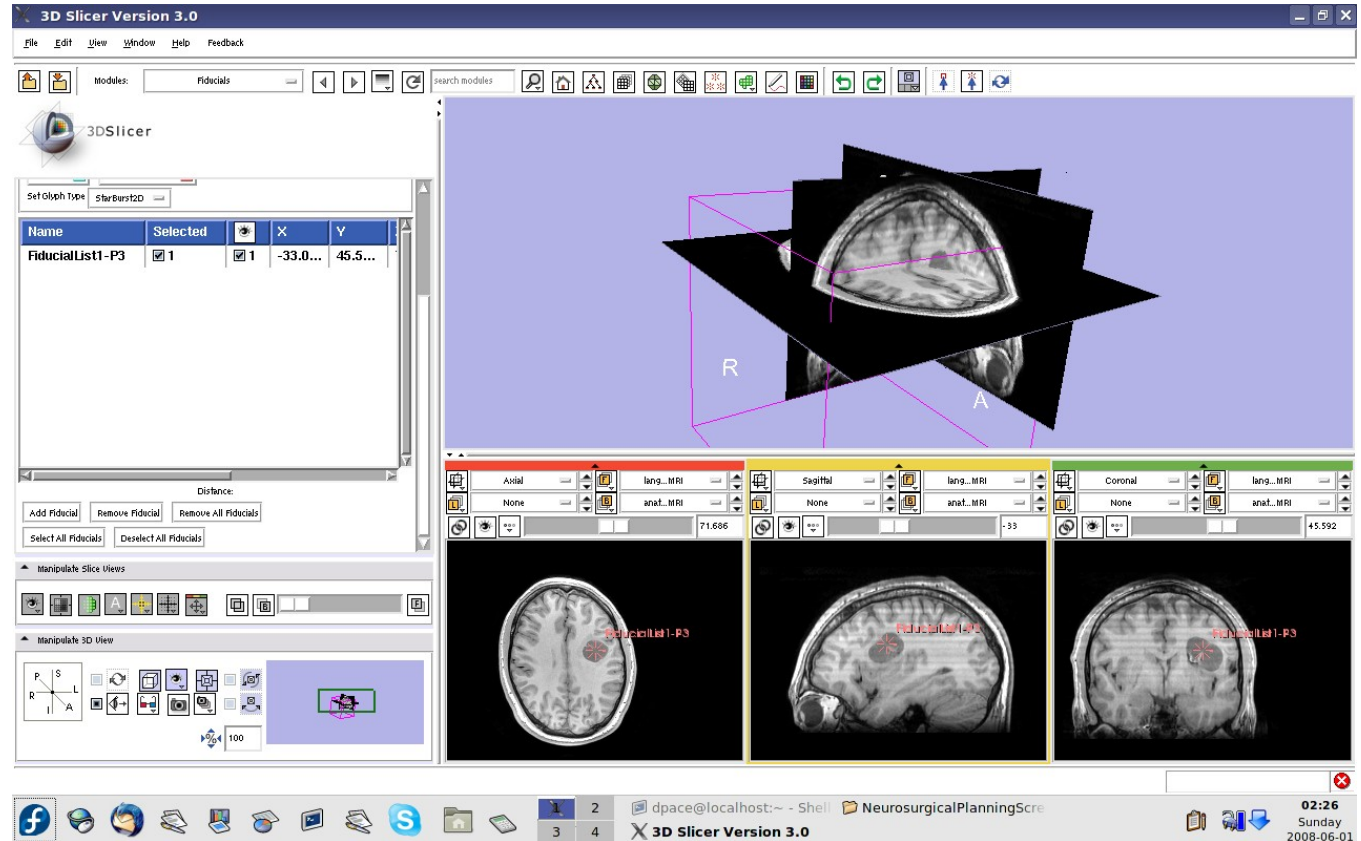




Place the seed point

Slice through the image volume until you see the tumour in all three views

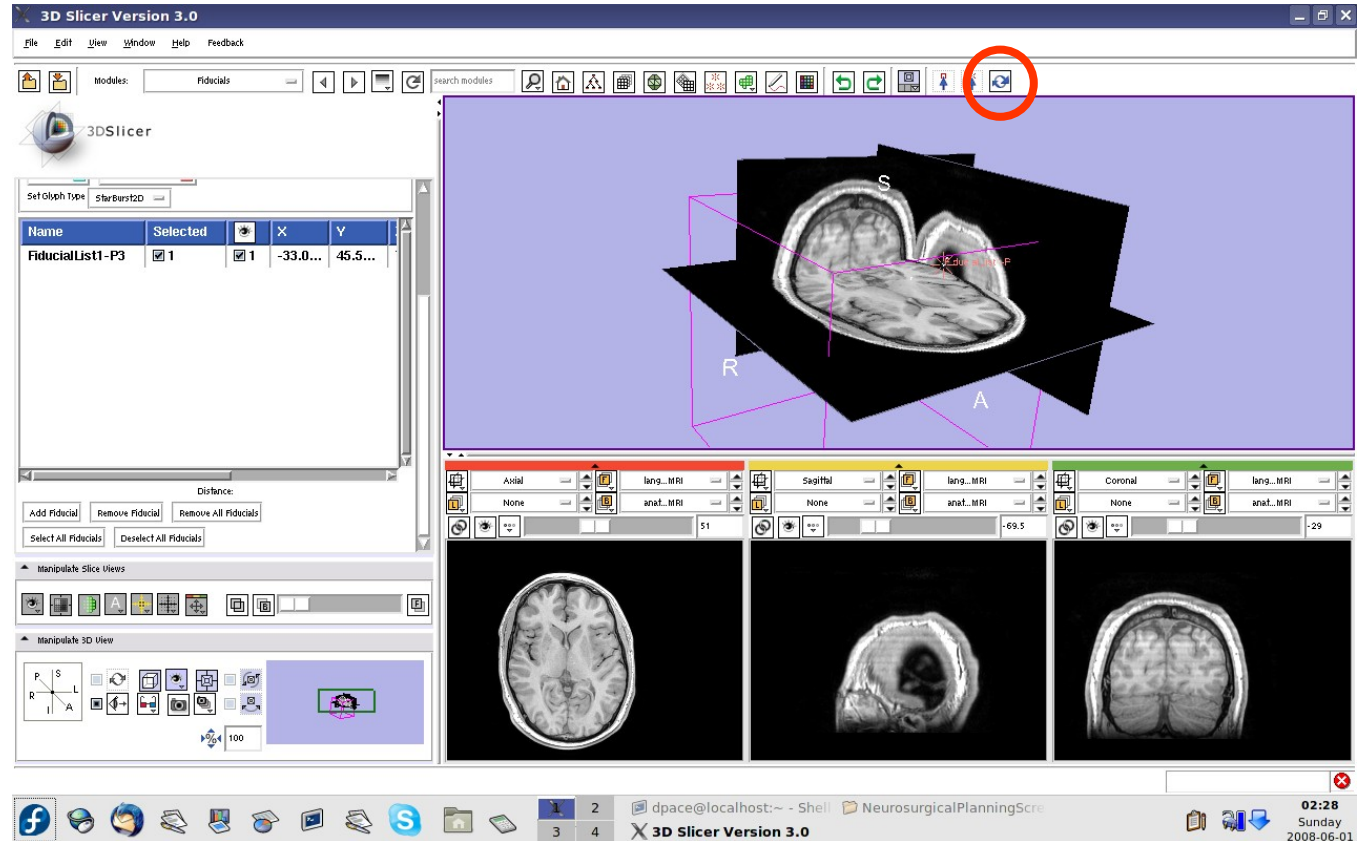
Click once to place the seed





Place the seed point

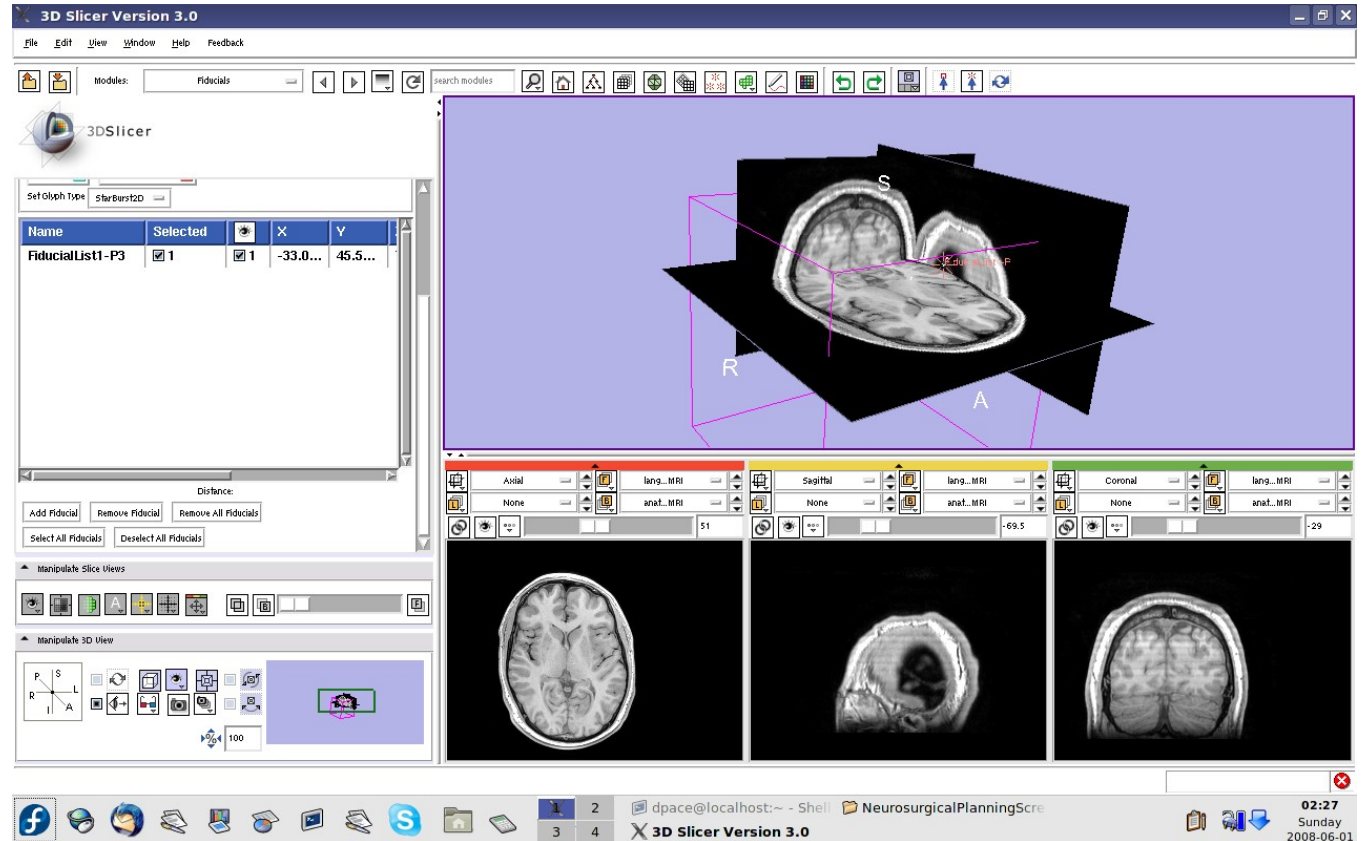
Set the mouse mode to “transform view”





Place the seed point

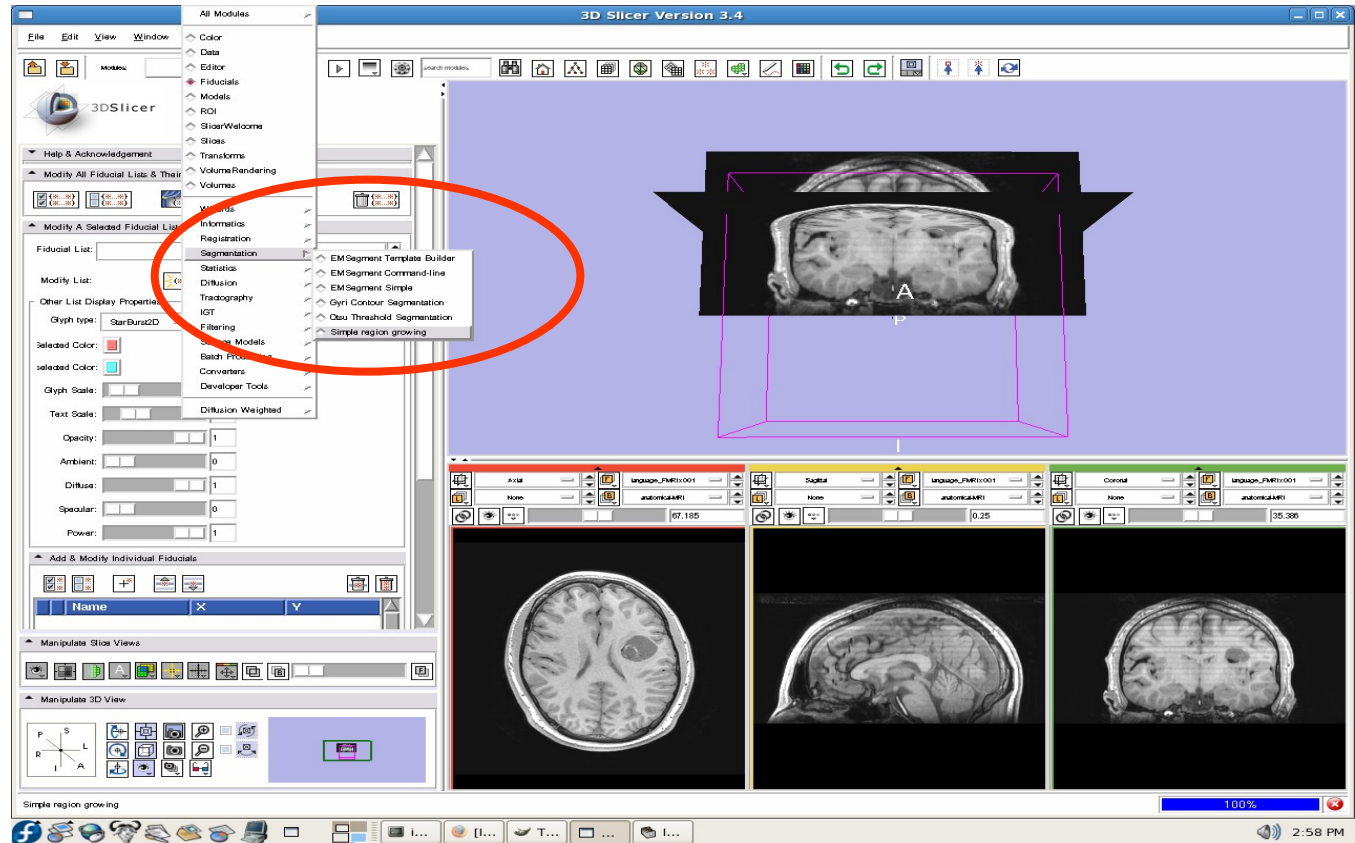
The fiducial can also be seen in the 3D Viewer





Segment the tumour volume

Open the
“Segmentation
-> Simple
Region
Growing”
module



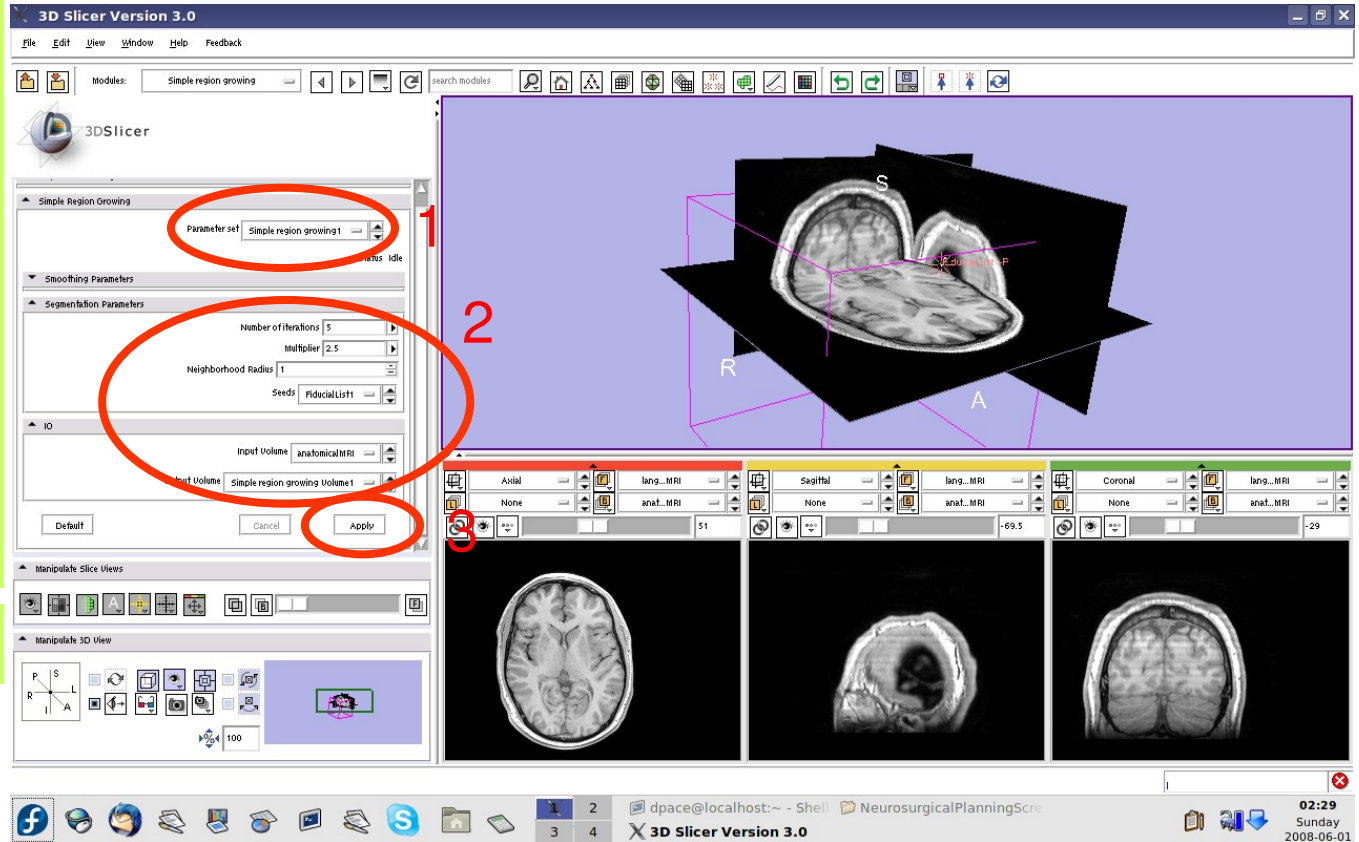


Segment the tumour volume

- Parameter set = Simple region growing
- # of iterations = 1
- Seeds = FiducialList1
- Input Volume = anatomicalMRI
- Output Volume = Create New Volume

Click “Apply”

This step may take a few minutes to run - wait until the status says “Completed”



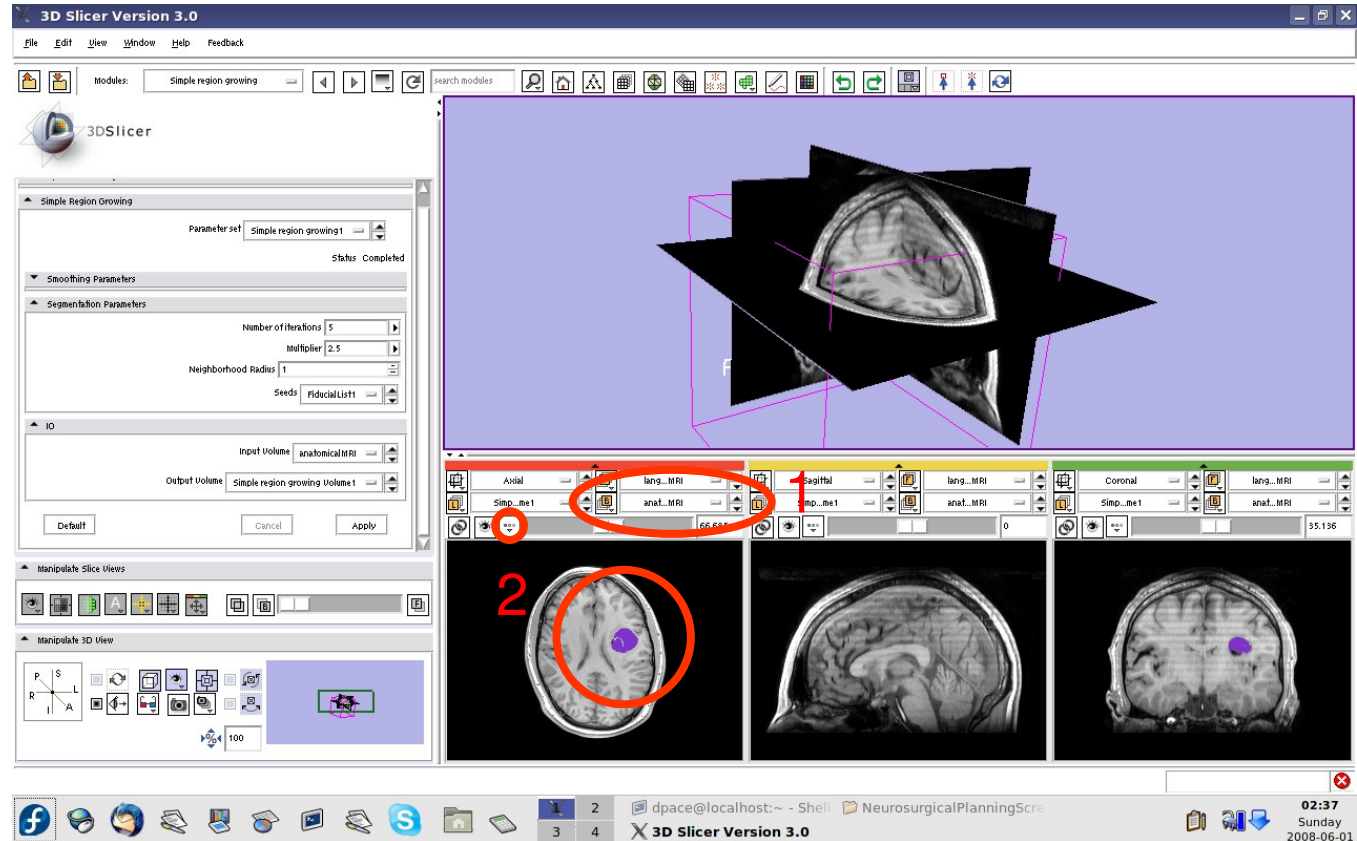


Segment the tumour volume

Set the background to anatomicalMRI

Click on the “fit to window” button

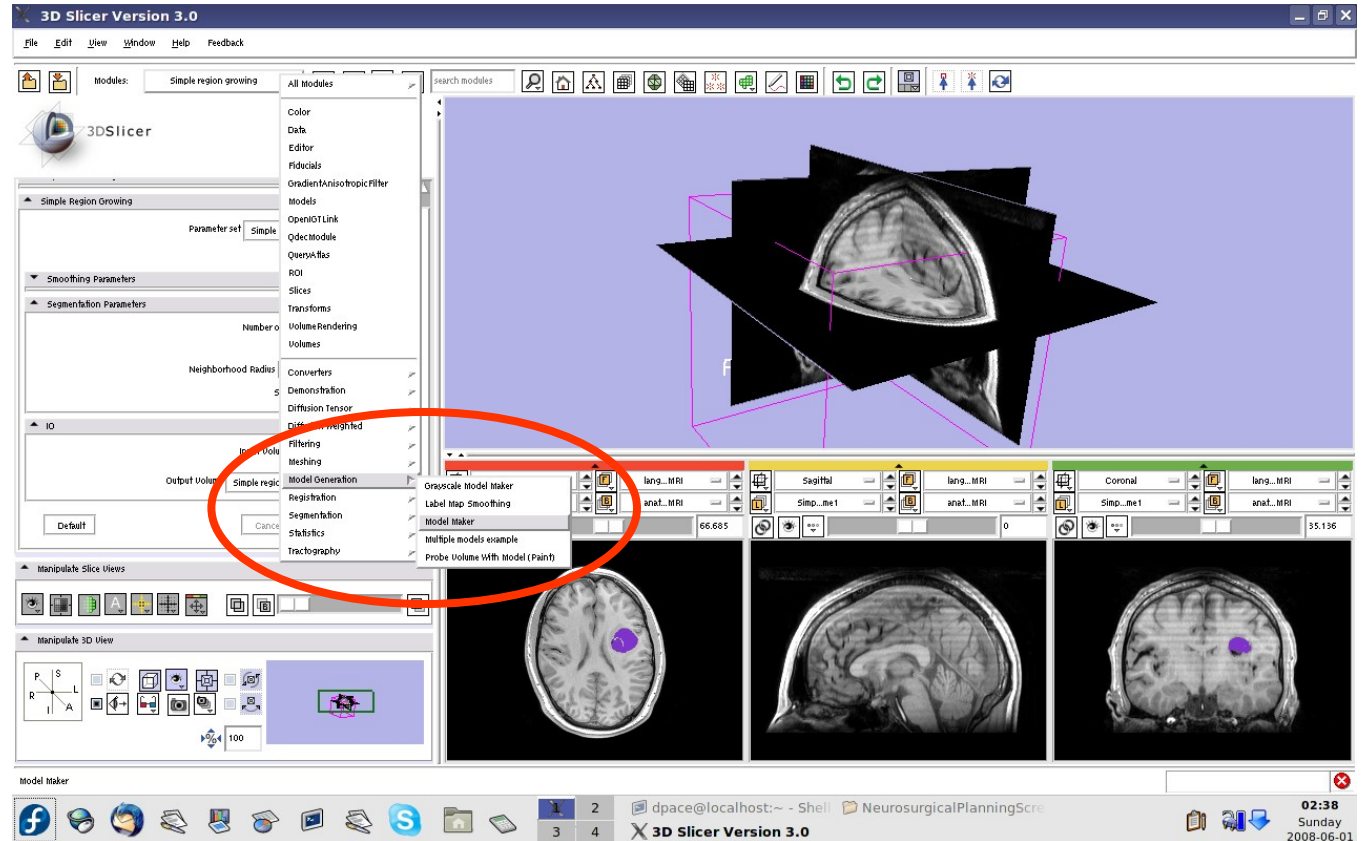
The tumour is segmented by the label layer called “Simple Region growing Volume1” (shown in purple)





Create the tumour model

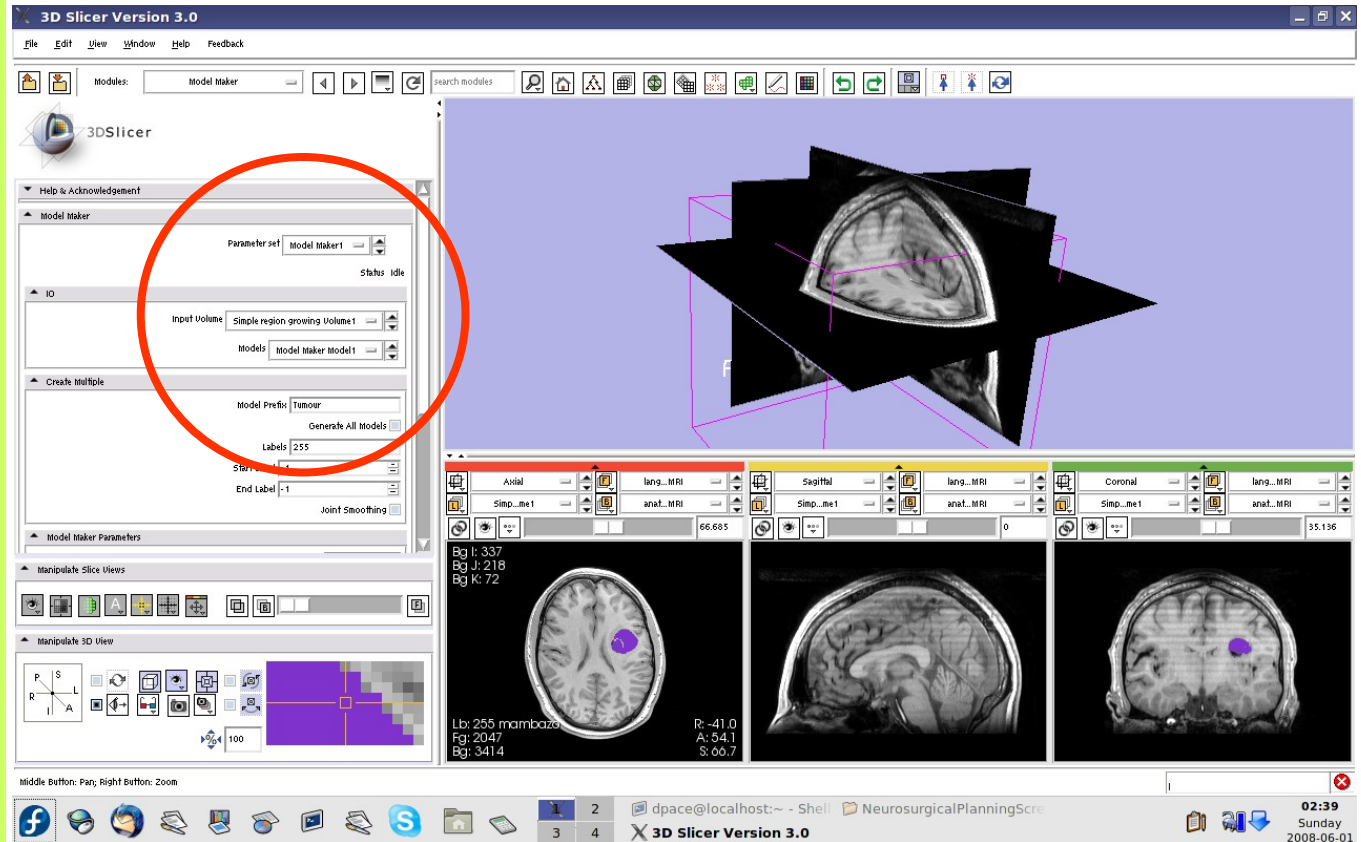
Open the Model Maker module





Create the tumour model

- Parameter set = Create new CommandLine Module
- Input Volume = Simple region growing Volume1
- Models = Create New ModelHierarchy
- Model Name = Tumour
- Labels = 255 (scroll over the purple tumour and note the “Lb” value)

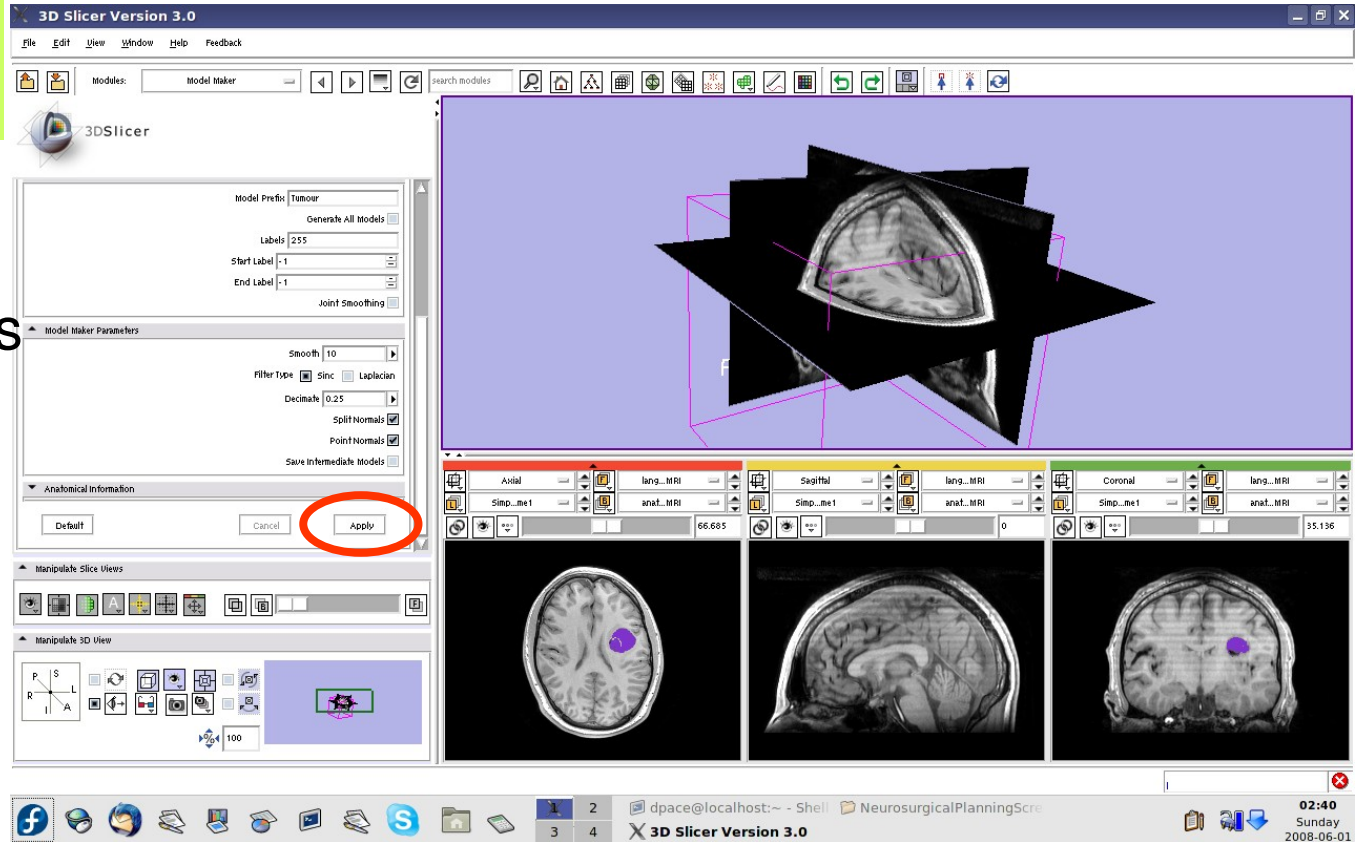




Create the tumour model

Click “Apply”

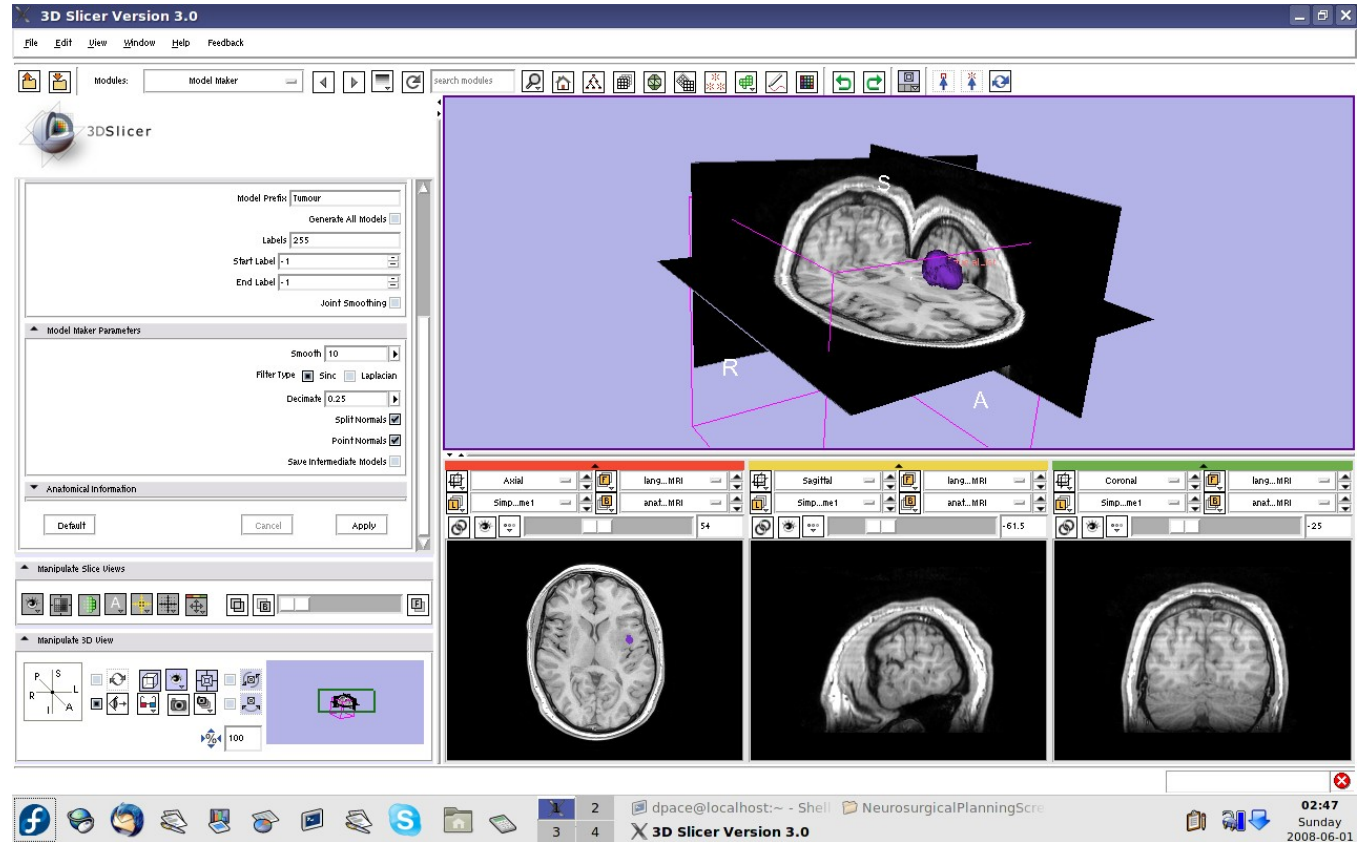
This step may take a few minutes to run - wait until the status says “Completed”





Create the tumour model

Slice through the image volume to expose the tumour model in the 3D Viewer

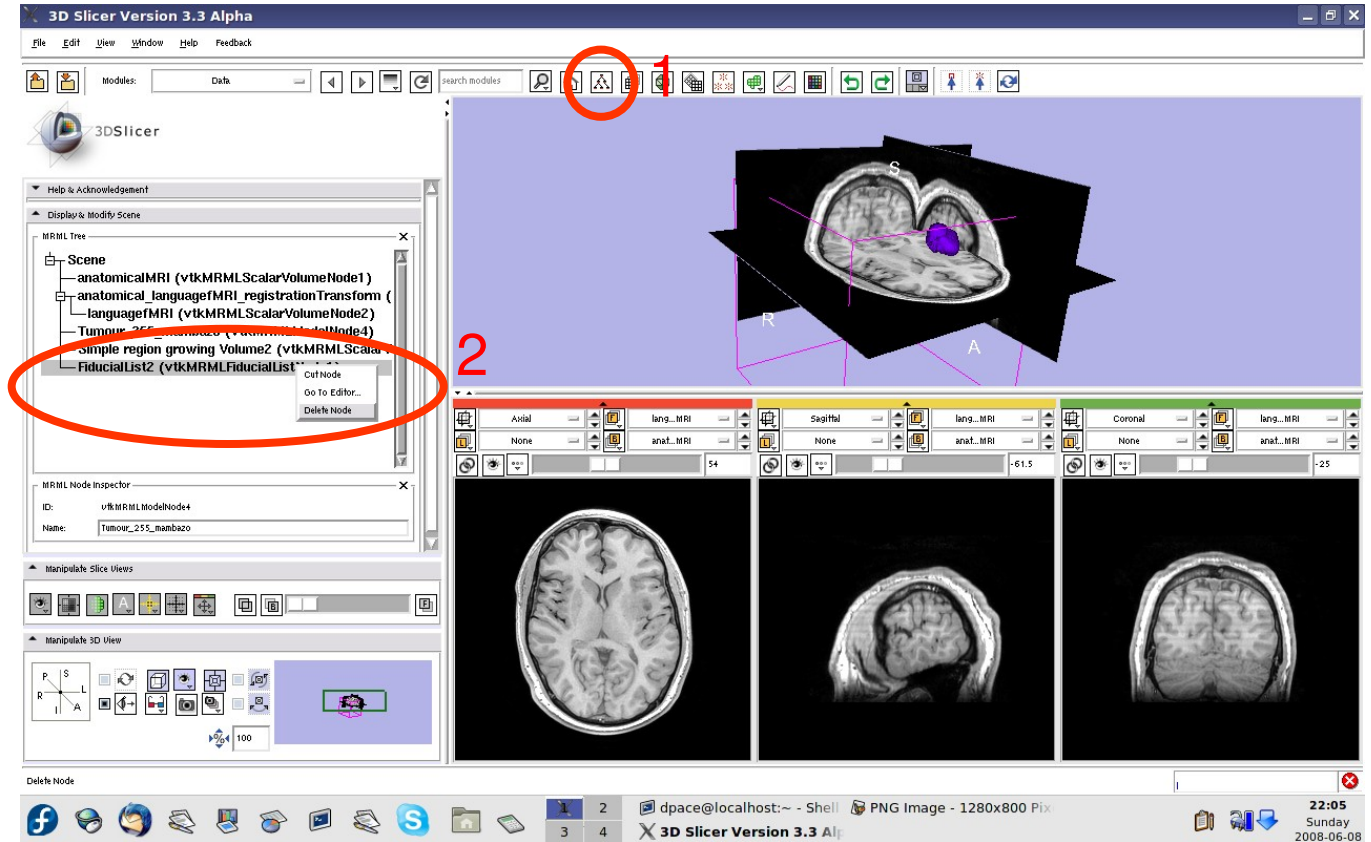




Create the tumour model

Open the Data module

Delete the FiducialList and Simple region growing Volume by right-clicking and selecting "Delete Node"

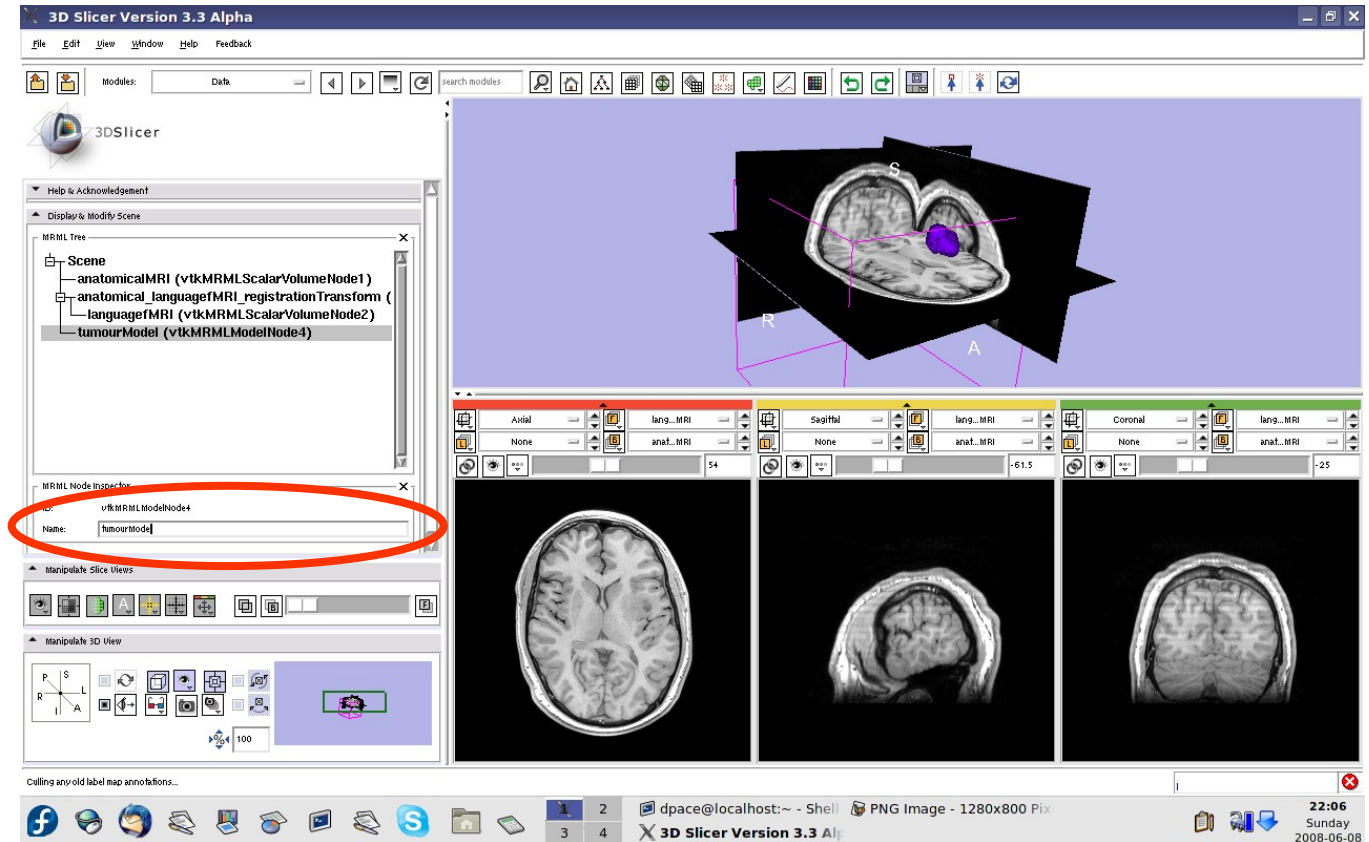




Create the tumour model

Note that the model now appears in the MRML tree

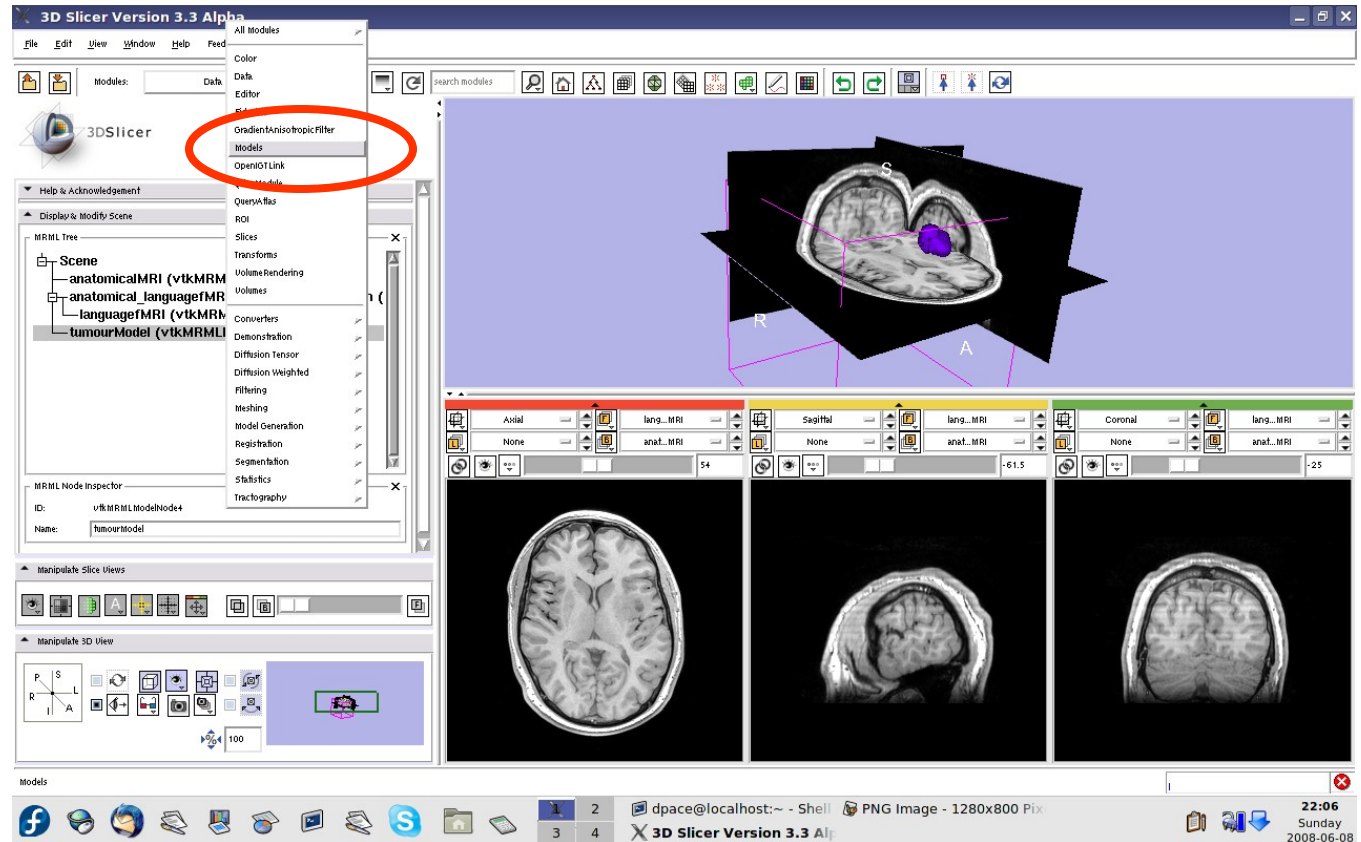
Change the name of the model to "tumourModel"





Change the model's appearance

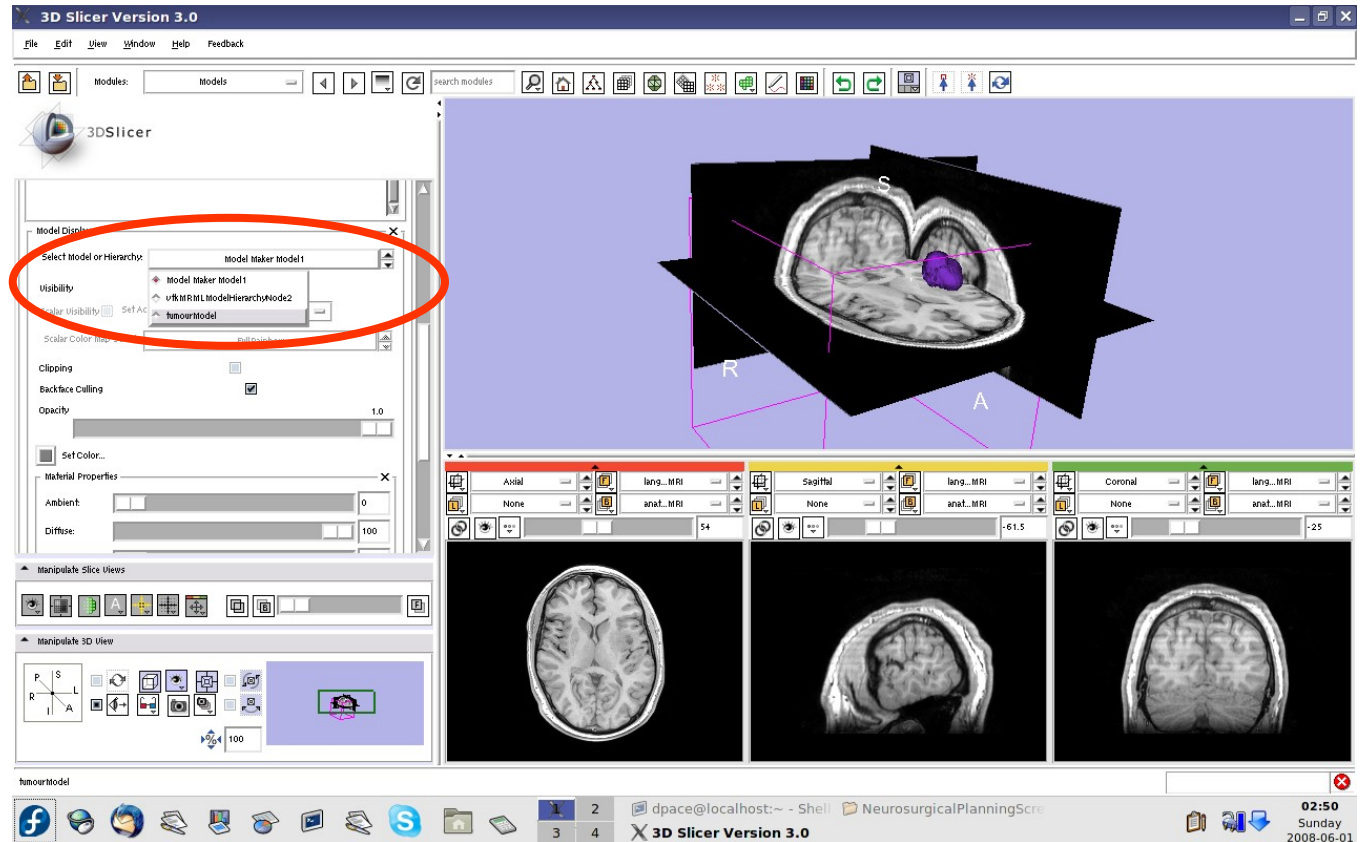
Open the Models module





Change the model's appearance

Select the tumour model

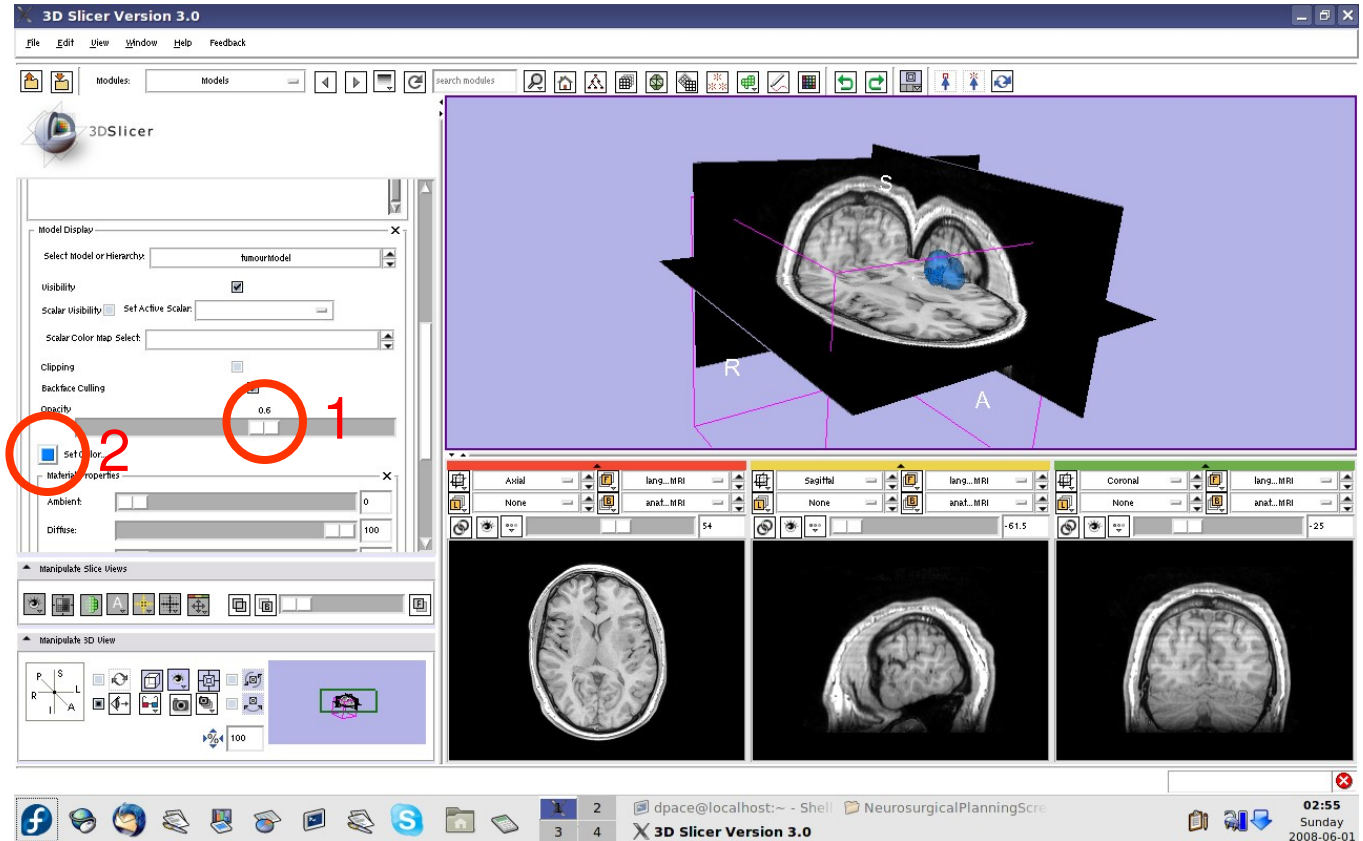




Change the model's appearance

Set the model's opacity to 0.6

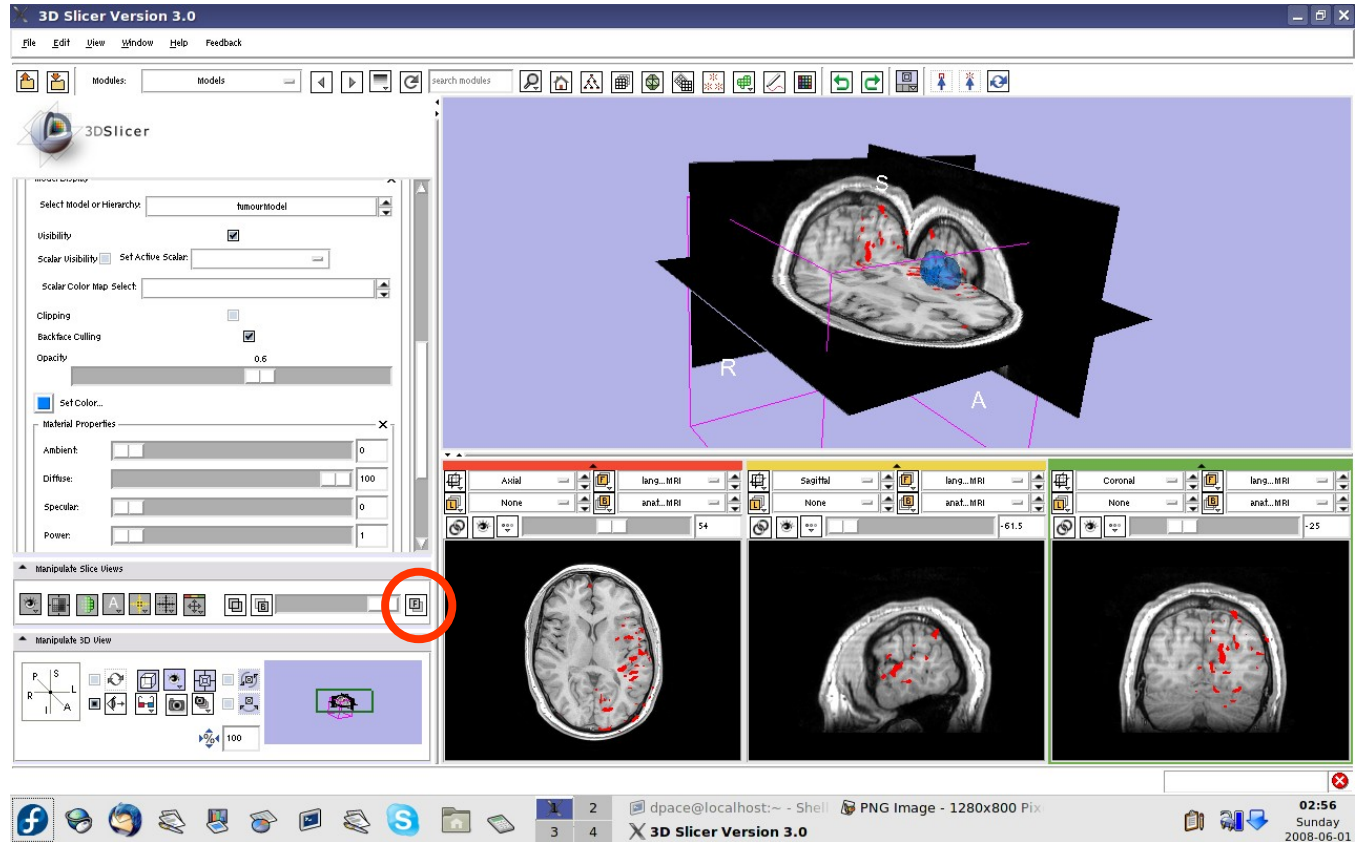
Click on the box next to "Set Color" to change the colour of the model to blue





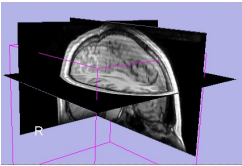
View the anatomical MRI, fMRI and tumour model

Click on the Foreground layer button to show the language fMRI data

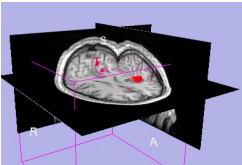




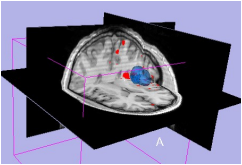
Overview



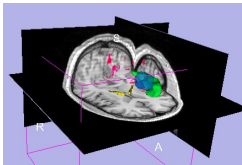
1. Loading and visualizing anatomical MRI data



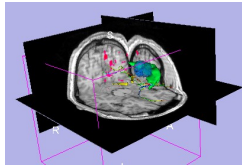
1. Incorporating fMRI data using image registration and thresholding



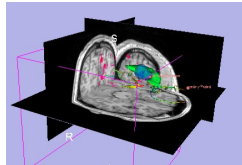
1. Creating a 3D model of the tumour volume



1. **Predicting the locations of brain structures using image registration and a brain atlas**



1. Incorporating brain fiber tractography from diffusion weighted images

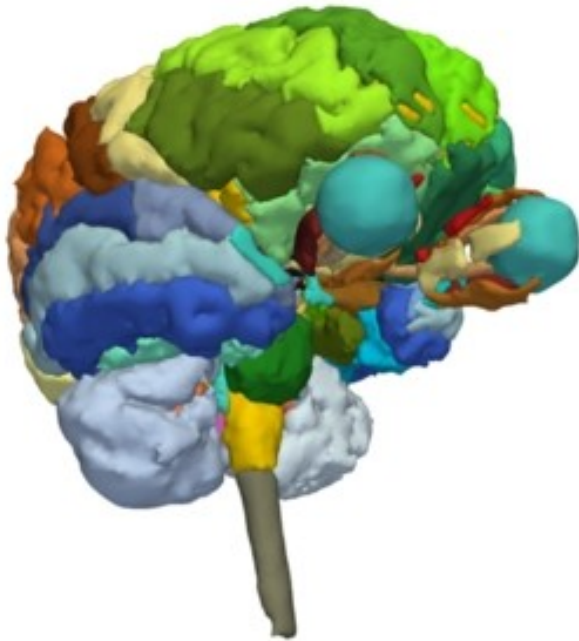


1. Annotating the preoperative plan and saving the scene



The SPL-PNL Brain Atlas

http://www.na-mic.org/pages/Special:PubDB_View? dspace



- Includes:
 - Anatomical MRI
 - Label maps
 - >160 models
- from a healthy volunteer



Incorporating a brain atlas

- **Utility of an atlas in IGT:**
 - Estimate the positions, orientations and shapes of important brain structures without having to segment each one in the patient dataset



Incorporating a brain atlas

- **Components of the brain atlas used here:**
 - Anatomical MRI image
 - Three models of segmented brain structures
- **Using a brain atlas to approximate where brain structures are in the patient:**
 - Register the atlas's MRI with the patient's MRI to determine the transformation between the atlas and the patient
 - Use the same transformation to **transform the atlas models** so that they overlap with the patient's MRI



Incorporating a brain atlas

- **Steps involved in this section:**

Import MRML scene

Inspect the MRML scene

Registration using the MRML scene

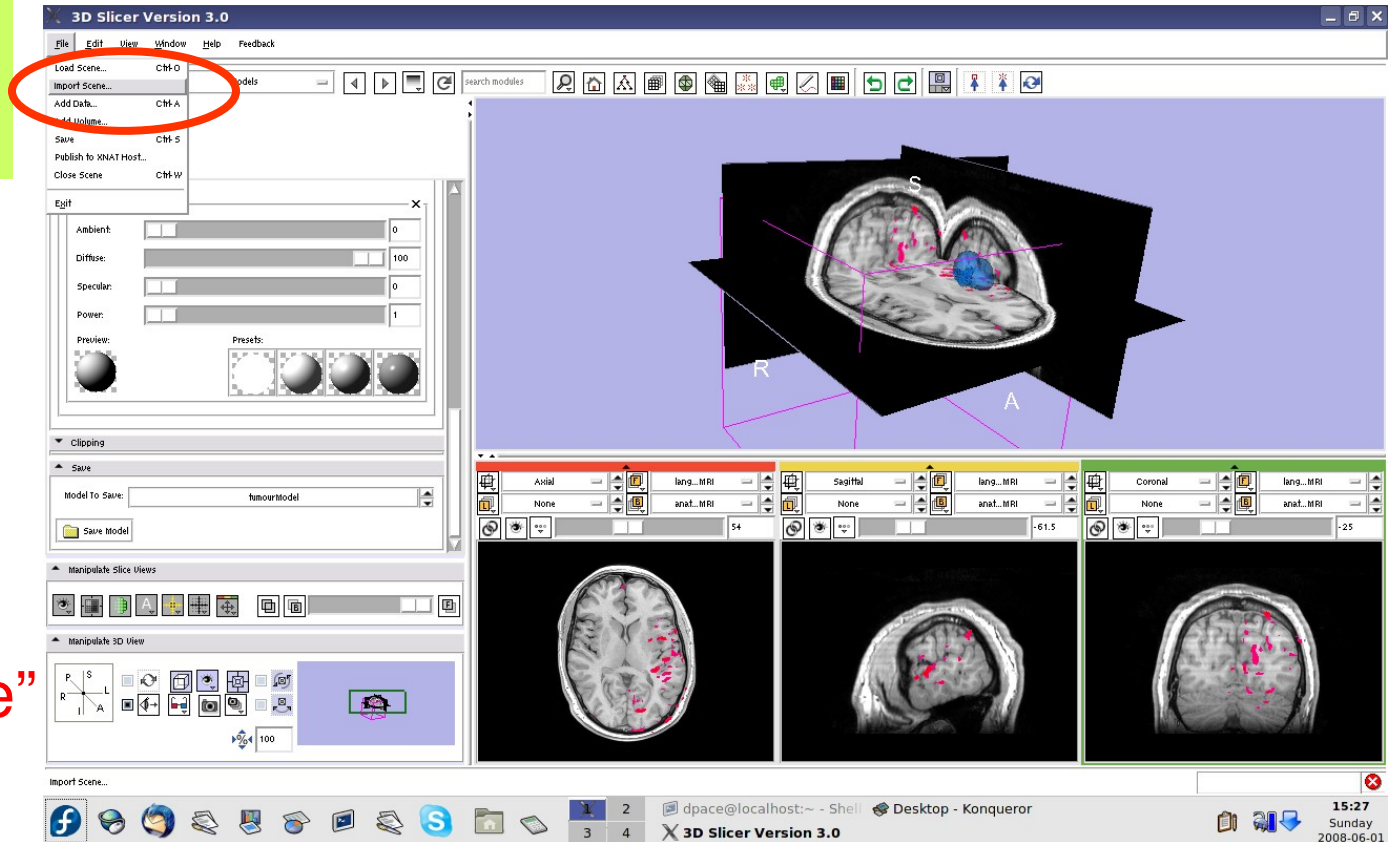
- The precomputed MRML scene contains a copy of the patient's anatomical MRI, the atlas's anatomical MRI, three models:
 - Left and right optic tracts
 - Left anterior superior temporal gyrusand the transformation between the patient and the atlas
- The anatomical MRIs of the patient and the atlas were registered with an initial manual transform followed by an automatic affine registration



Import the patient-atlas registration transform scene

Select File -> Import Scene

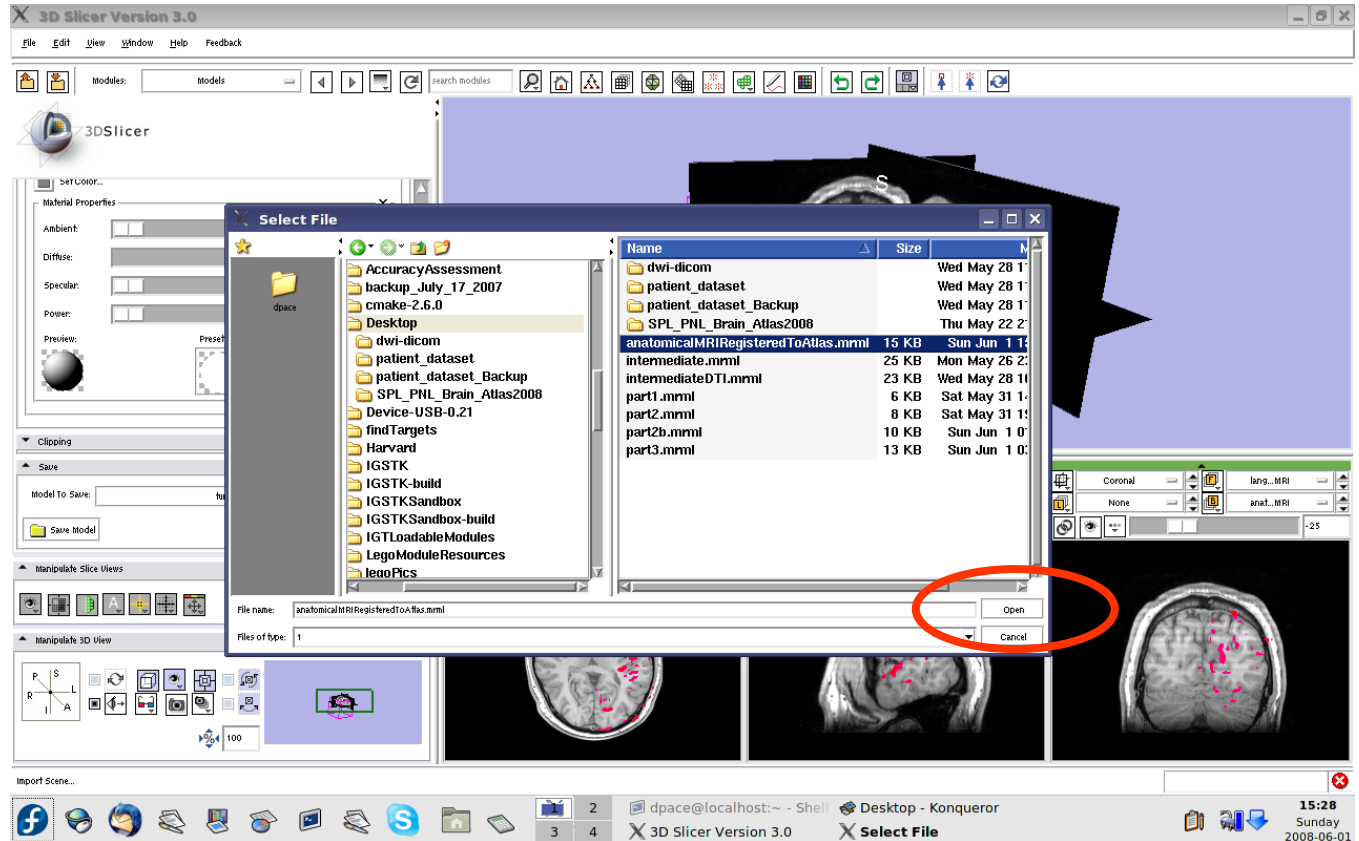
Note: Make sure that you select “Import Scene” and not “Load Scene”, as “Load Scene” will delete your work so far





Import the patient-atlas registration transform scene

Select
“anatomical
MRI Registered
ToAtlas.mrml”,
then click
“Open”



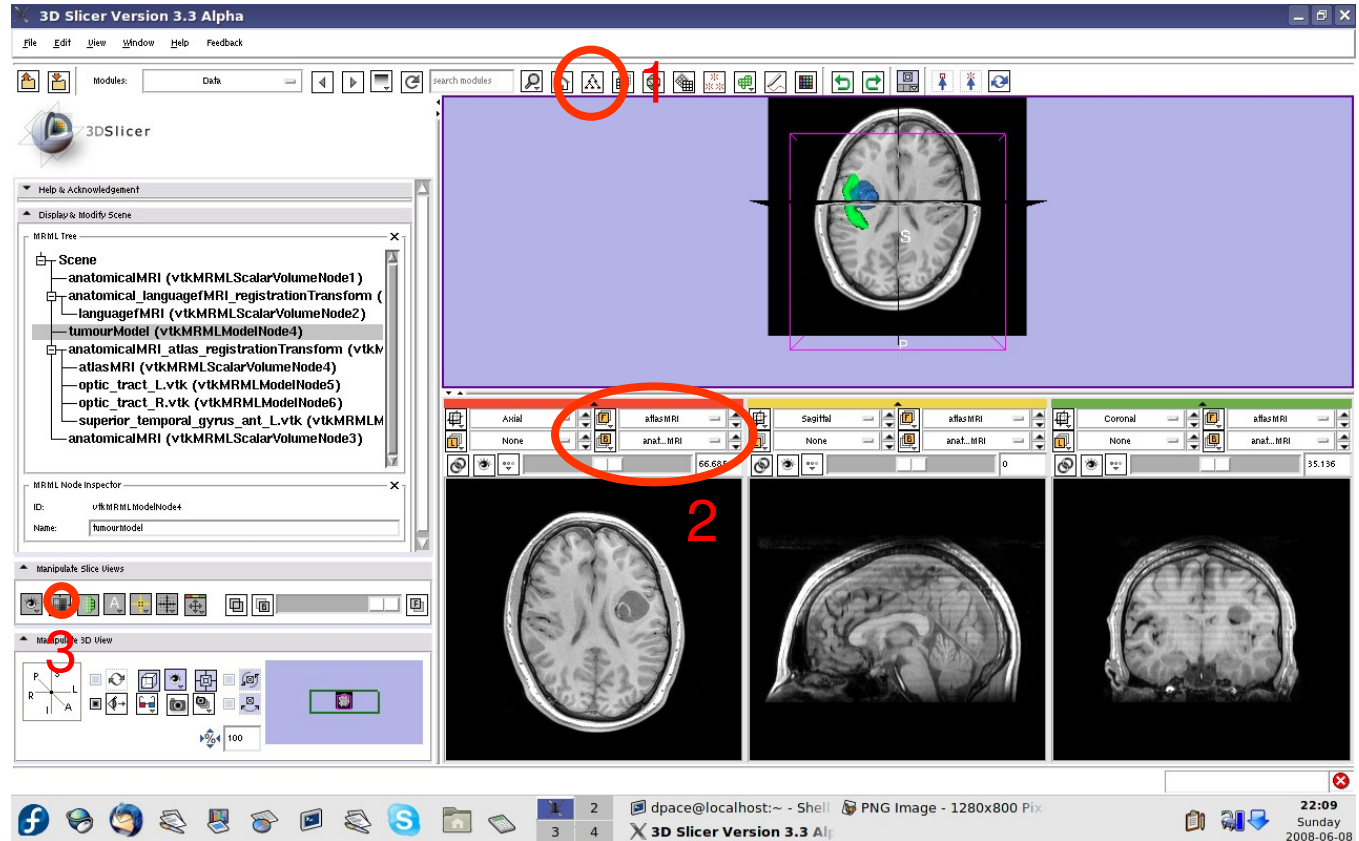


Inspect the MRML scene

Open the Data module

Set the foreground to atlasMRI and the background to anatomicalMRI

Click on the “fit to window” button

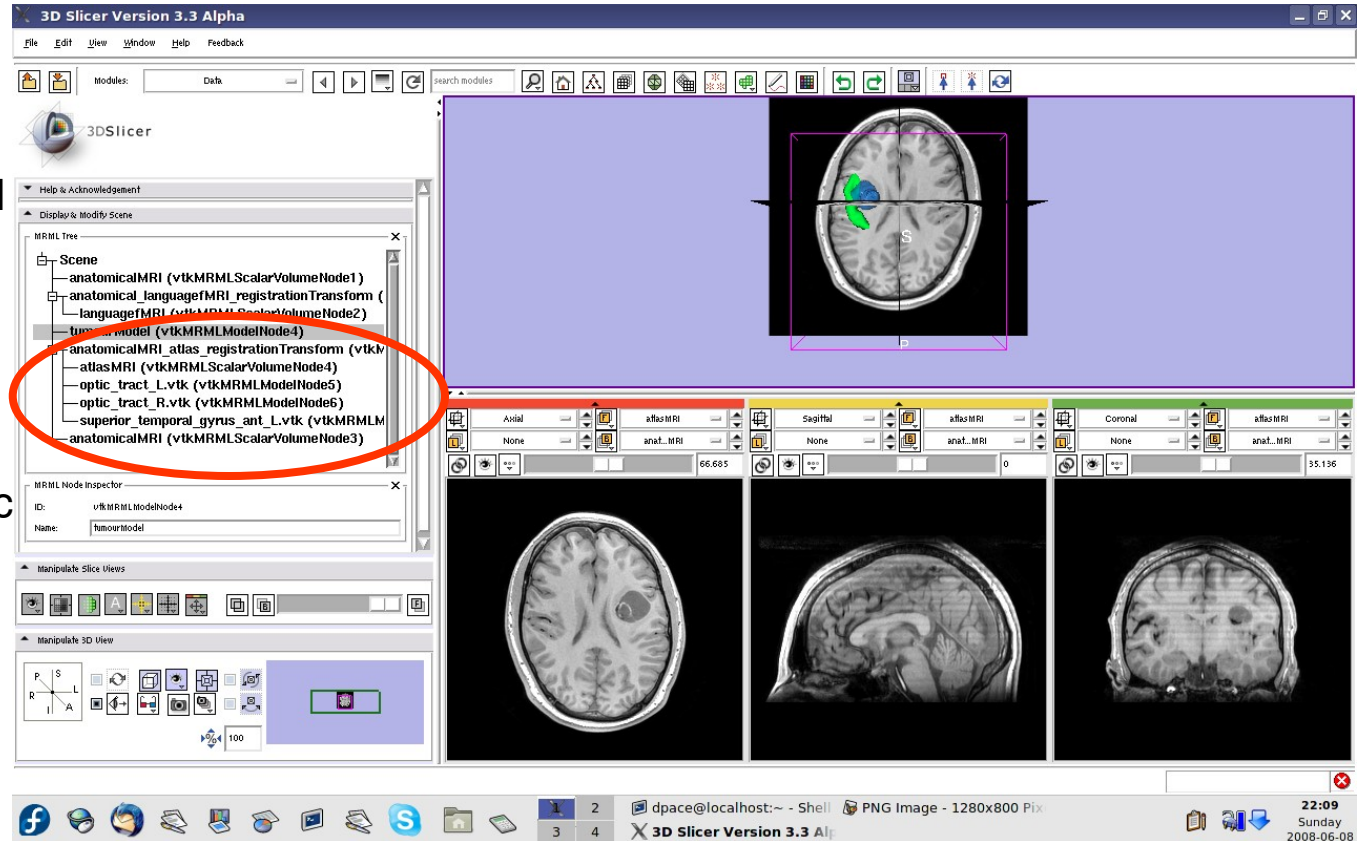




Inspect the MRML scene

Inspect the atlas MRML scene - 6 new nodes

- atlasMRI = anatomical MRI from the atlas
- optic_tract_L.vtk = model of the left optic tract
- optic_tract_R.vtk = model of the right optic tract
- Superior_temporal_gyrus_ant_L.vtk = model of the left anterior superior temporal gyrus

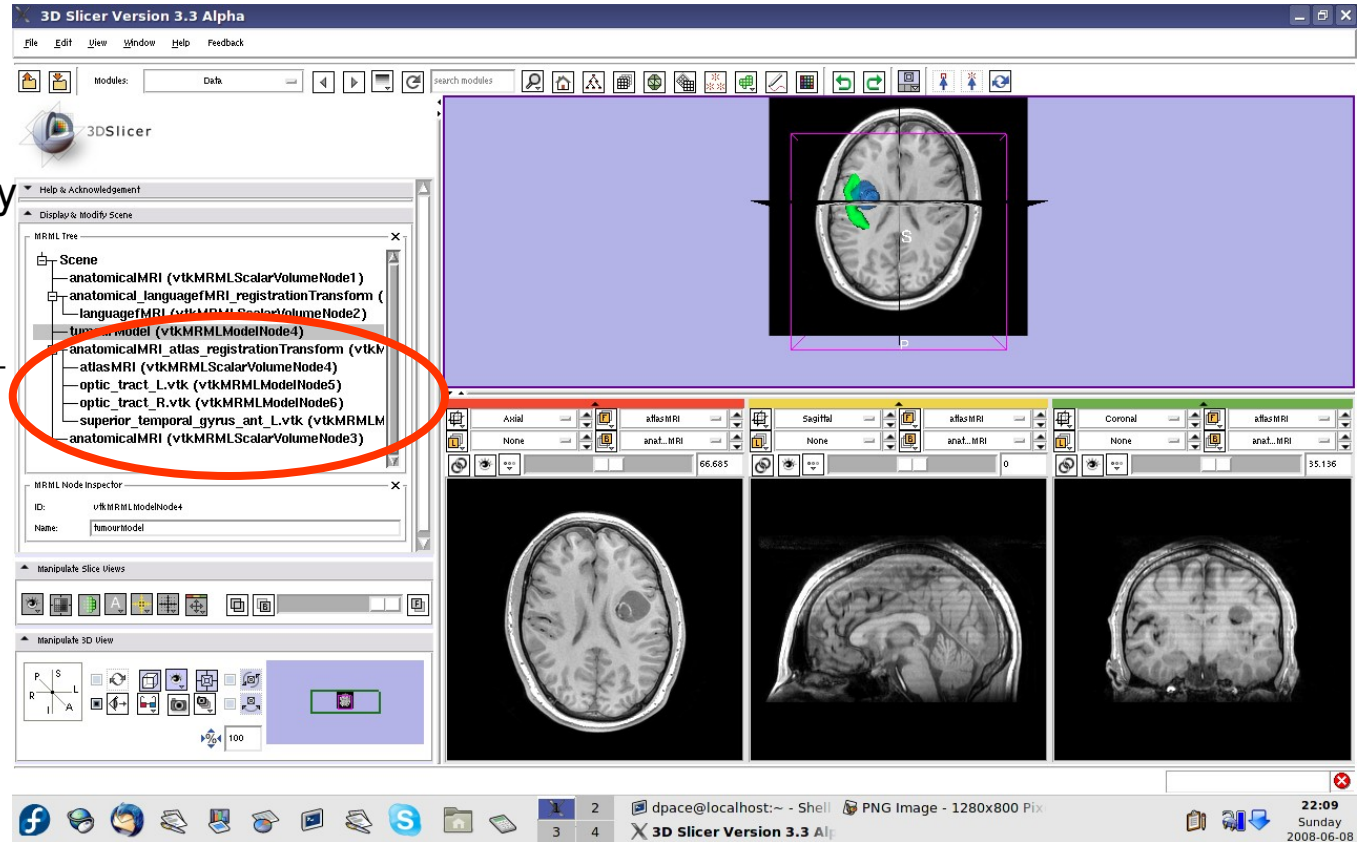




Inspect the MRML scene

Inspect the atlas MRML scene - 6 new nodes

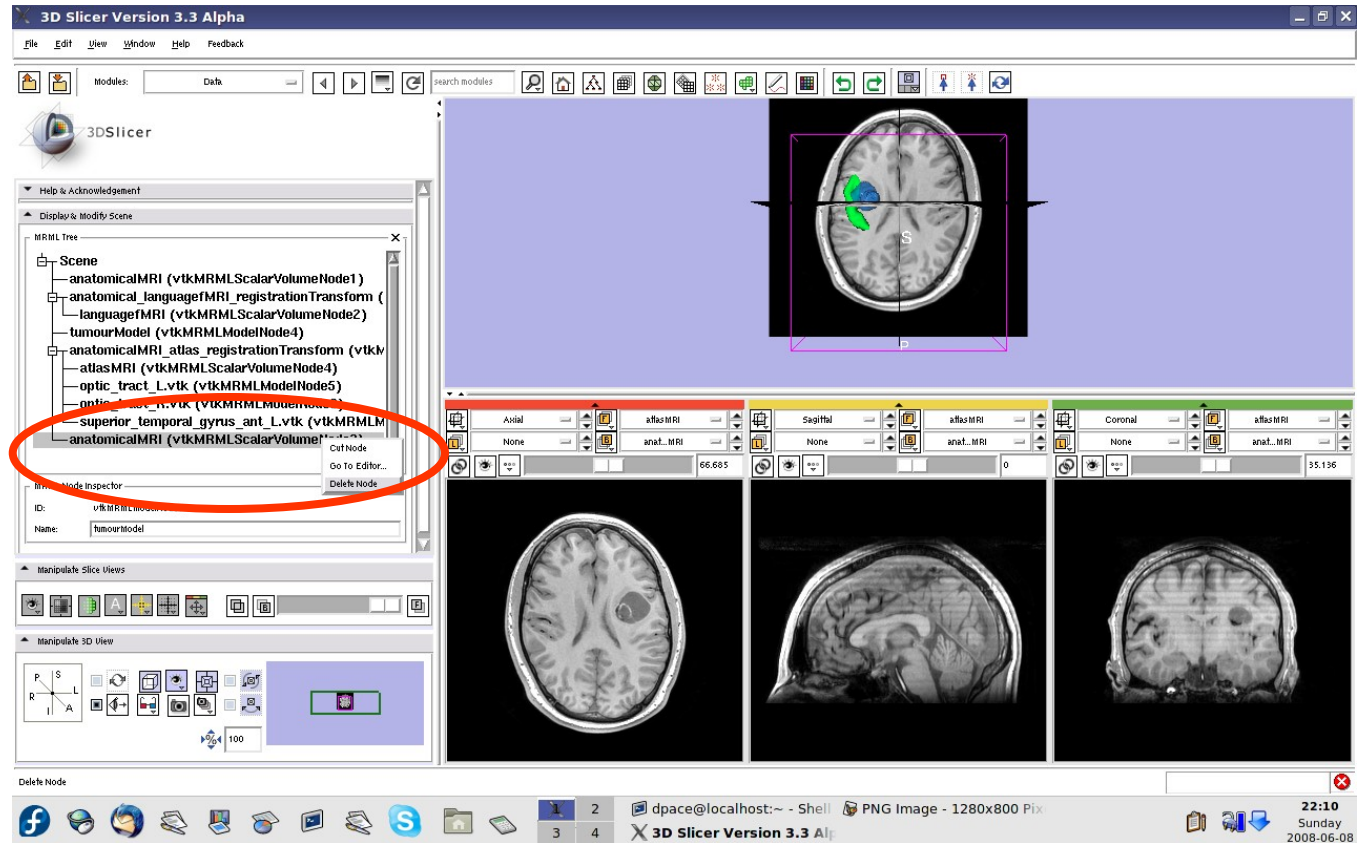
- anatomical MRI = copy of the patient's anatomical MRI
- anatomicalMRI_atlas_registration Transformation = the transformation between the patient's anatomical MRI and the atlas's MRI





Inspect the MRML scene

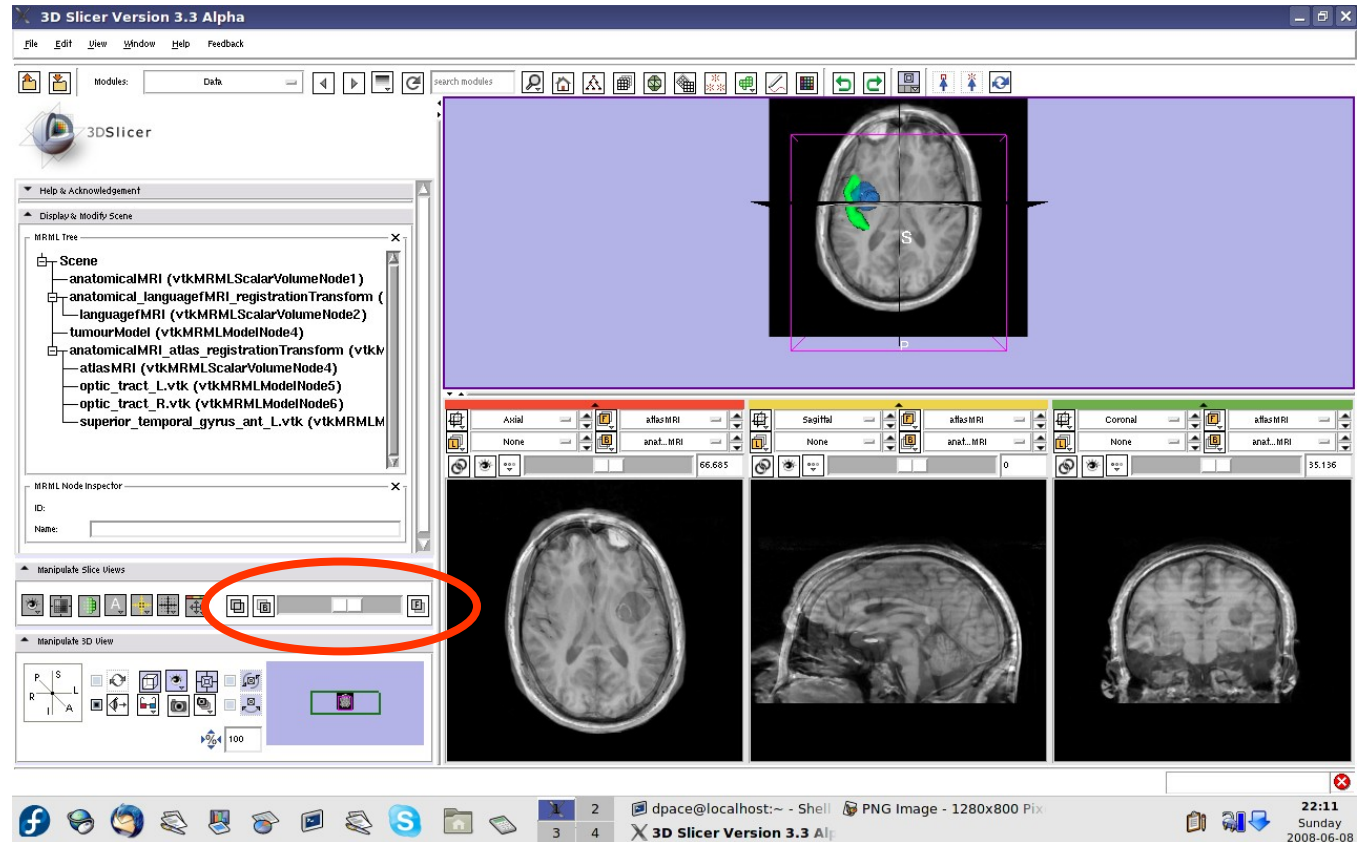
Delete the duplicate anatomicalMRI node by right-clicking and selecting “Delete Node”





Inspect the patient-atlas registration

Scale the opacities to see how well the atlas MRI and patient anatomical MRI image volumes are aligned





Inspect the patient-atlas registration

- **Important note:** Since an affine registration was used, the brain structure models from the atlas may not match the anatomy of the patient:
 - Affine registration does not account for differences in brain shape
 - The patient's tumour will deform brain structures compared to the healthy atlas subject
- Thus the brain structure models give only a rough idea of their positions in the patient
- Non-linear registration could be used to partially remedy this - ex. B-Spline registration in Slicer3

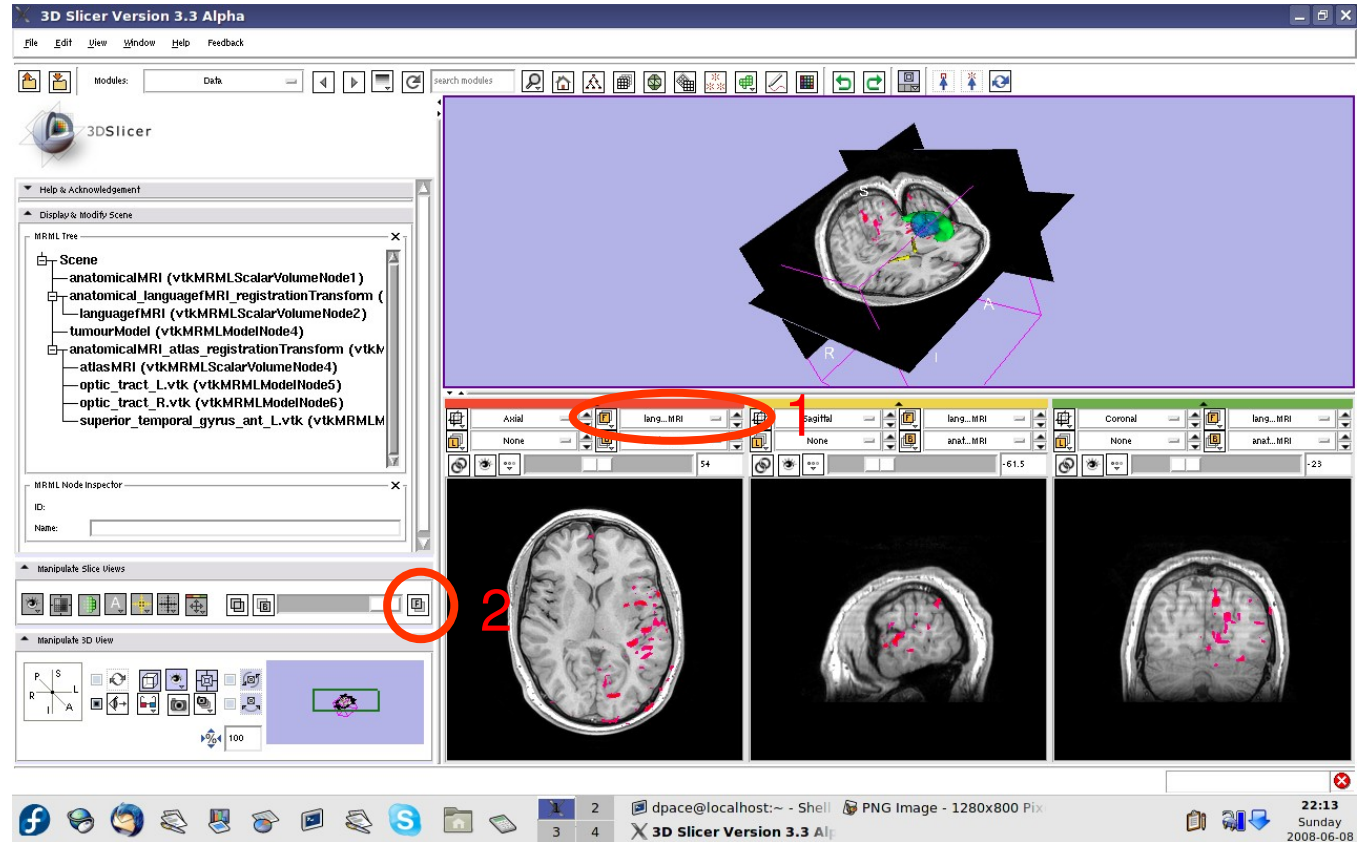


Inspect the entire scene so far

Set the foreground to languagefMRI

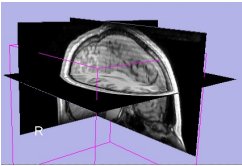
Click on the Foreground layer button to show the language fMRI data

Slice through the image volume to get a good view

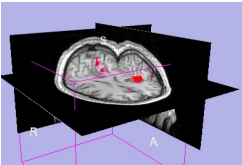




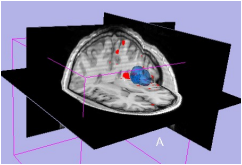
Overview



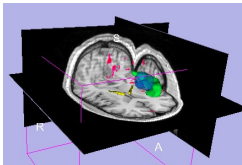
1. Loading and visualizing anatomical MRI data



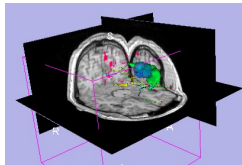
1. Incorporating fMRI data using image registration and thresholding



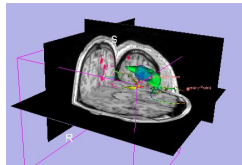
1. Creating a 3D model of the tumour volume



1. Predicting the locations of brain structures using image registration and a brain atlas




1. **Incorporating brain fiber tractography from diffusion weighted images**



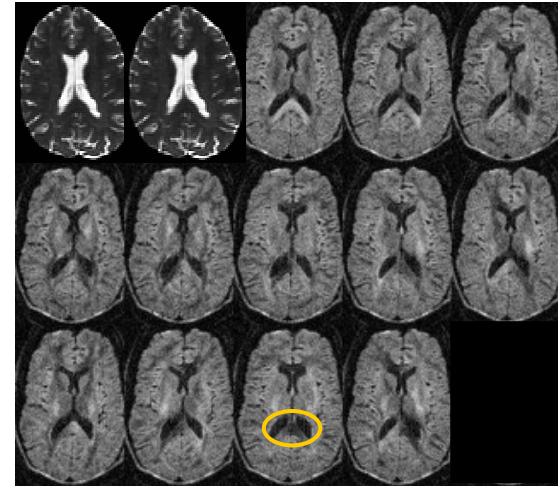
1. Annotating the preoperative plan and saving the scene

Diffusion Tensor Imaging (DTI)

Diffusion Sensitizing Gradients



Diffusion Weighted Images

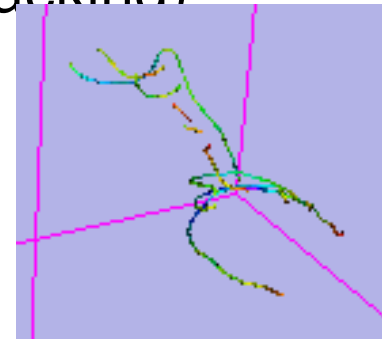
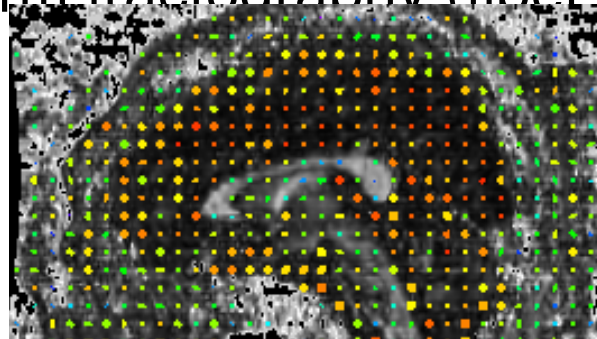
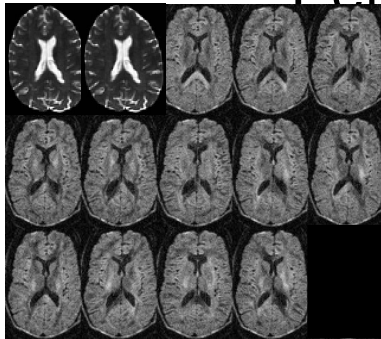


- Each diffusion weighted image shows the diffusion of water in the direction of the diffusion sensitizing gradient



Diffusion Tensor Imaging (DTI)

- Acquire diffusion weighted images (DWI) and baseline images
 - Estimate a tensor at each voxel to create a Diffusion Tensor Image (DTI)
 - Calculate a scalar “diffusion anisotropy index”, such as fractional anisotropy, to quantify the diffusion’s anisotropy
 - Perform tractography (fiber tracking)





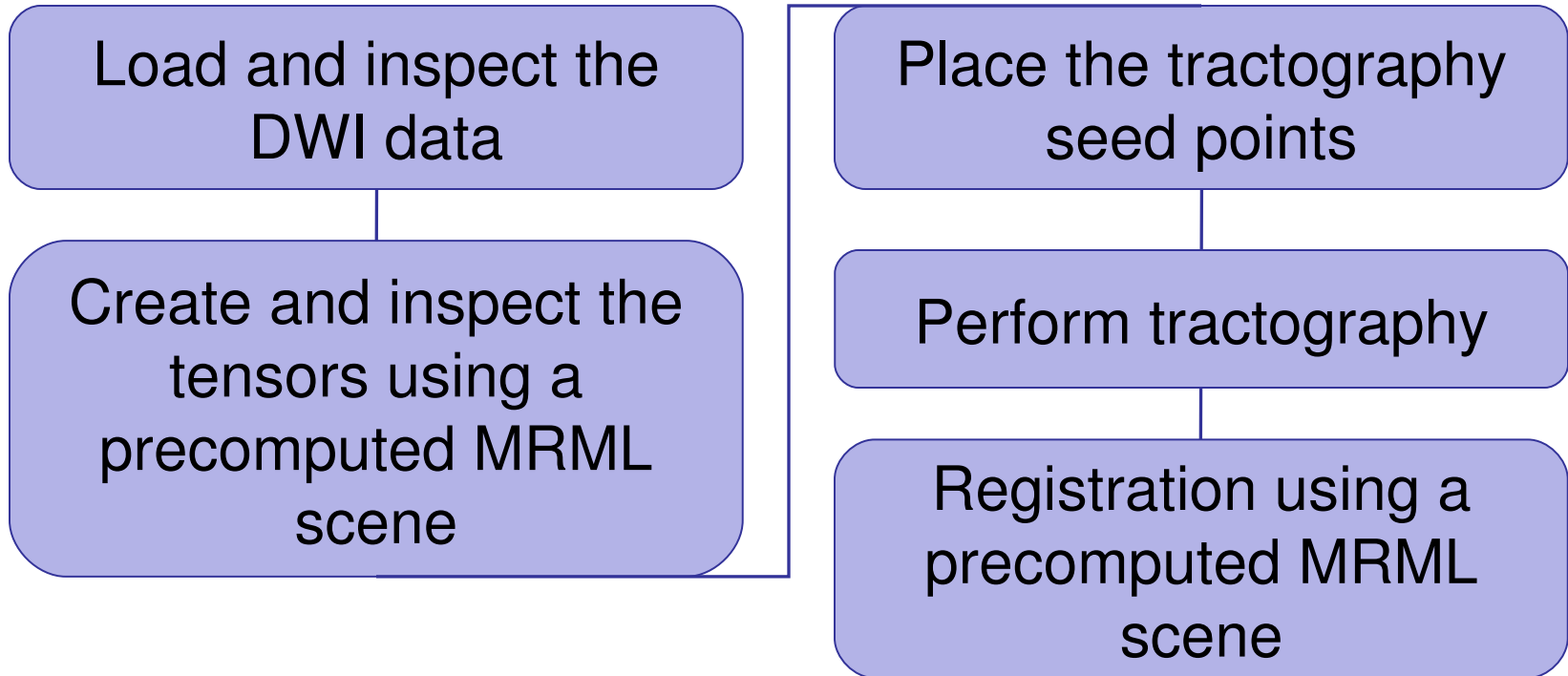
Diffusion Tensor Imaging (DTI)

- **Utility of Diffusion Tensor Imaging in IGT:**
 - Major tracts that run between functionally important regions of the brain must remain intact to prevent side effects for the patient
 - Knowing where these tracts are allows us to modify our surgical plan so that we avoid them (as much as possible)



Diffusion Tensor Imaging (DTI)

- **Steps involved in this section:**





Load the DWI data

The screenshot shows the 3D Slicer Version 3.4 interface. The 'DICOM DWI Loader' module is open, showing a 'Parameter set' dropdown set to 'r' and a 'Status' of 'Completed'. The 'IC' section shows 'DicomDirectory' set to 'DTI' and 'dwiImage' set to a dropdown menu. Below these are 'Default', 'Cancel', and 'Apply' buttons. A large green text box is overlaid on the right side of the window, containing the following text:

Open the DICOM DWI Loader module:
Modules -> Converters -> Dicom DWI Loader

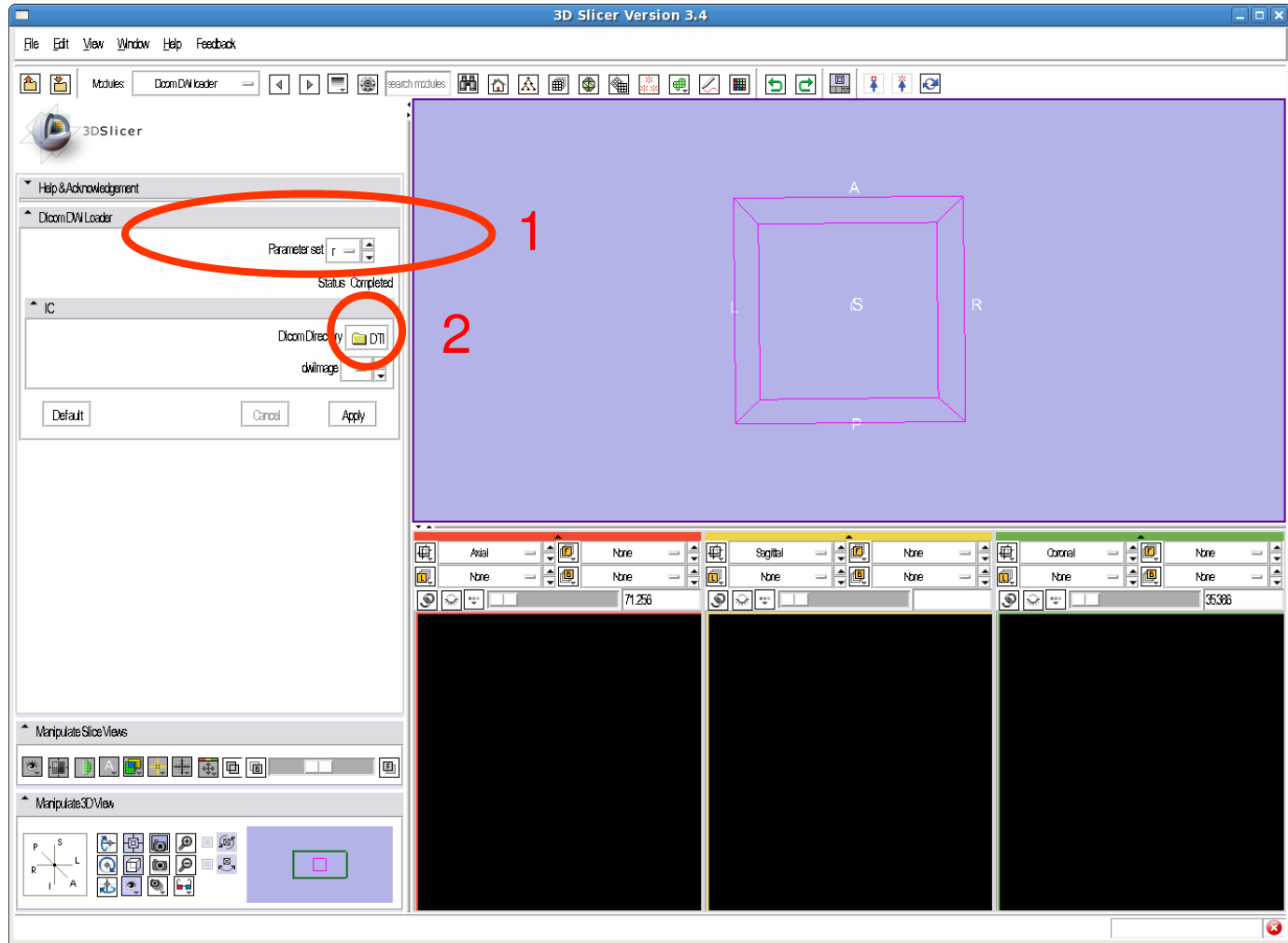
The interface also shows a menu bar (File, Edit, View, Window, Help, Feedback), a toolbar with various icons, and a 3D view area at the bottom with three panels (Axial, Sagittal, Coronal) and a status bar showing coordinates (71.256, 35.386).



Load the DWI data

Create a new
CommandLine
Module

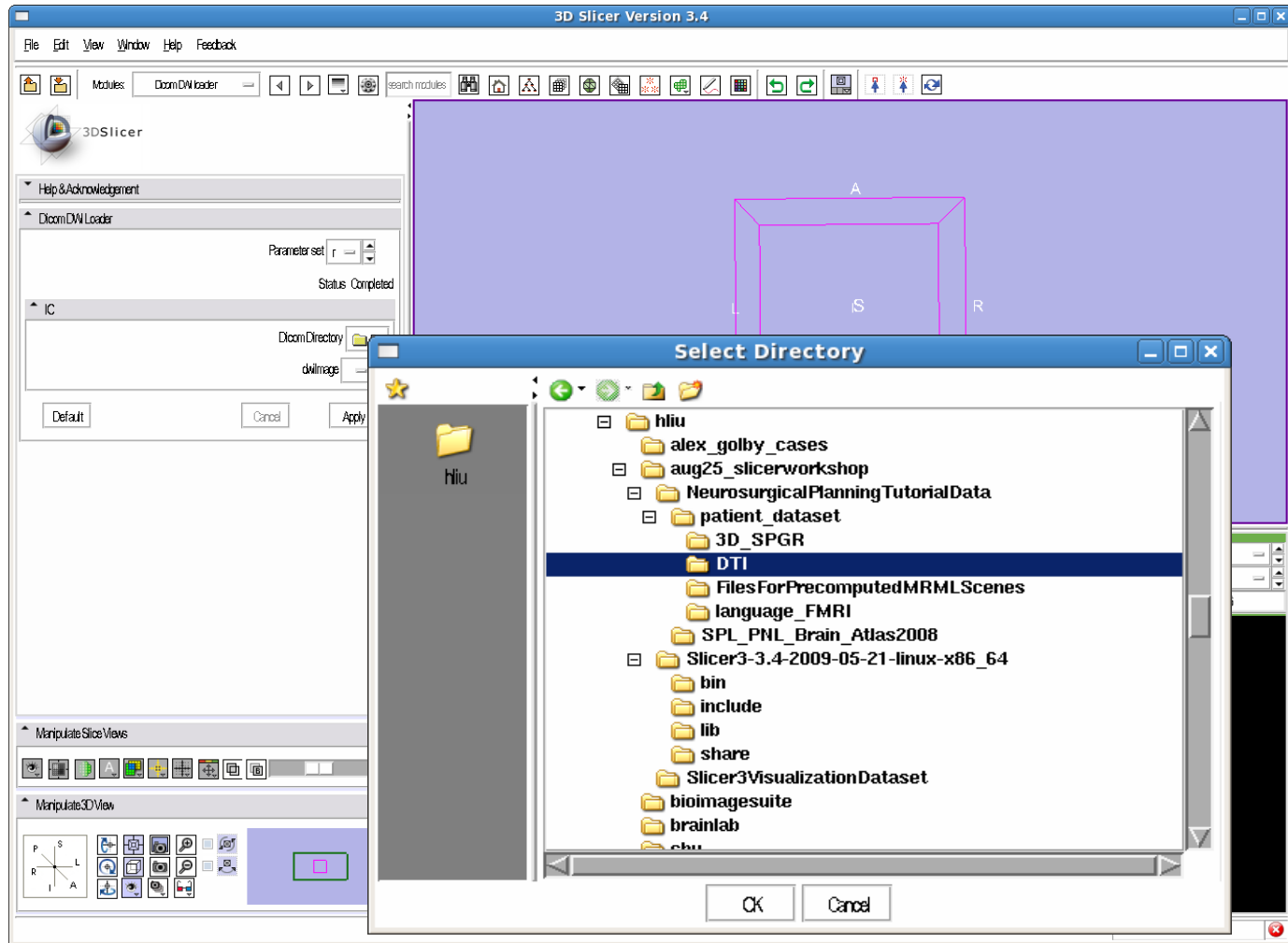
Click on the
folder icon to
set the DICOM
directory





Load the DWI data

Click on the DTI folder within the patient dataset, then click “OK”



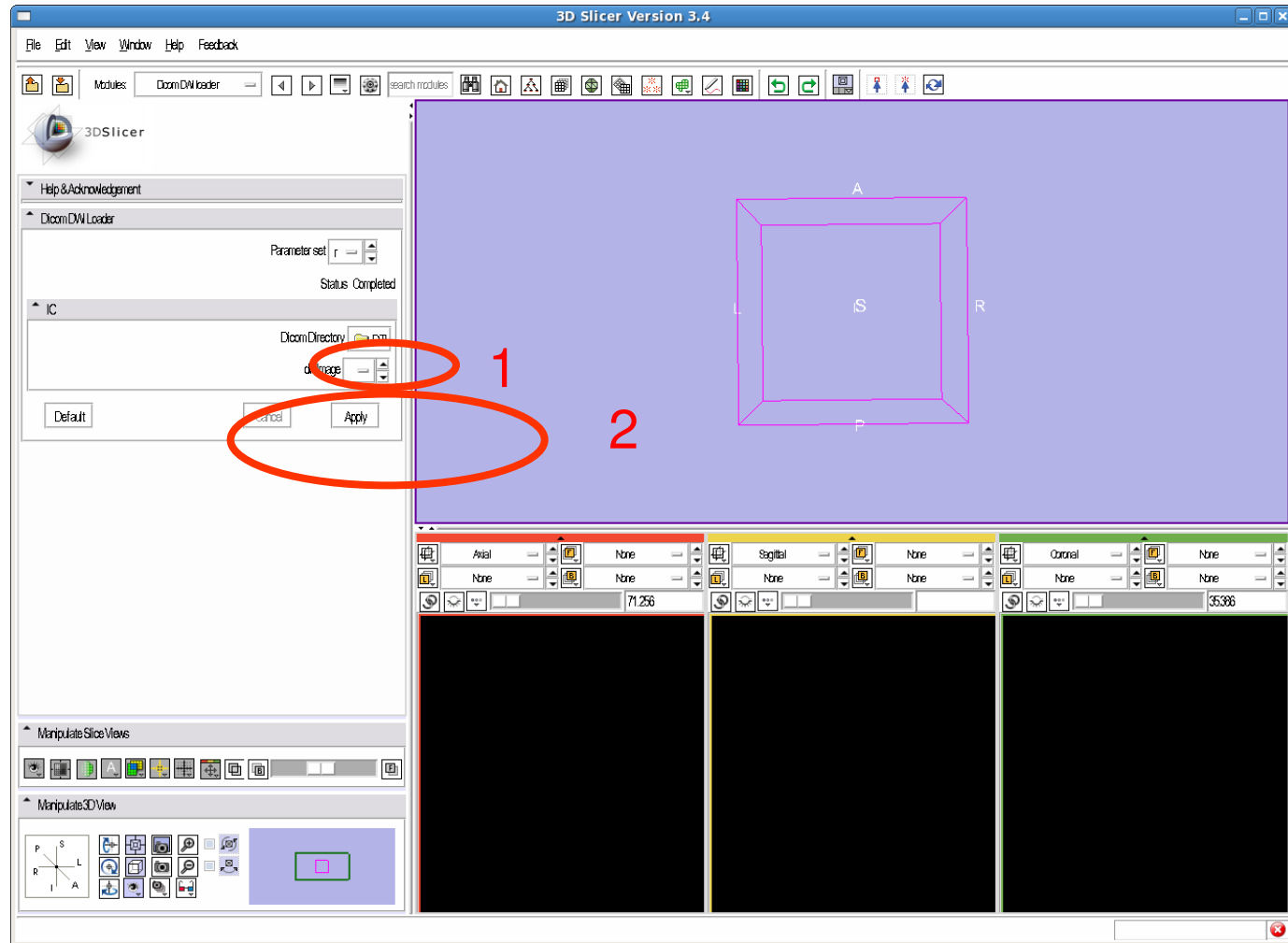


Load the DWI data

Set the dwimage to “Create New Diffusion Weighted Volume”

Click “Apply”

This step may take a few minutes. Wait until Status says “Completed”



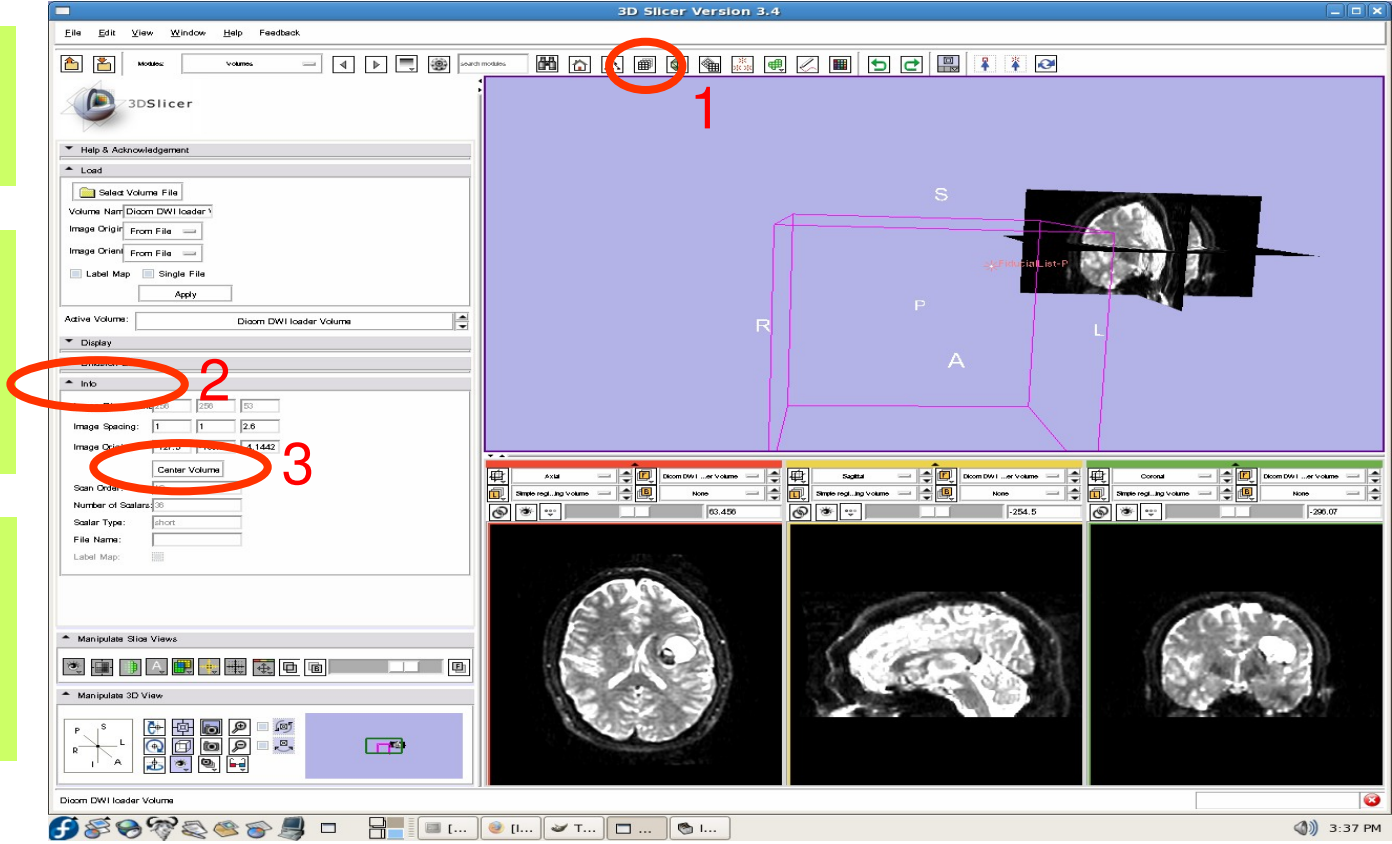


Load the DWI data

Select the Volumes Module

Close “Display” tab and expand “Info” tab.

Select “Center Volume”

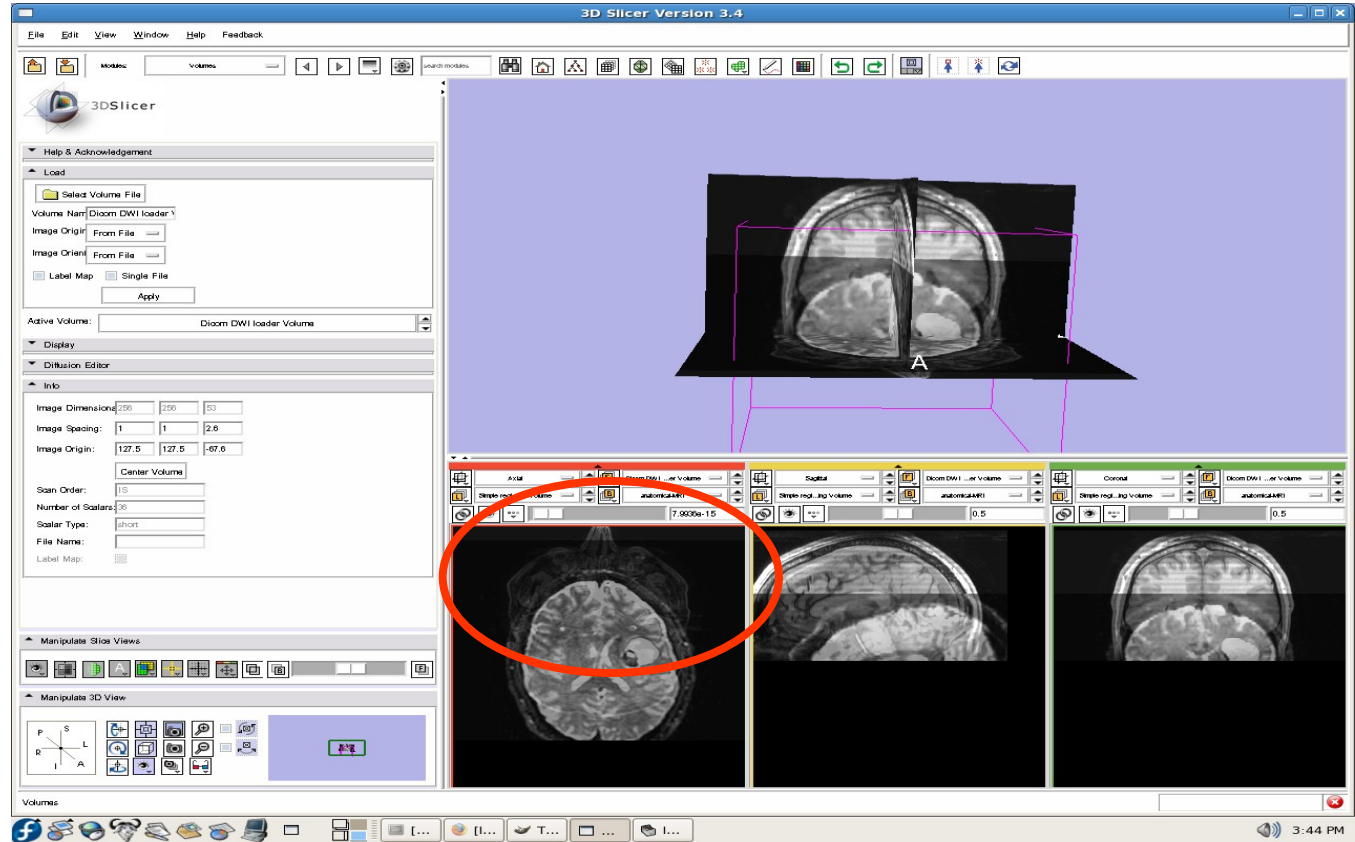




Load the DWI data

Note that the volumes are not correctly aligned.

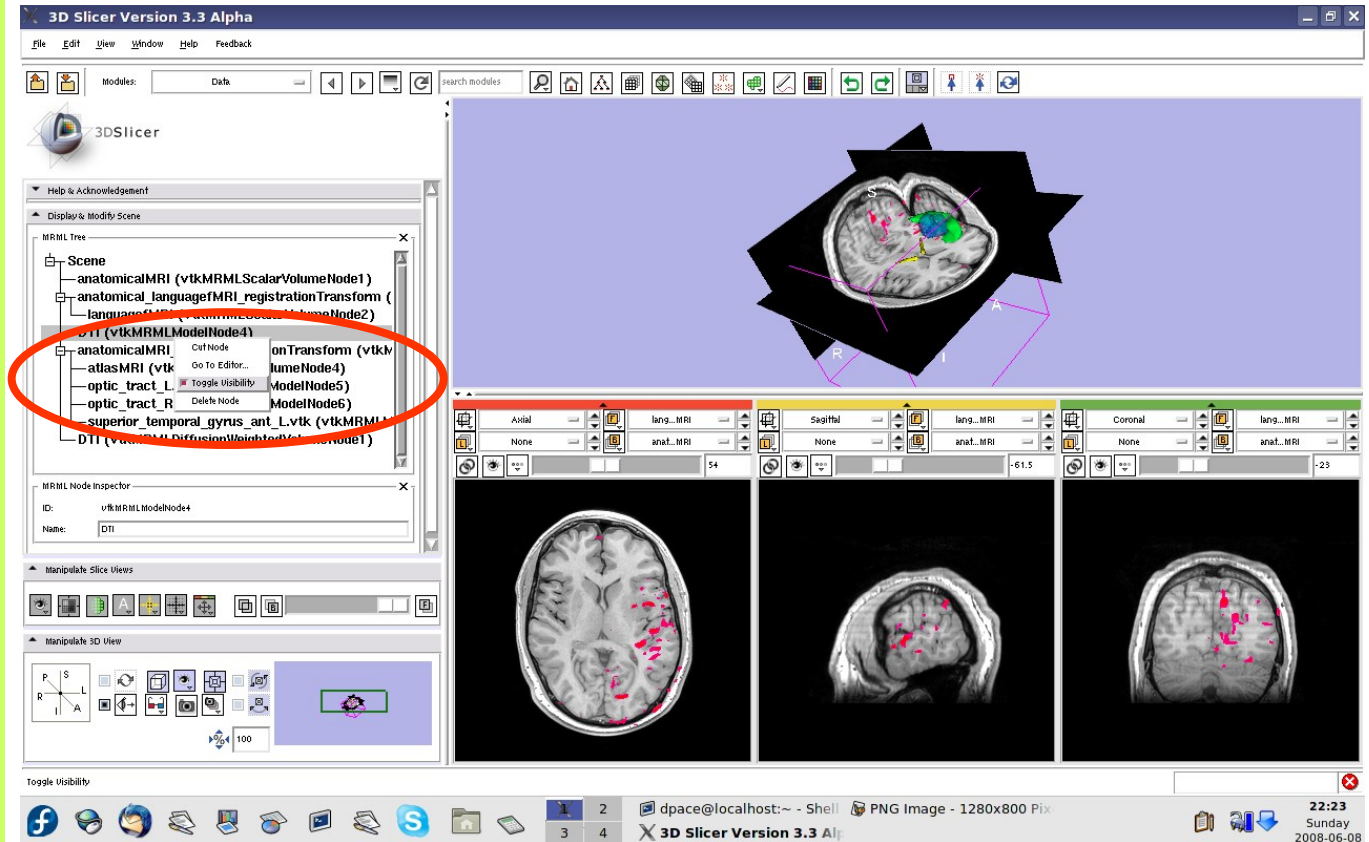
Repeat the steps from slide 41 to align the volumes using manual transform followed by affine registration





Load the DWI data

Turn the visibility off for the four models in the scene (tumour, left and right optic tracts, and left anterior superior temporal gyrus) by right-clicking and selecting “Toggle Visibility”



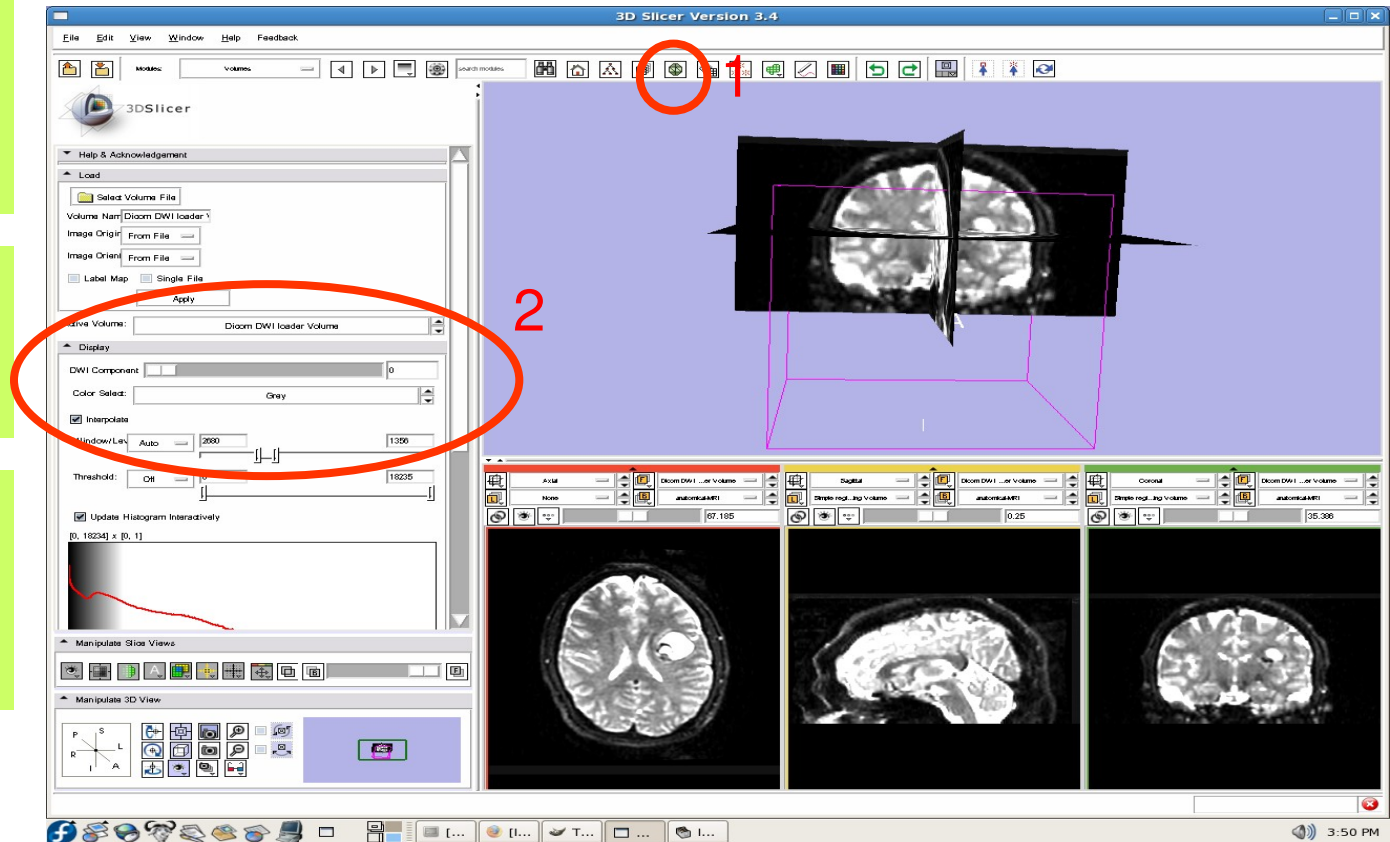


Inspect the DWI data

Open the Volumes module

Open the Display pane

Set the active volume to the DTI volume





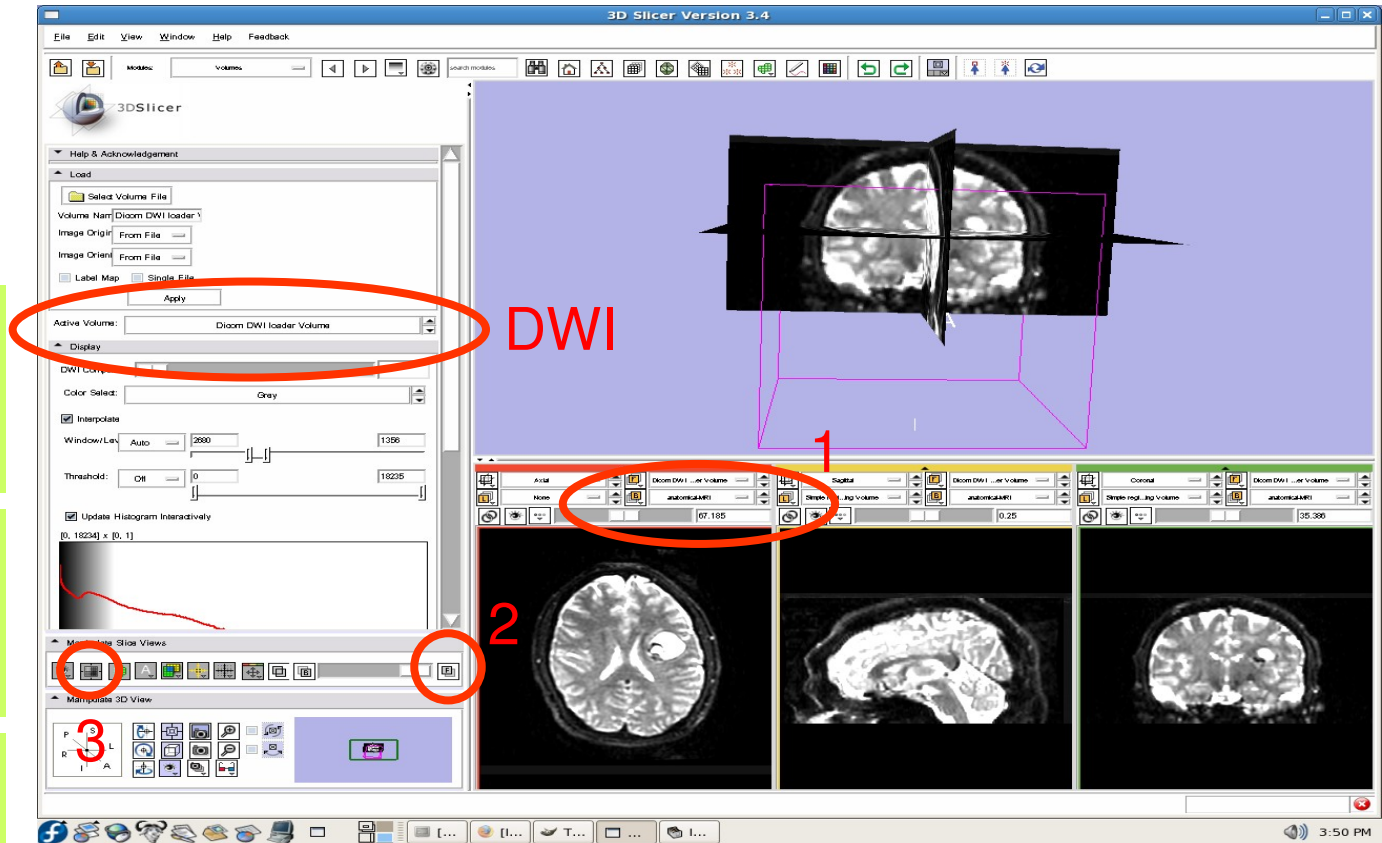
Inspect the DWI data

Note that the Display pane now allows you to select the DWI volume

Set the background to DTI

Click on the Background layer button

Click on the “fit to window” button



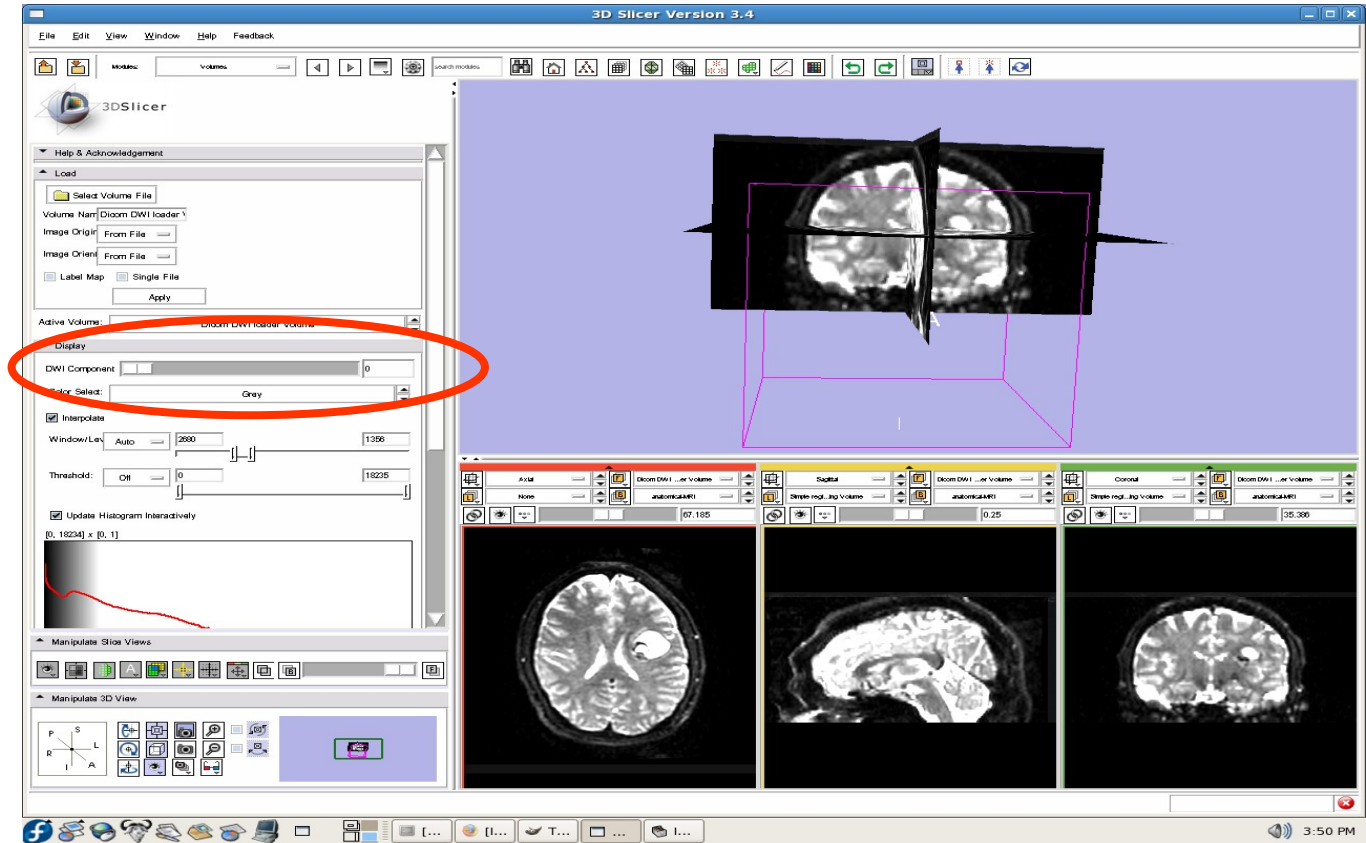


Inspect the DWI data

Scroll through the 36 volumes in the set:

-0 to 4 are baseline images

-5 to 35 are diffusion weighted images

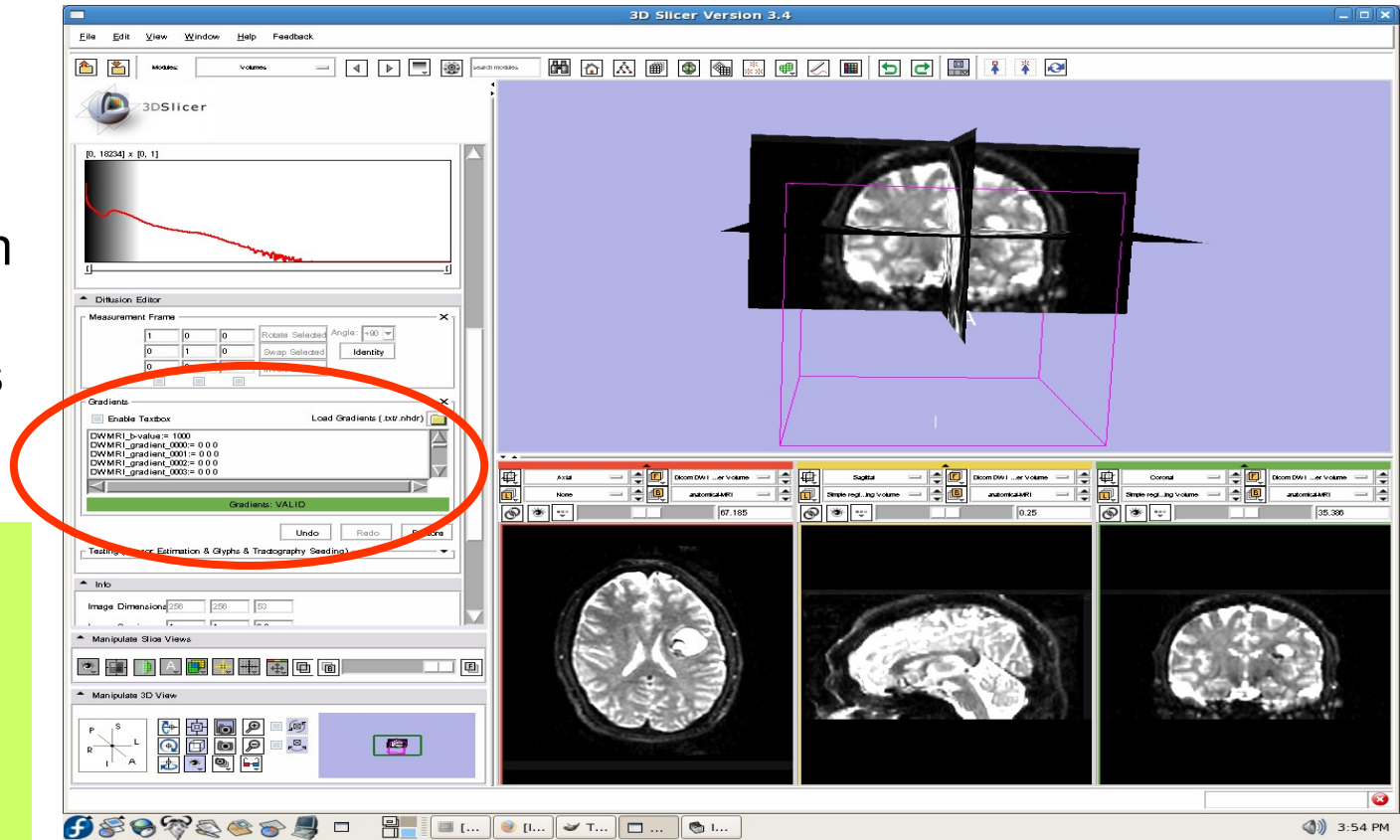




Inspect the DWI data

Note that the Diffusion Editor pane within the volumes module is activated when diffusion weighted images are loaded

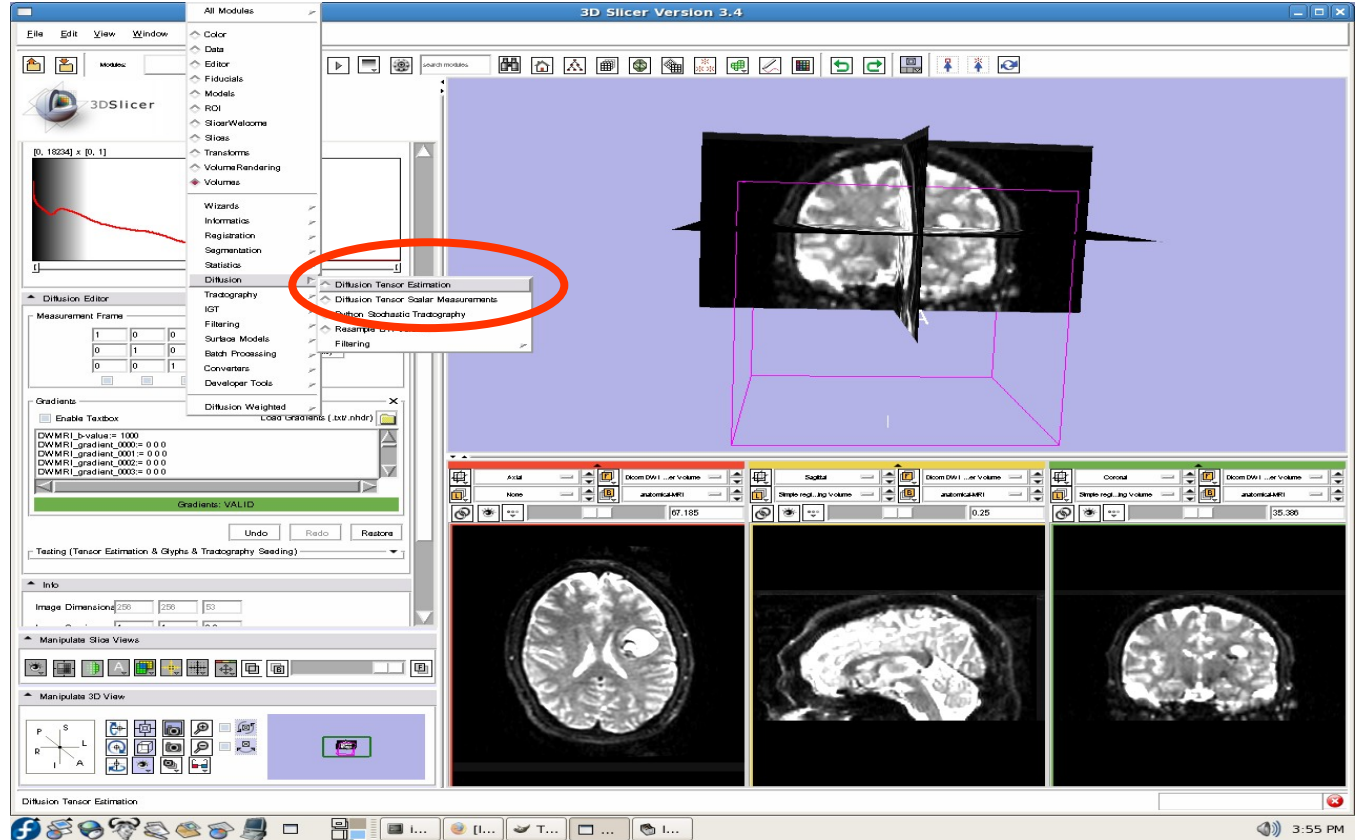
Expand the Diffusion Editor pane and note the gradients used to acquire the images





Create the tensors

Select the Module
“Diffusion Imaging -> Diffusion Tensor Estimation”

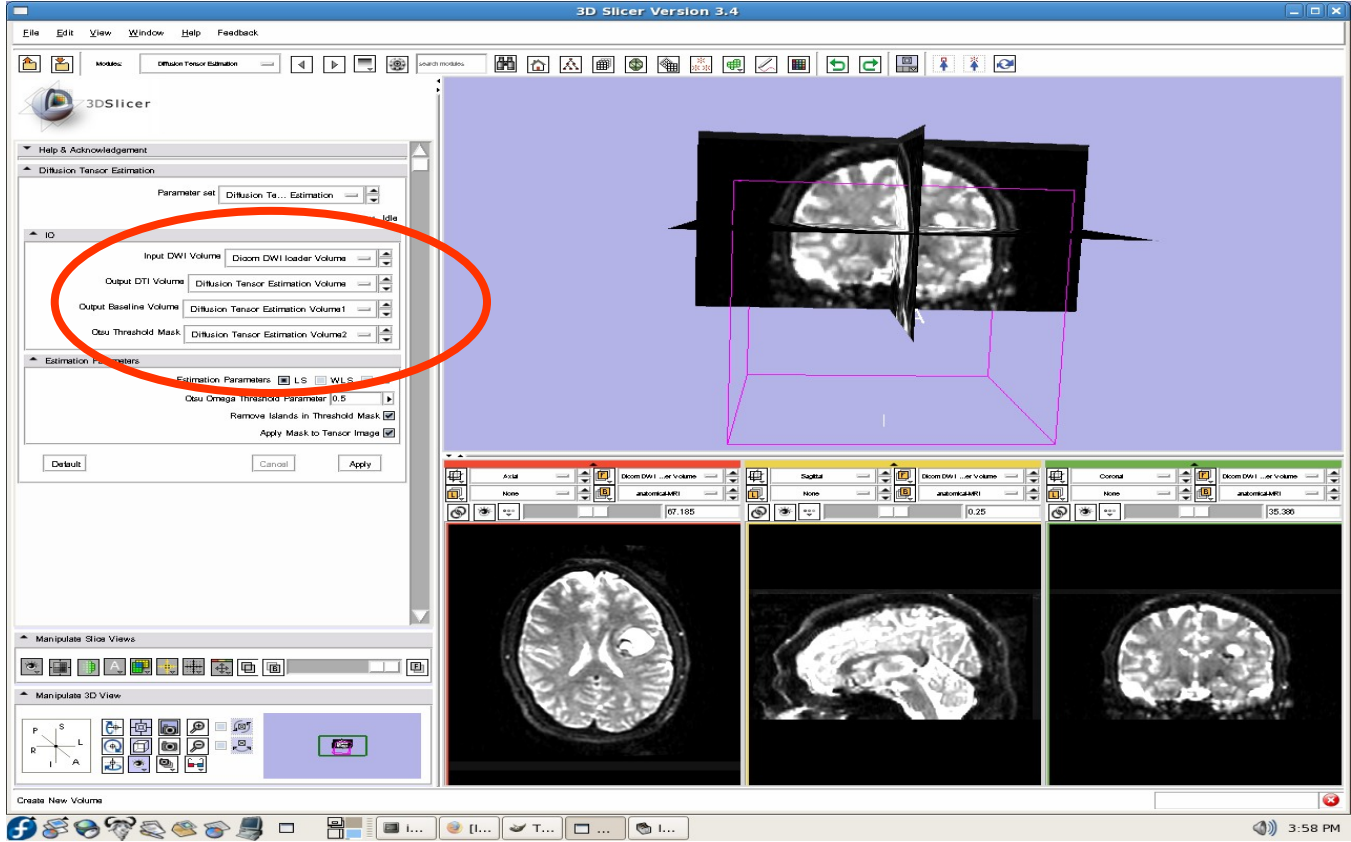




Create the tensors

Set the three “Output” fields to “Create New DiffusionTensorVolume”

You would click “Apply” to compute the tensors, but will upload a MRML scene of precomputed tensors because computing tensors takes a while



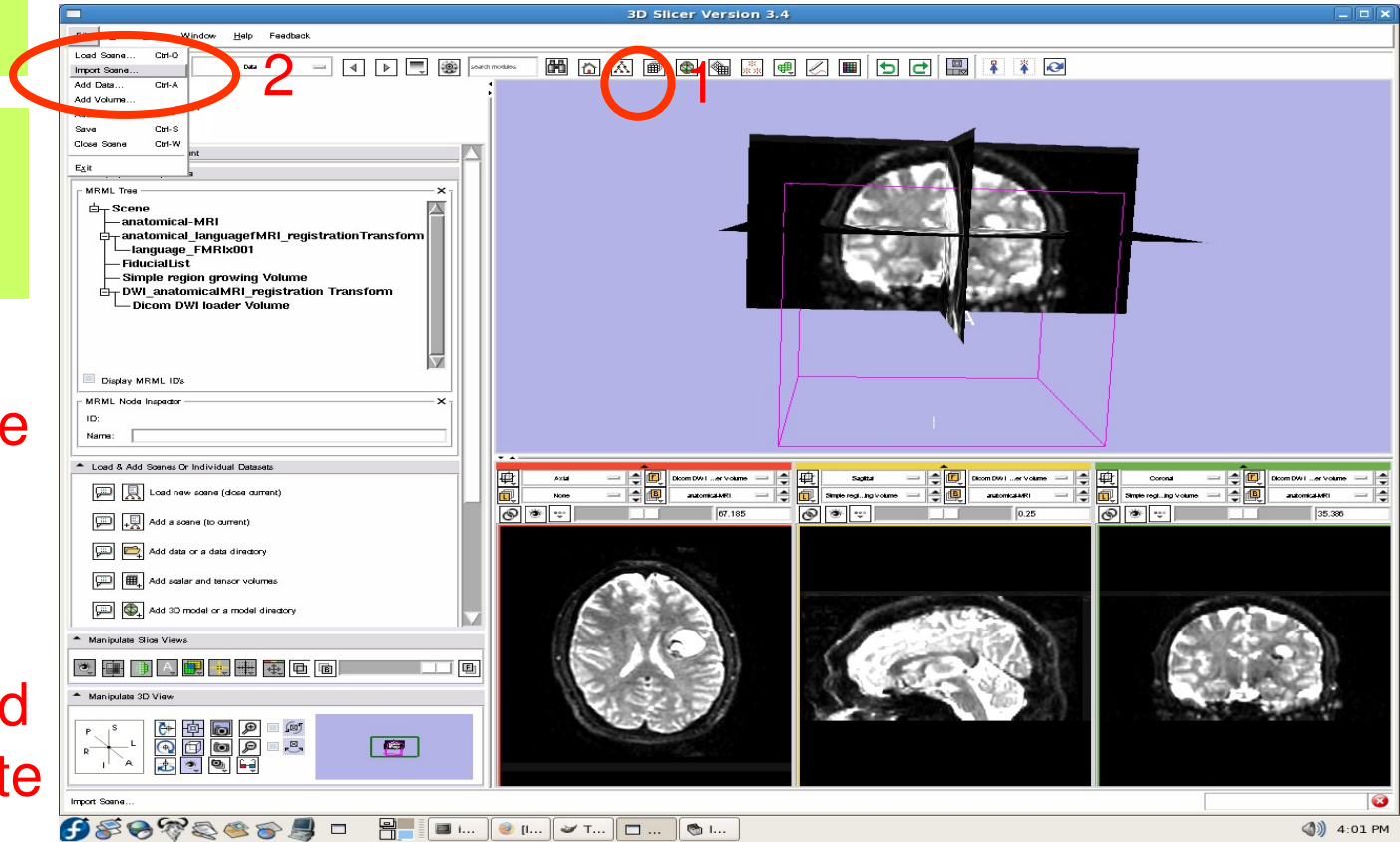


Create the tensors

Open the Data module

Select File -> Import Scene

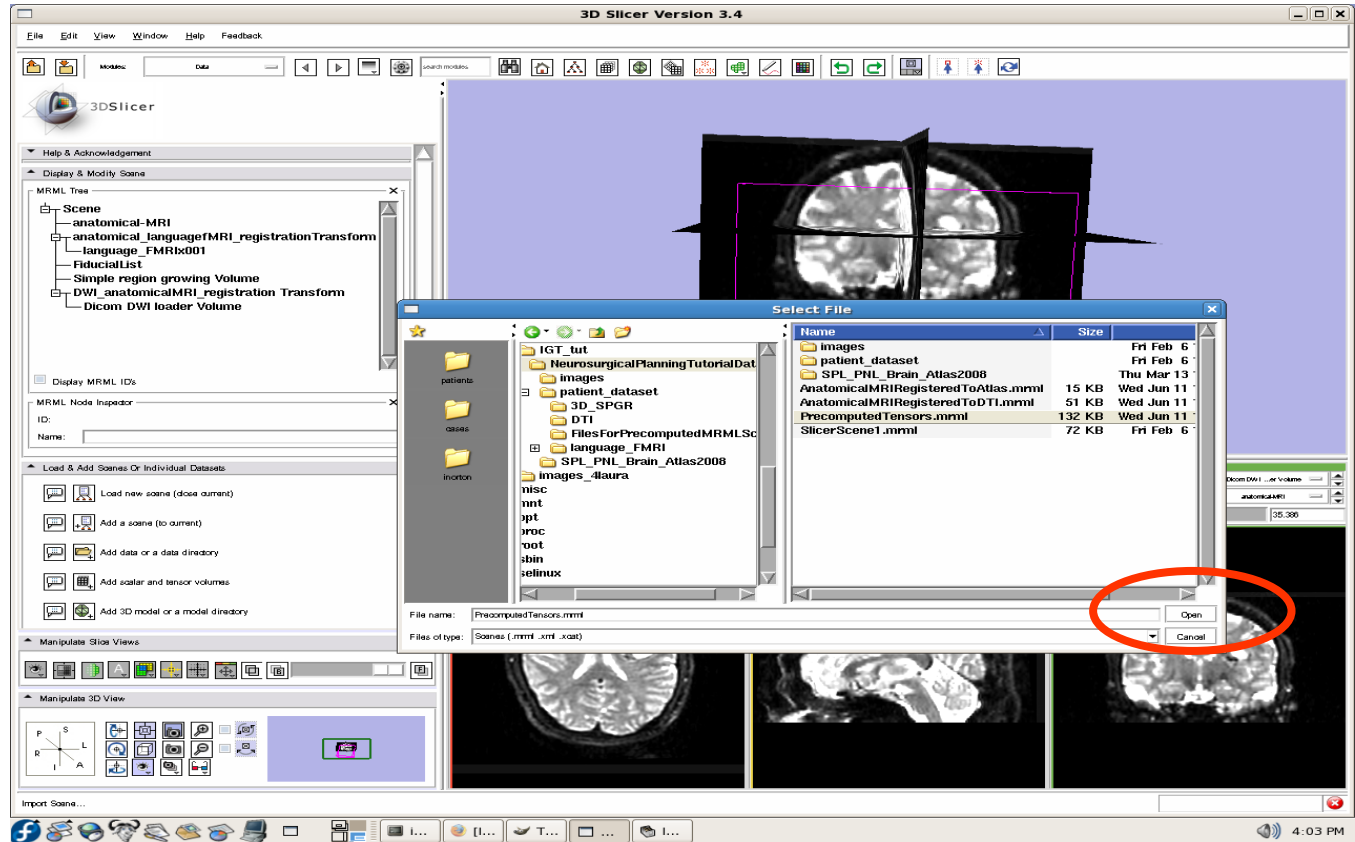
Note: Make sure that you select "Import Scene" and not "Load Scene", as "Load Scene" will delete your work so far





Create the tensors

Select
“precomputed
Tensors.mrml”,
then click
“Open”



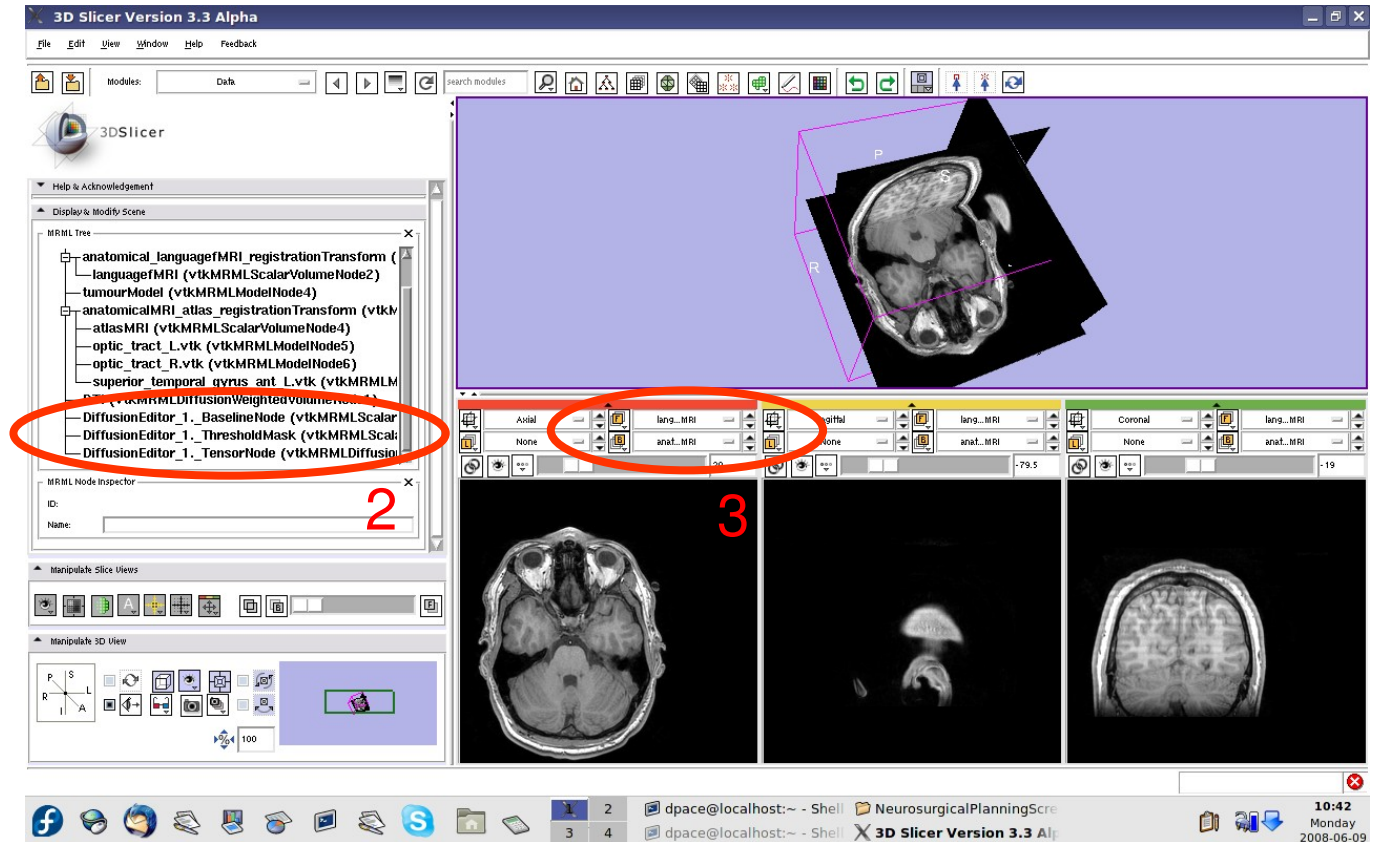


Create the tensors

3 new nodes:

- **Baseline Node:** image without diffusion weighting
- **Threshold Mask:** mask excluding the background
- **TensorNode** = the tensors

Set the background to the tensor node



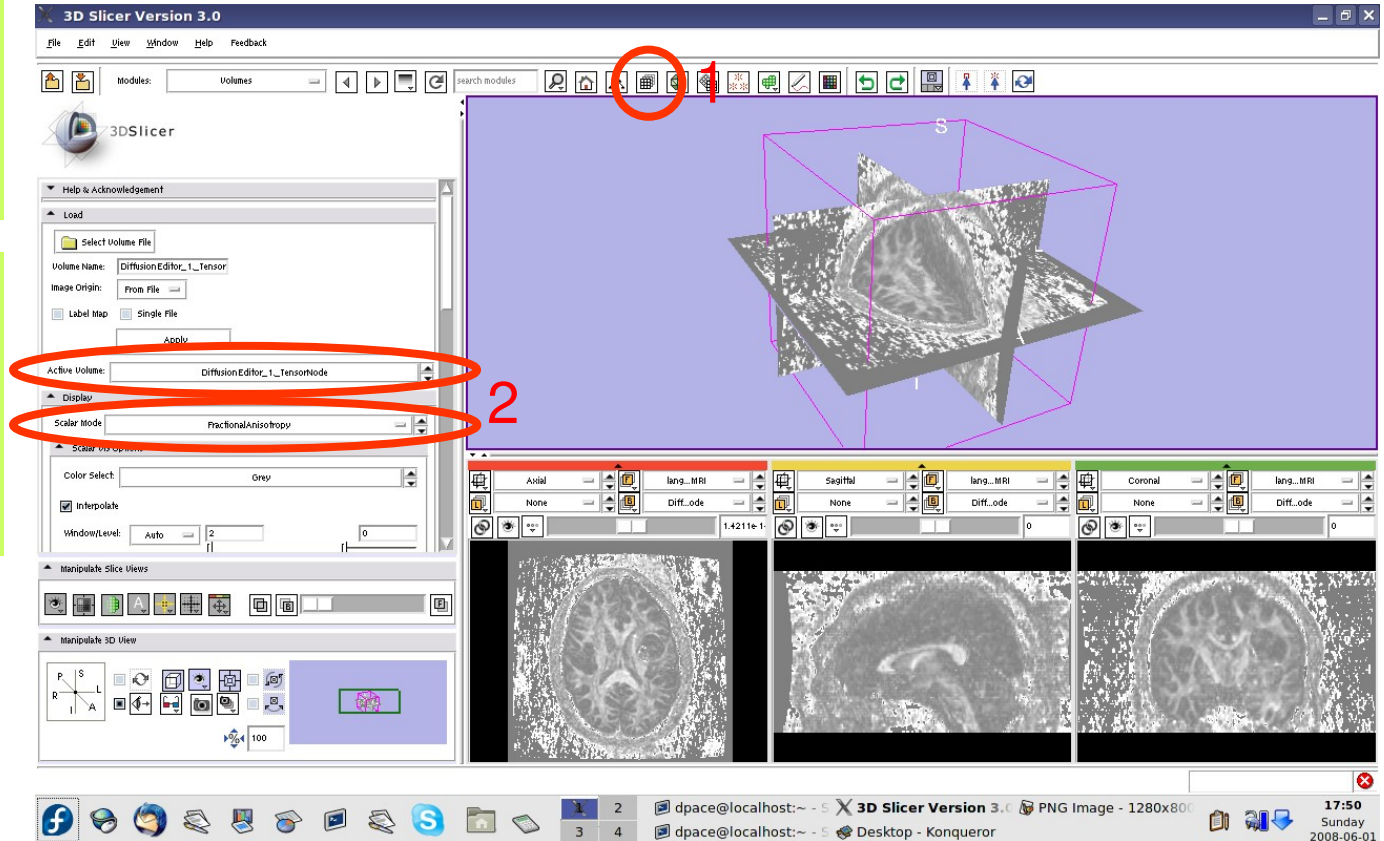


Create the tensors

Open the Volumes module

Set the active volume to the diffusion tensor node

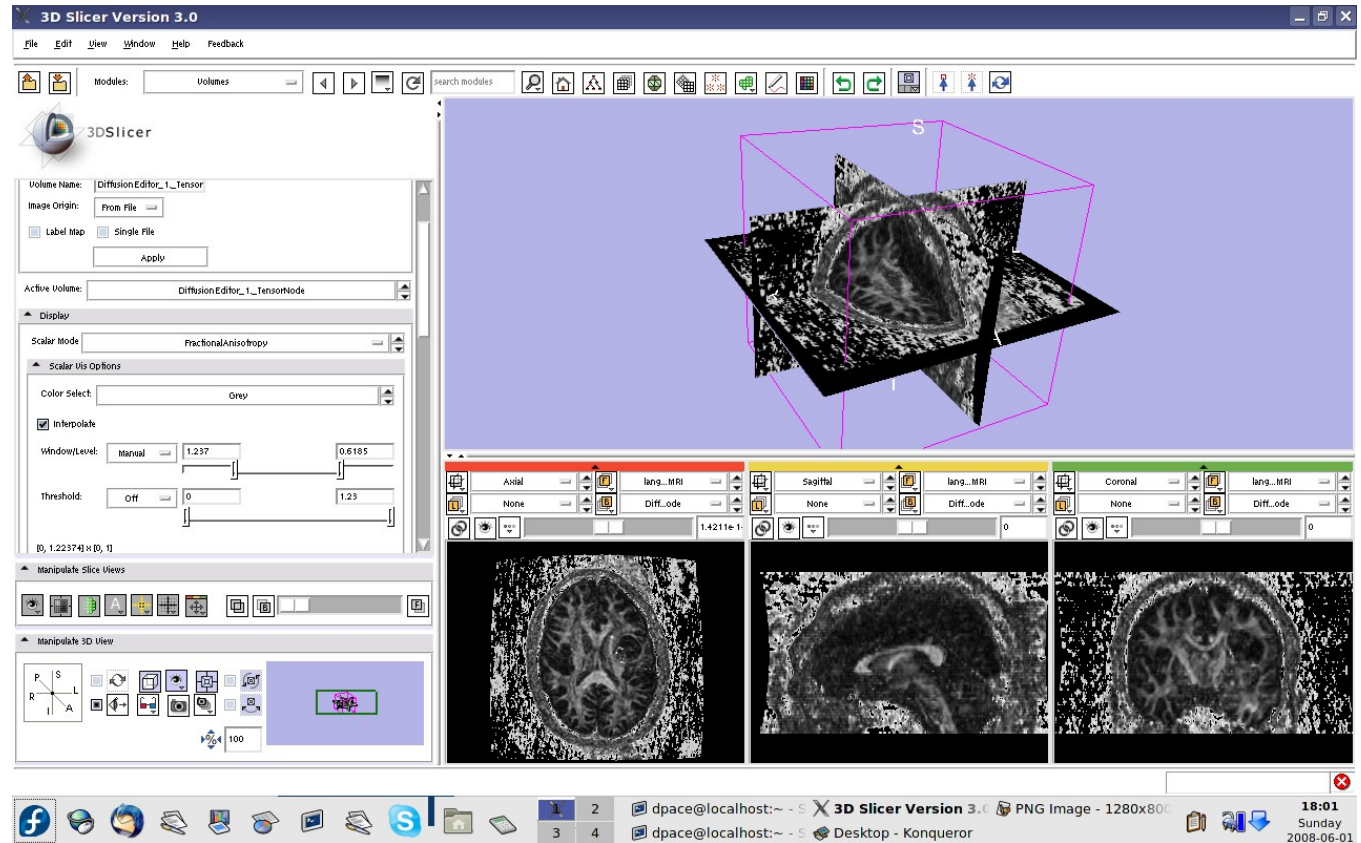
The fractional anisotropy is displayed by default





View the tensors

Set the Window/Level to Manual and adjust the levels to invert the image so that the tensors will be easier to see

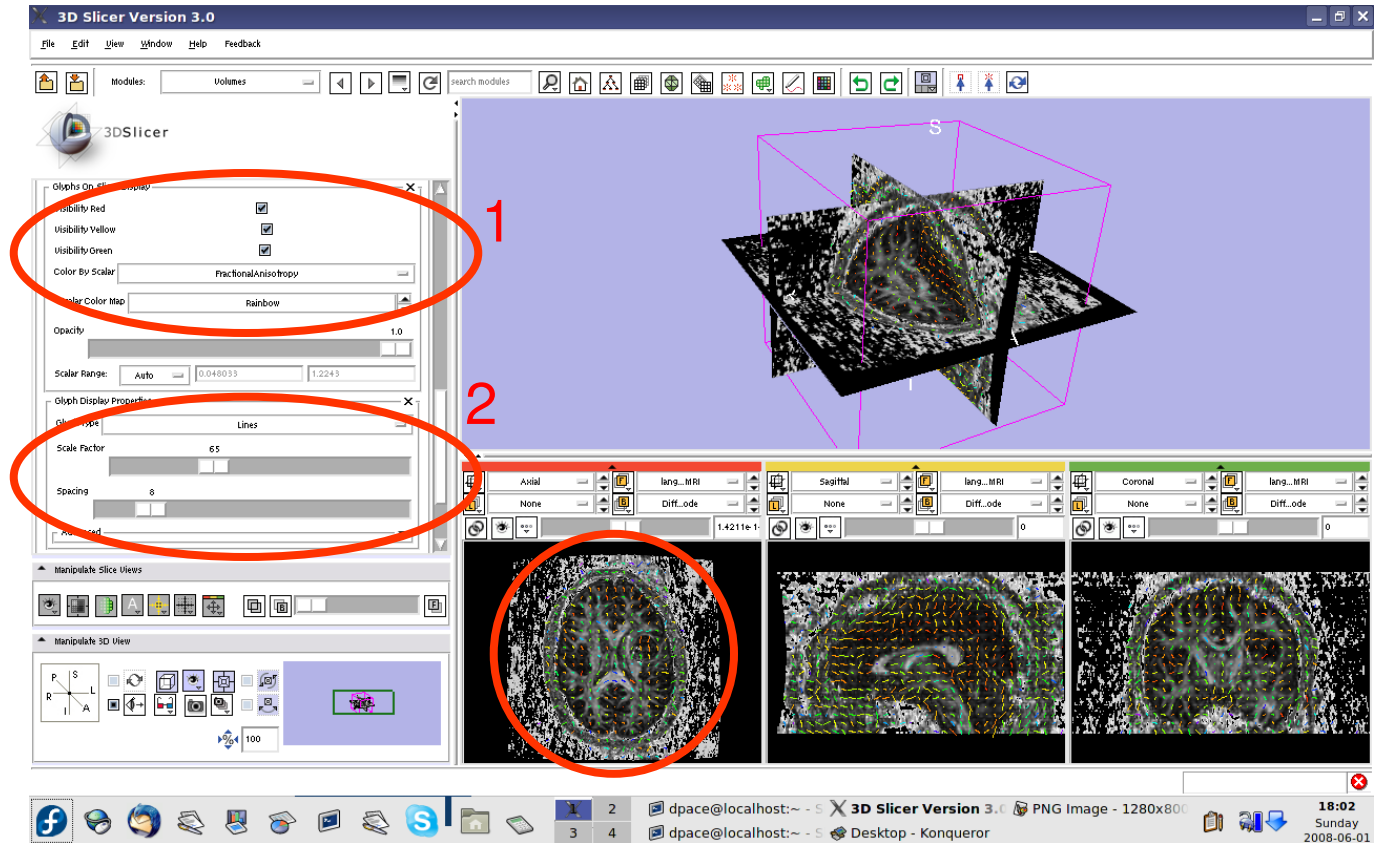




View the tensors

Scroll down and turn the glyphs on for all three views

Adjust the scale factor and the spacing



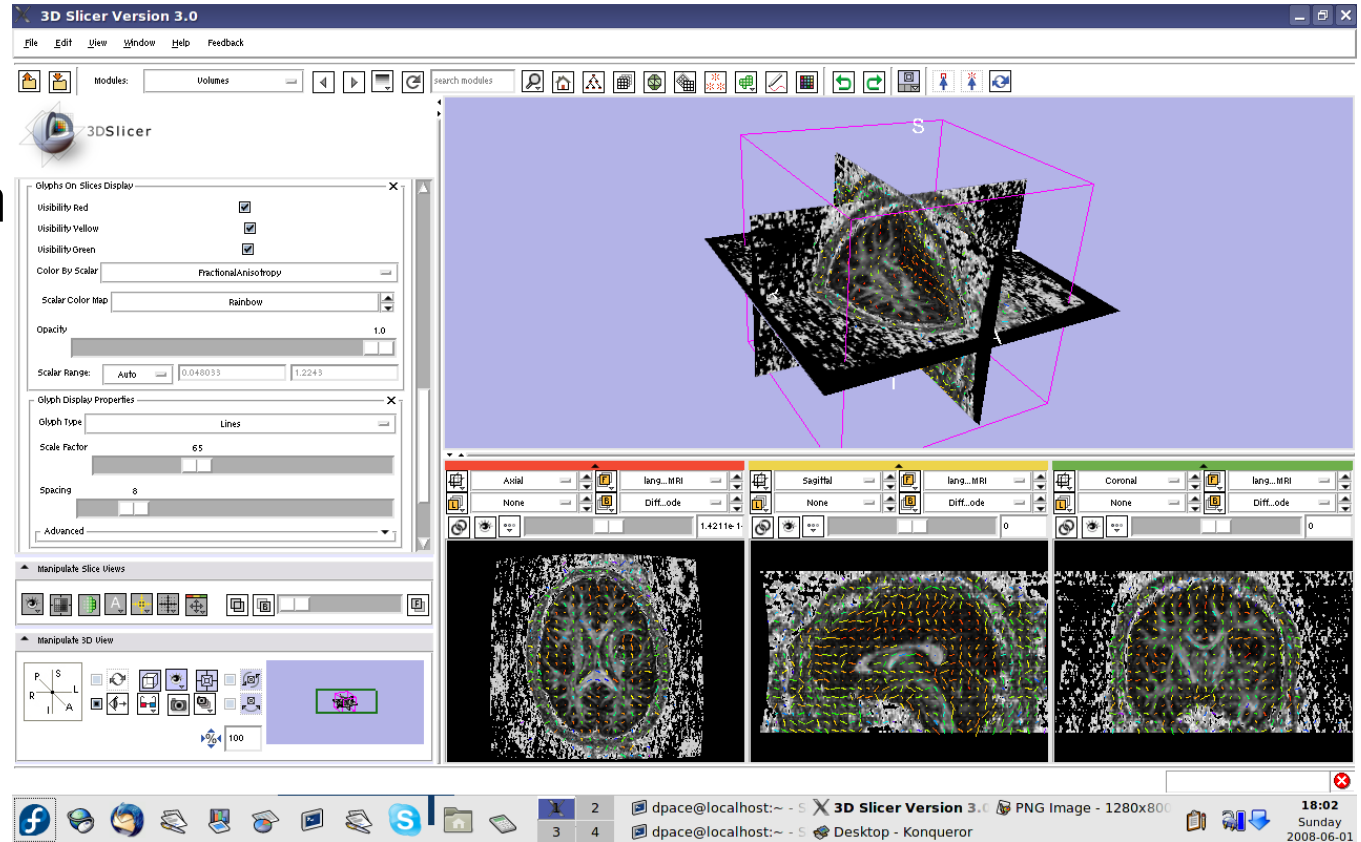


View the tensors

Line direction:
the direction of
the tensor's main
eigenvector

Line magnitude:
the magnitude of
the diffusion

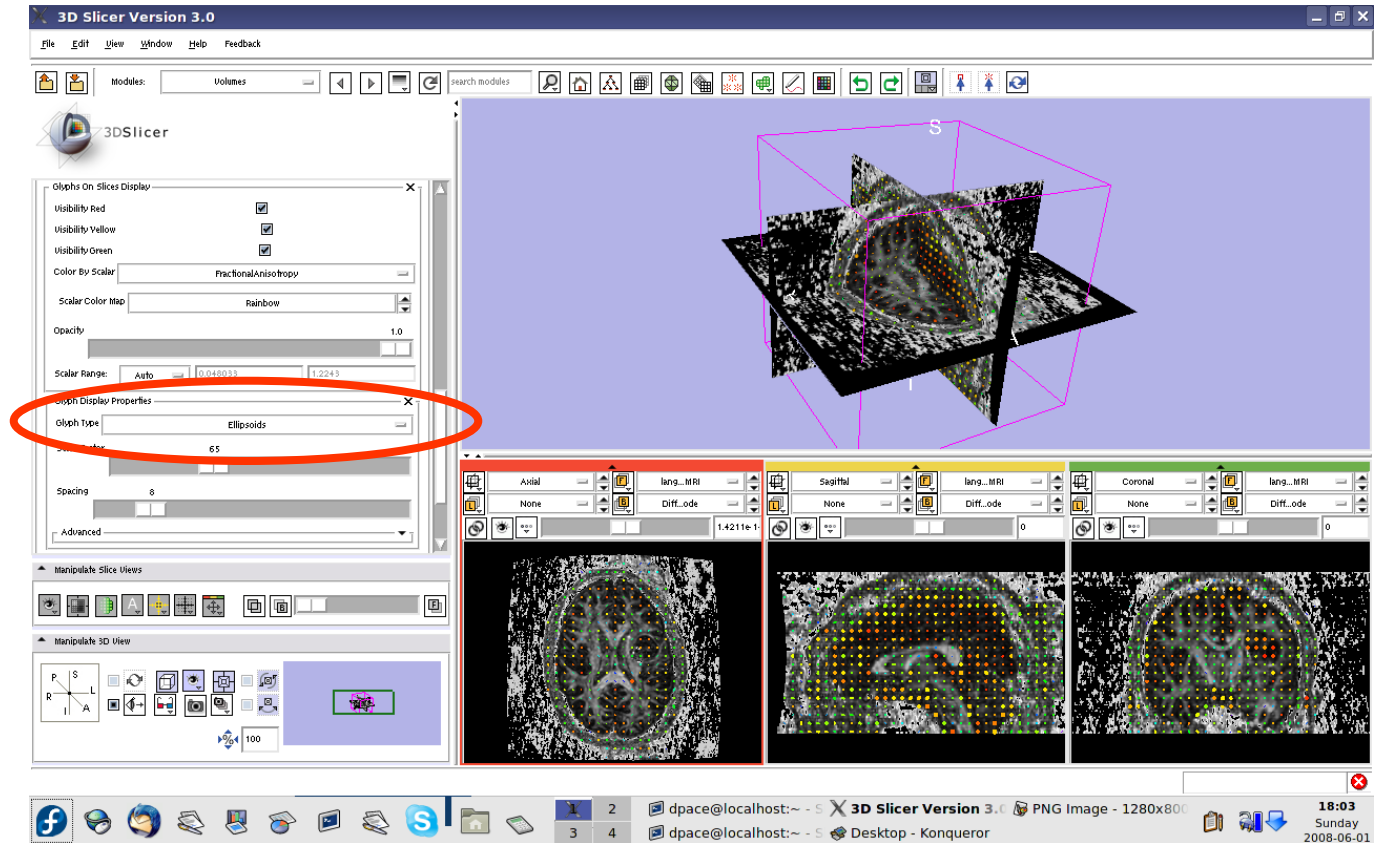
Line colour:
fractional
anisotropy





View the tensors

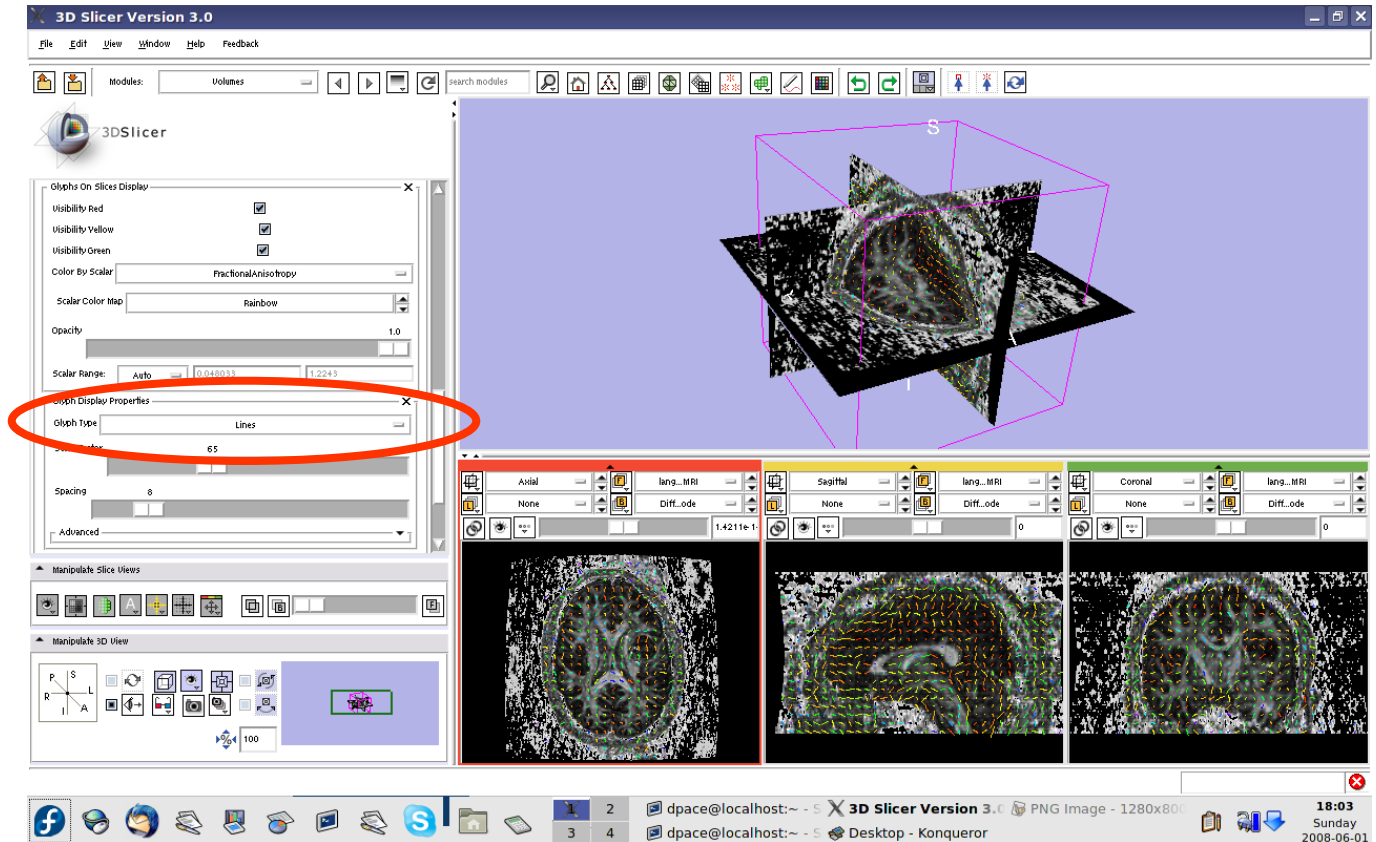
Change the Glyph Type to "Ellipsoids"





View the tensors

Change the
Glyph Type back
to “Lines”

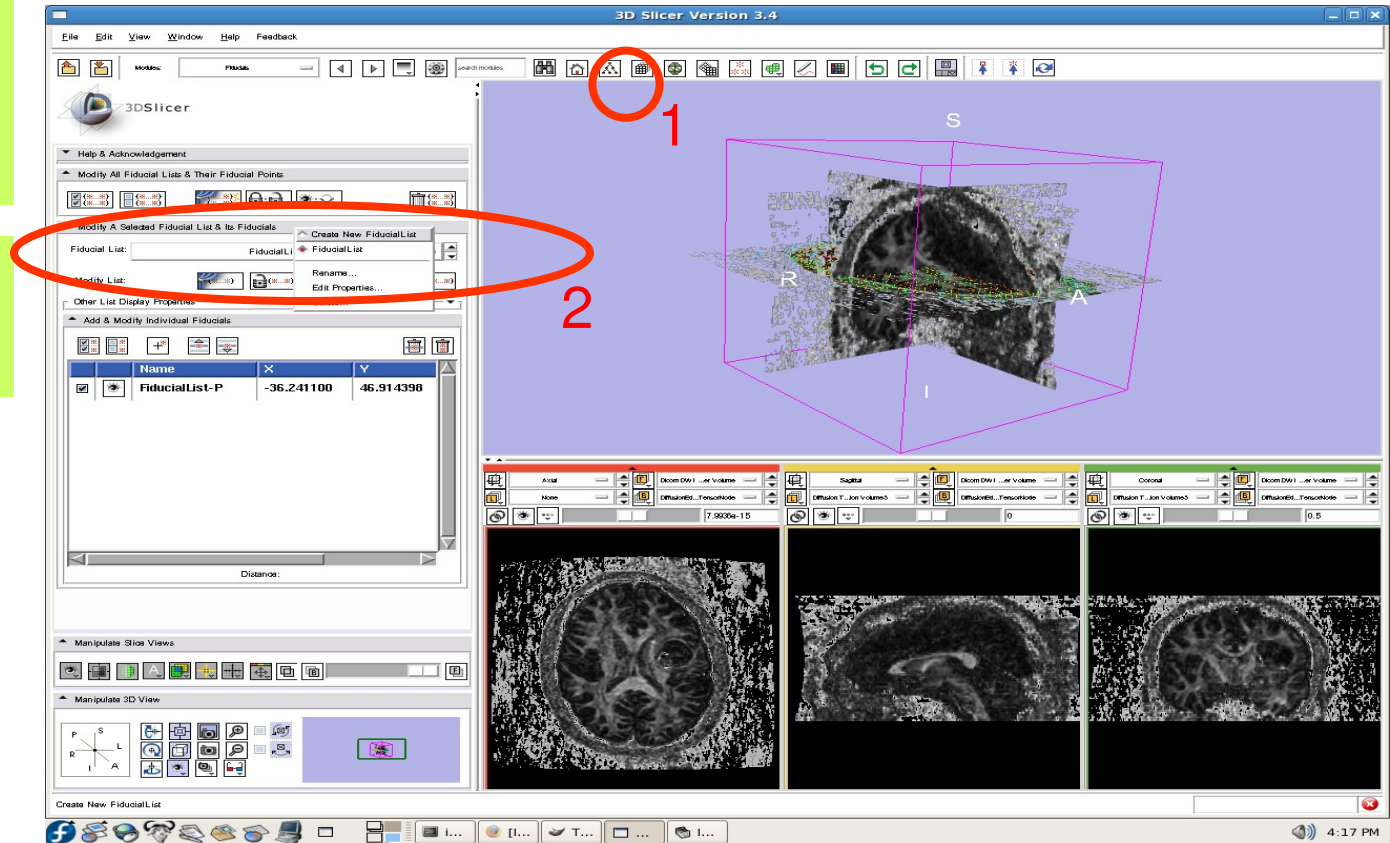




Place the tractography seed points

Open the
Fiducials
module

Create a new
Fiducial List

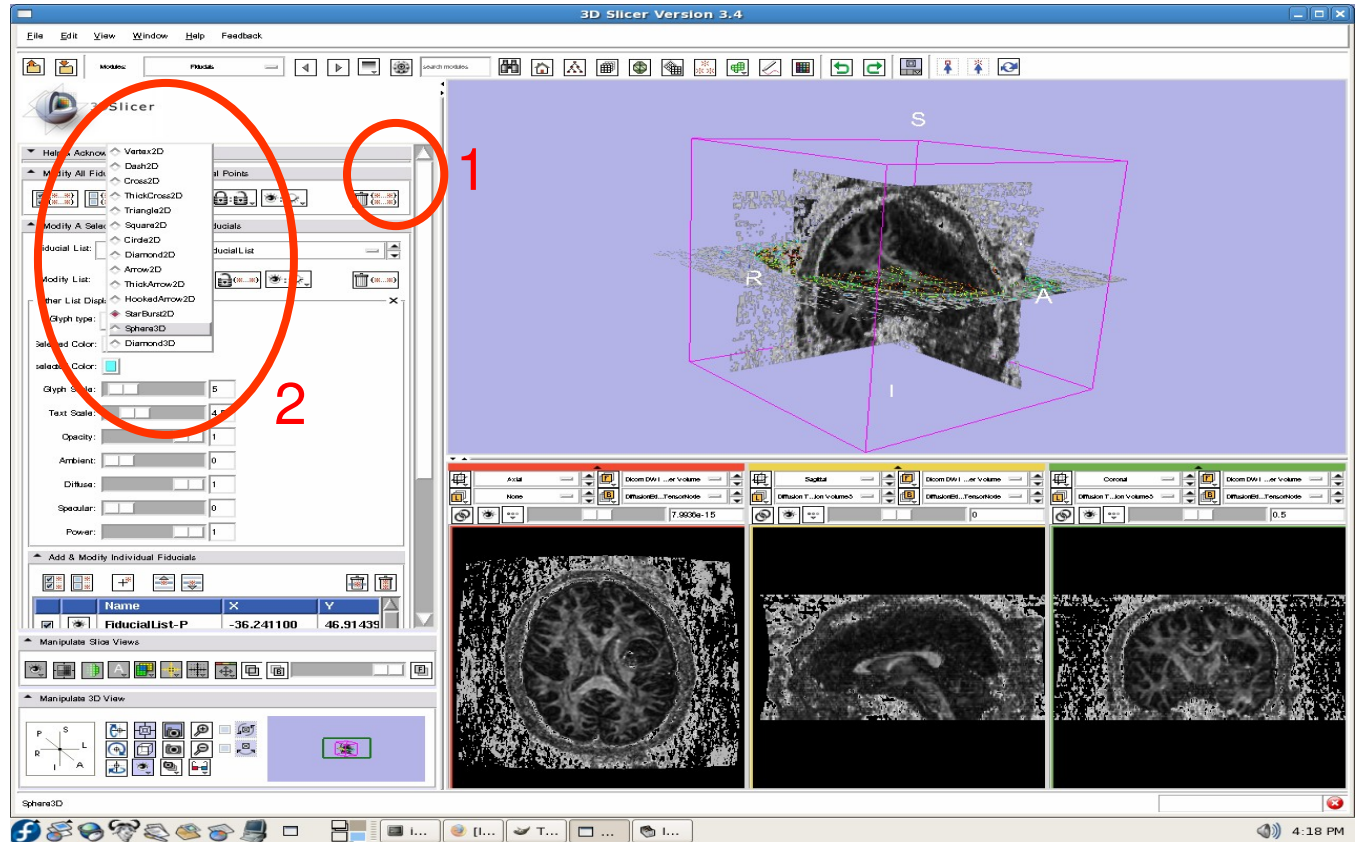




Place the tractography seed points

Expand “Other Display List Properties.”

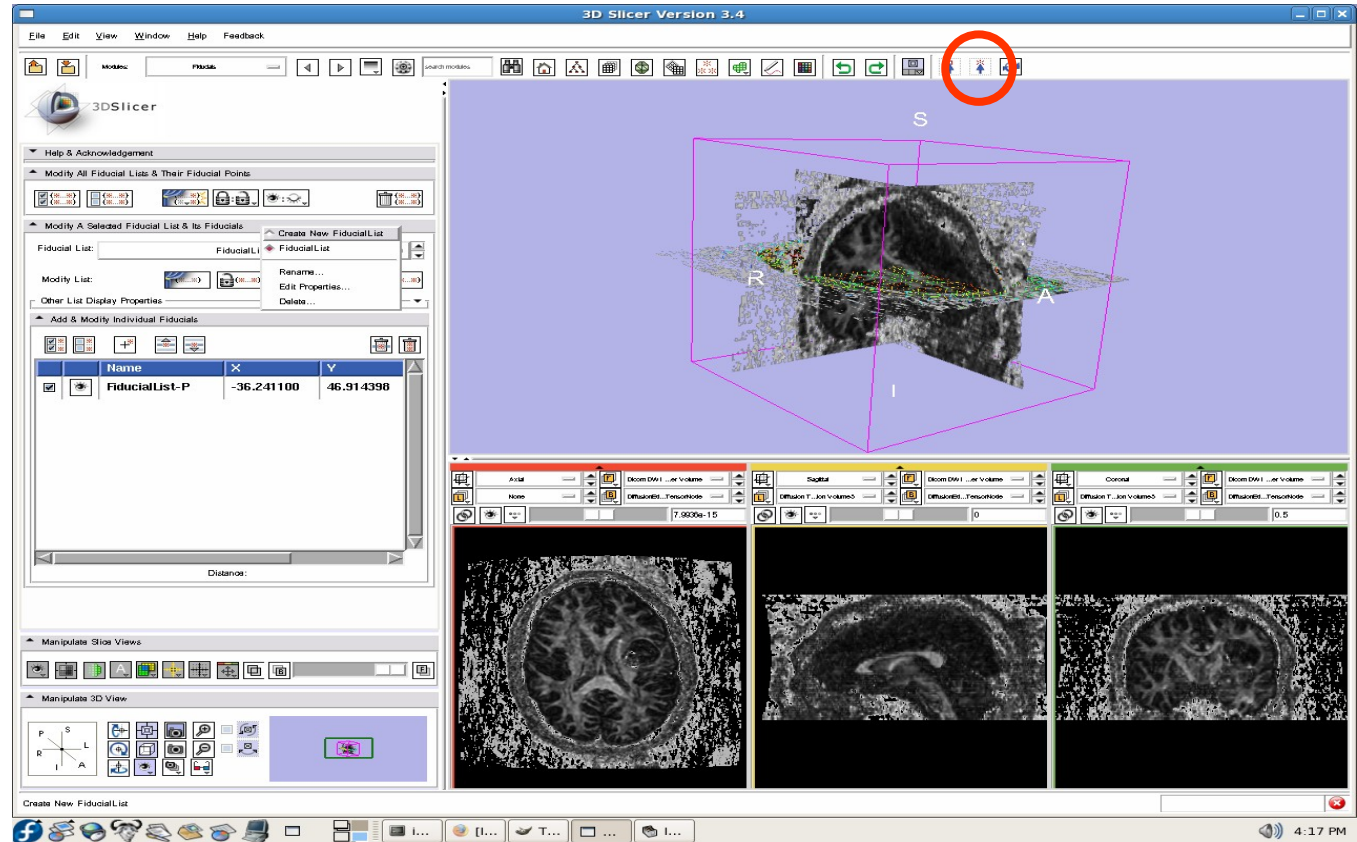
Set the glyph type to Sphere3D





Place the tractography seed points

Set the mouse mode to “place items”

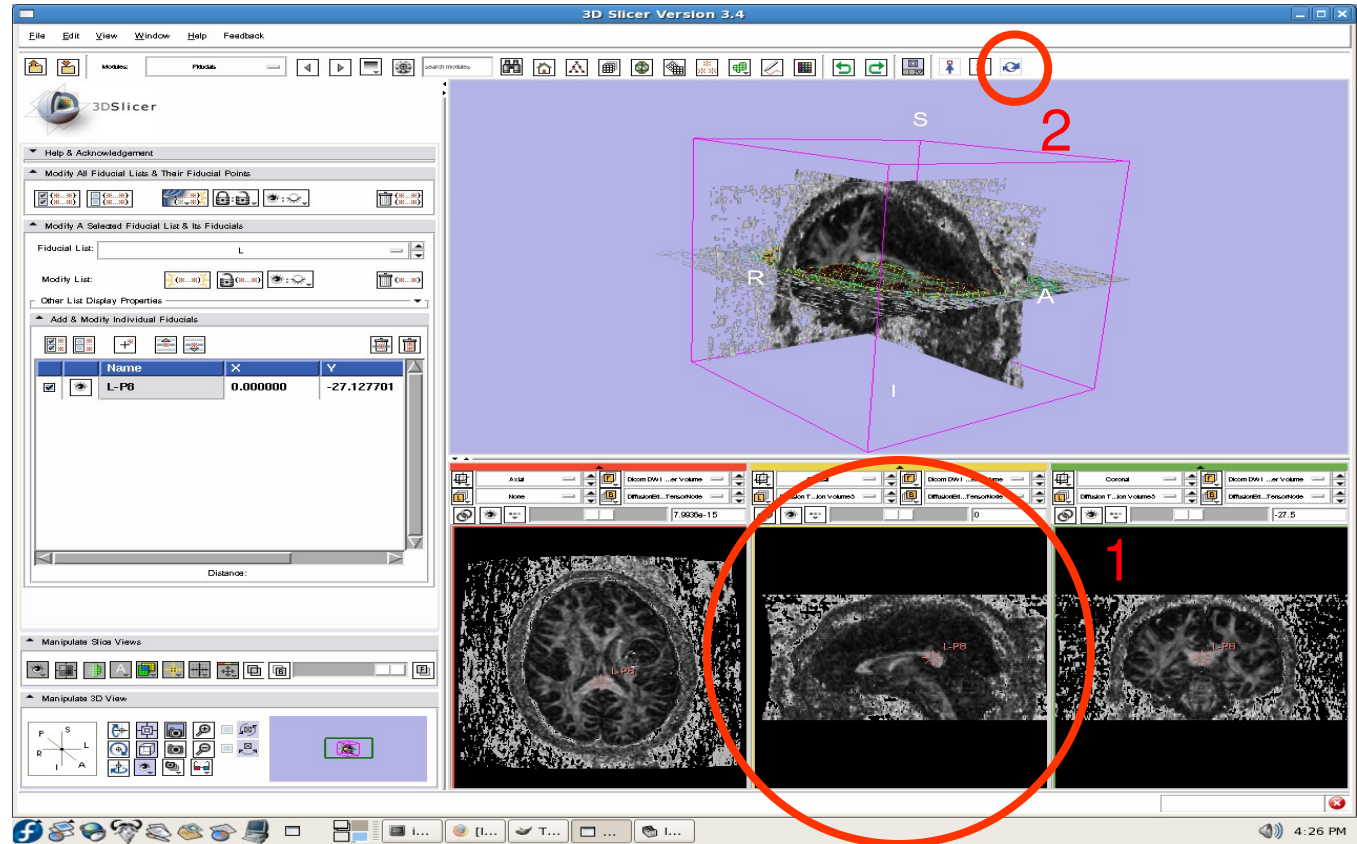




Place the tractography seed points

Click to place one fiducial point in the corpus callosum

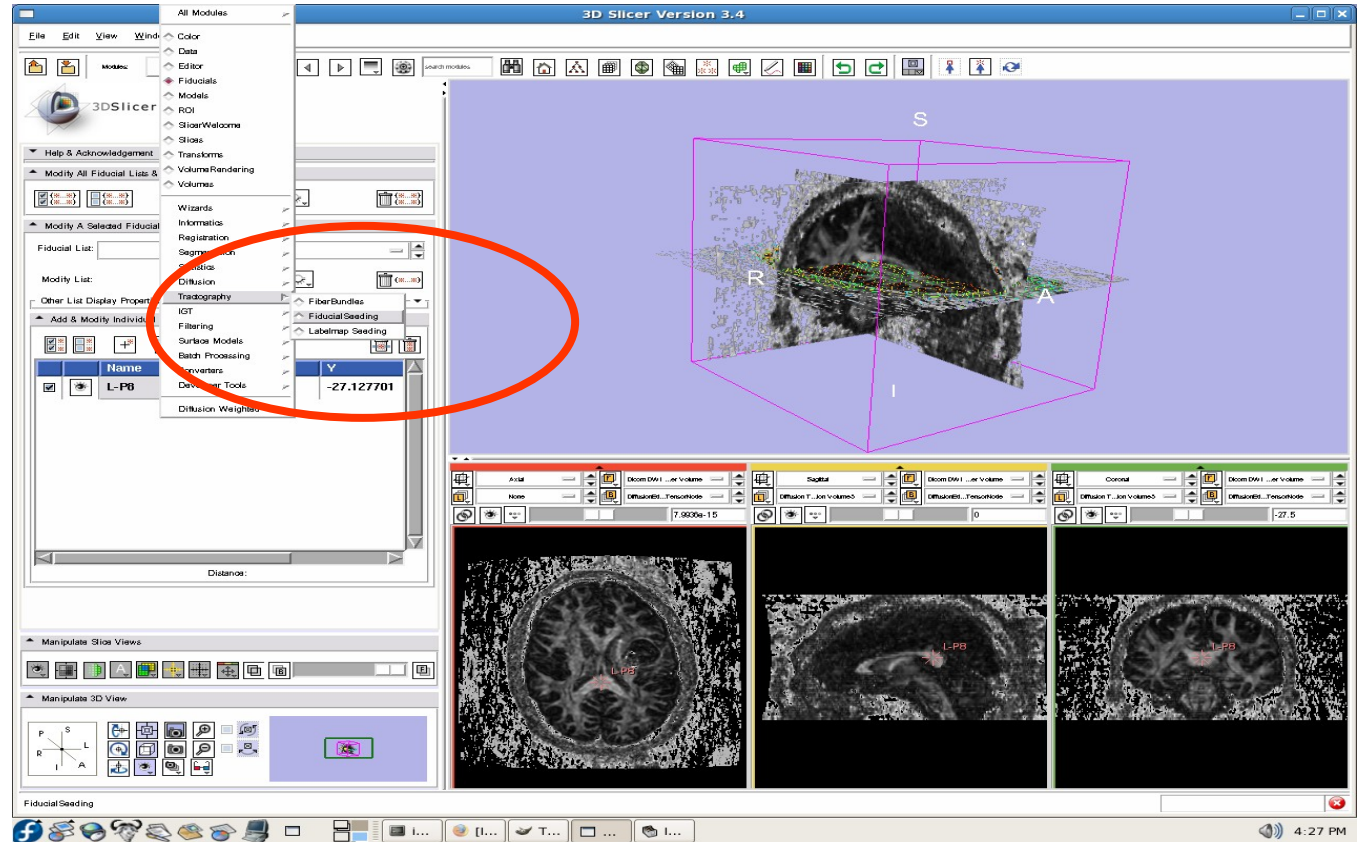
Set the mouse mode to “transform view”





Perform tractography (fiber tracking)

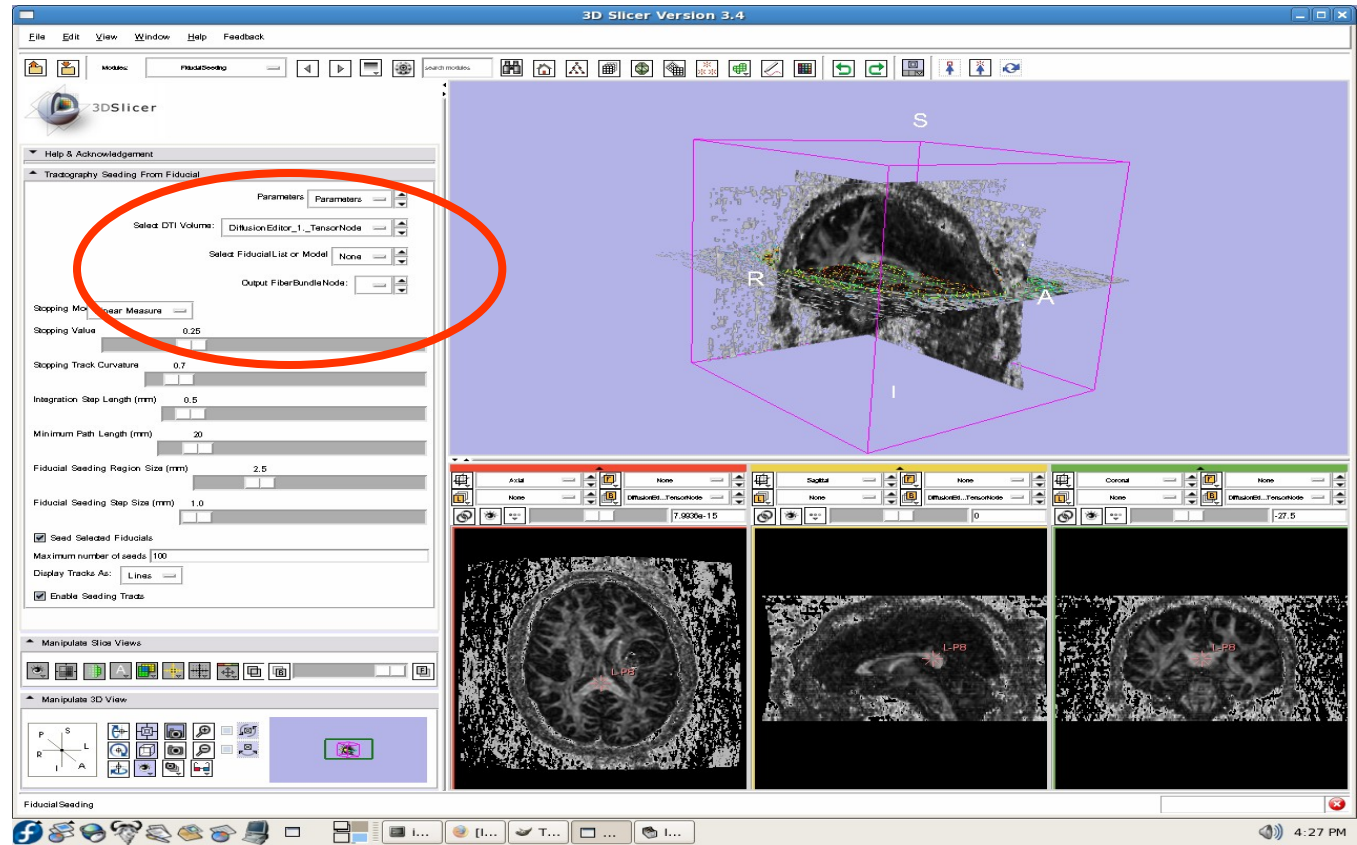
Open the tractography “Fiducial Seeding” module





Perform tractography (fiber tracking)

- DTI volume = Diffusion Editor_1_TensorNode
- Fiducial list = FiducialList2
- Output FiberBundle Node = Create New Fiber Bundle



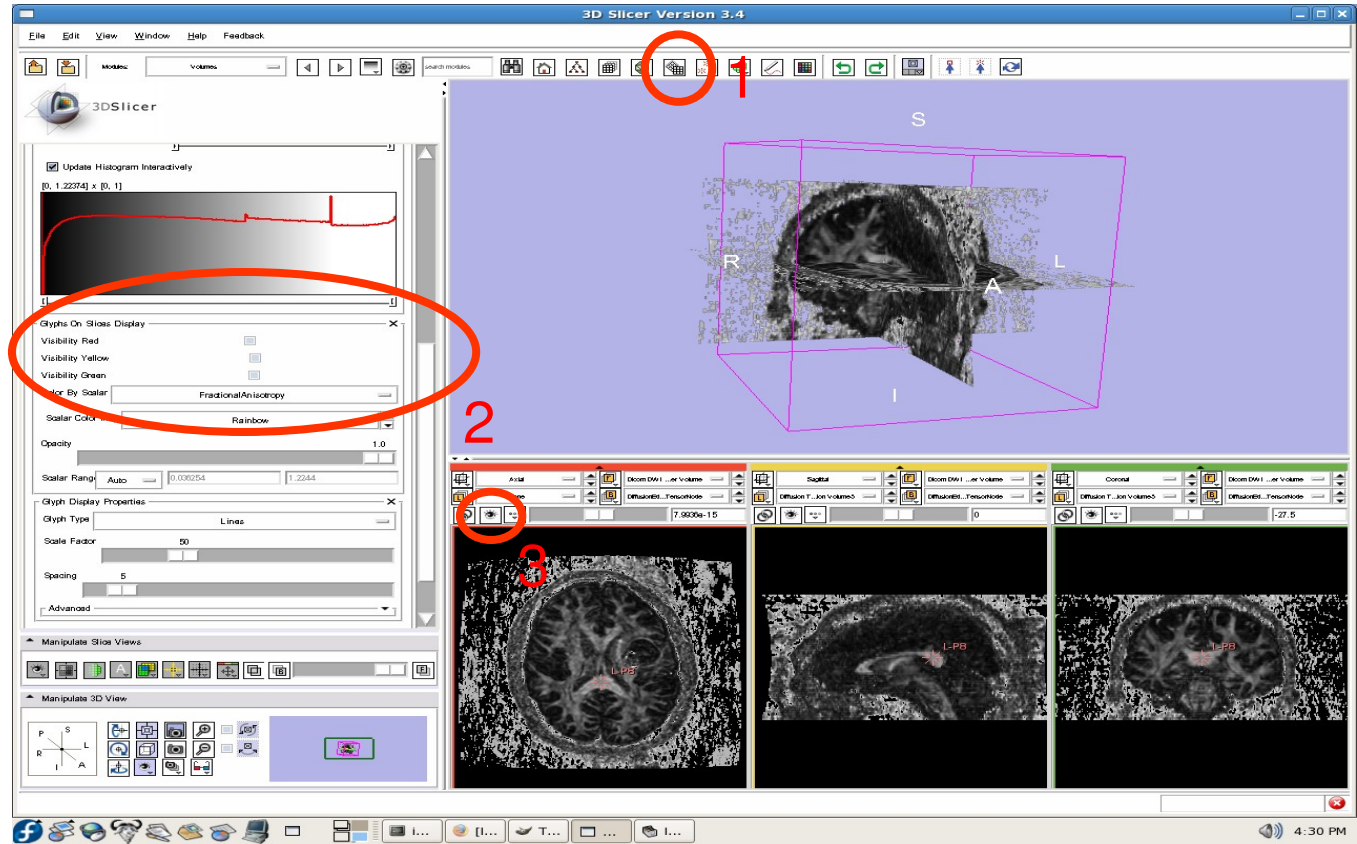


Perform tractography (fiber tracking)

Open the Volumes module

Turn the glyphs off for all three views

Click on the “visibility” button to turn off the slice visibility



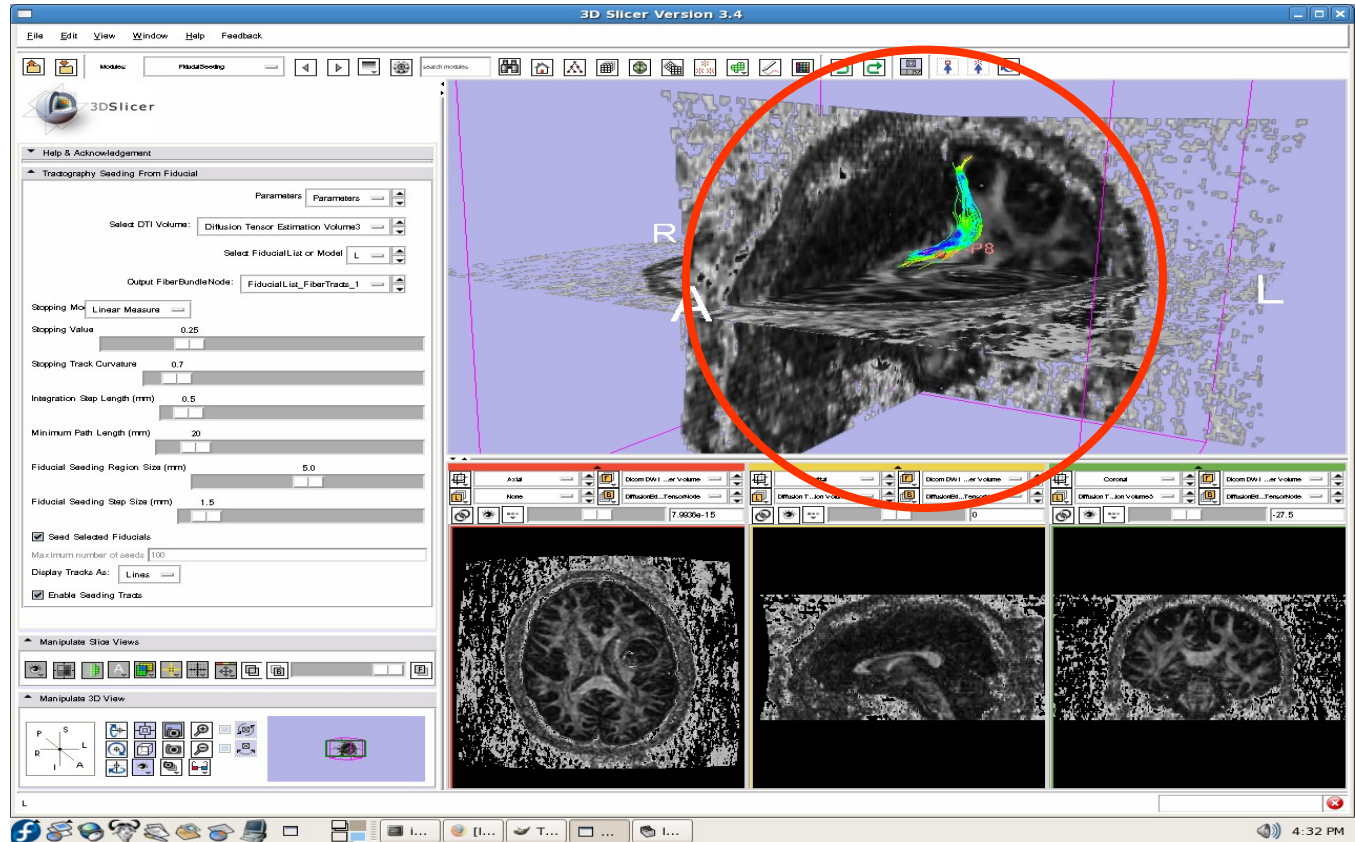


Perform tractography (fiber tracking)

One tract is generated for each fiducial

The tract colour is the fractional anisotropy by default.

Click and drag the pink sphere in 3D view to interactively select tracts.

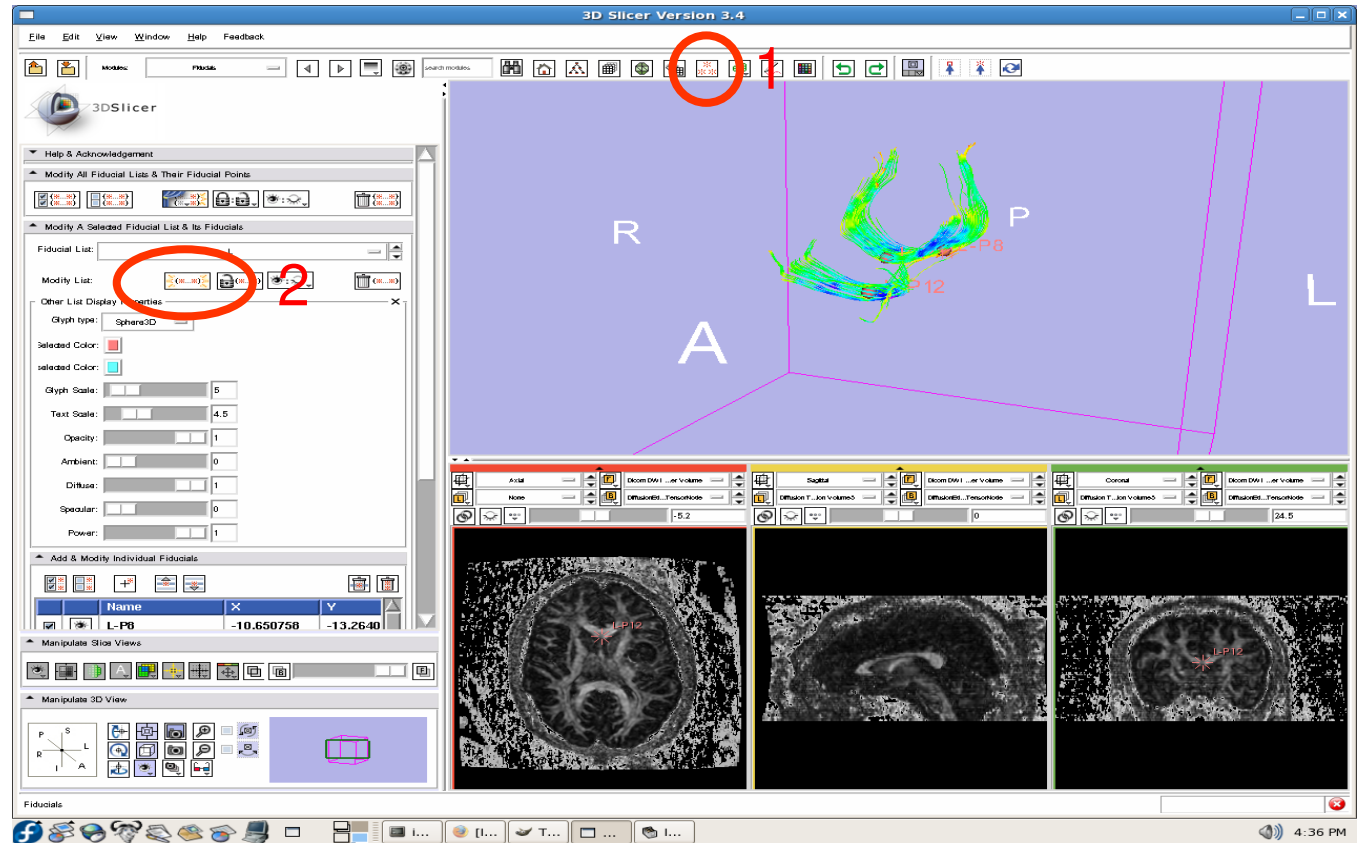




Perform tractography (fiber tracking)

Open the
Fiducials
module

Turn off the
visibility of the
fiducials

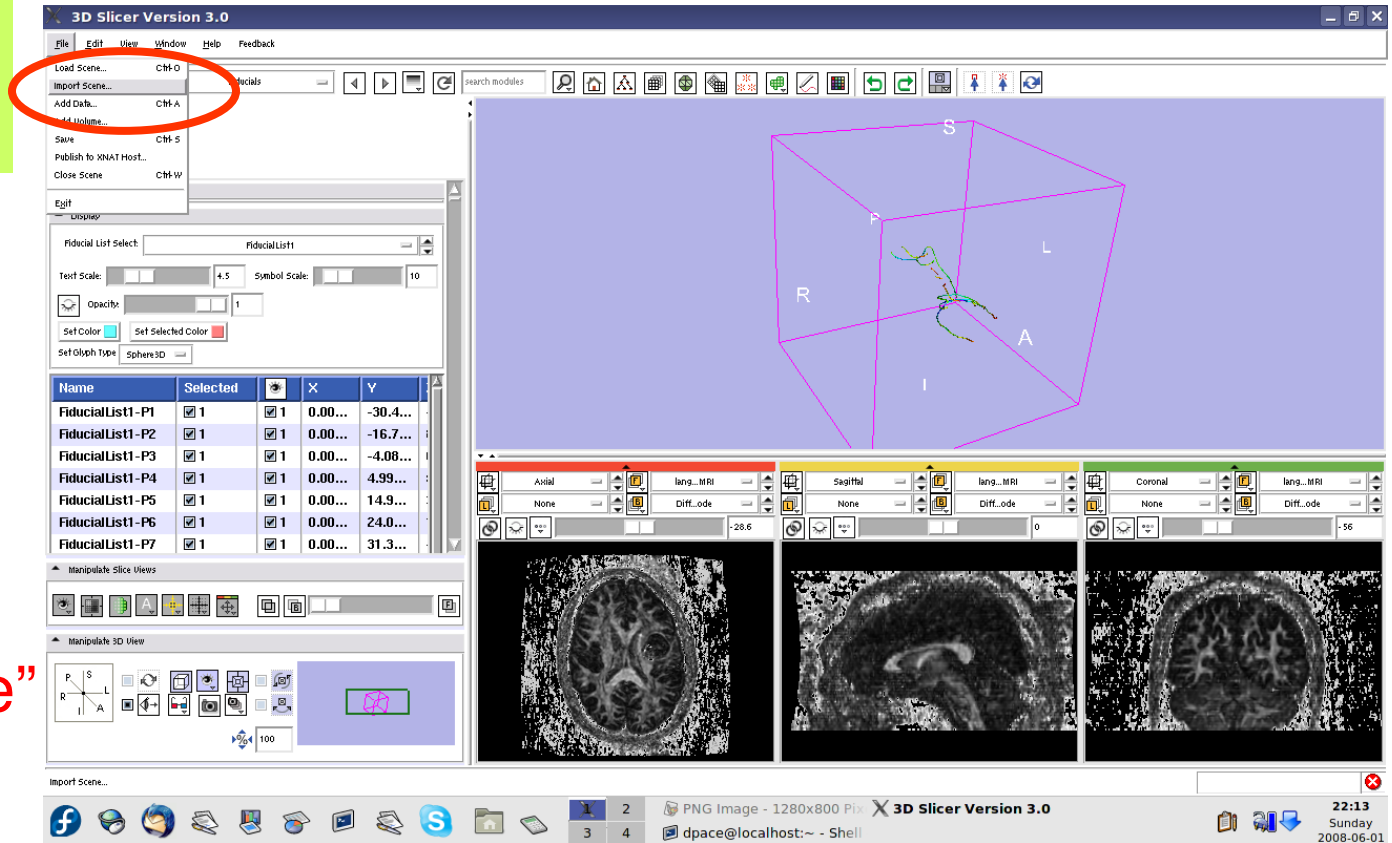




Import the anatomical-DTI registration transform

Select File -> Import Scene

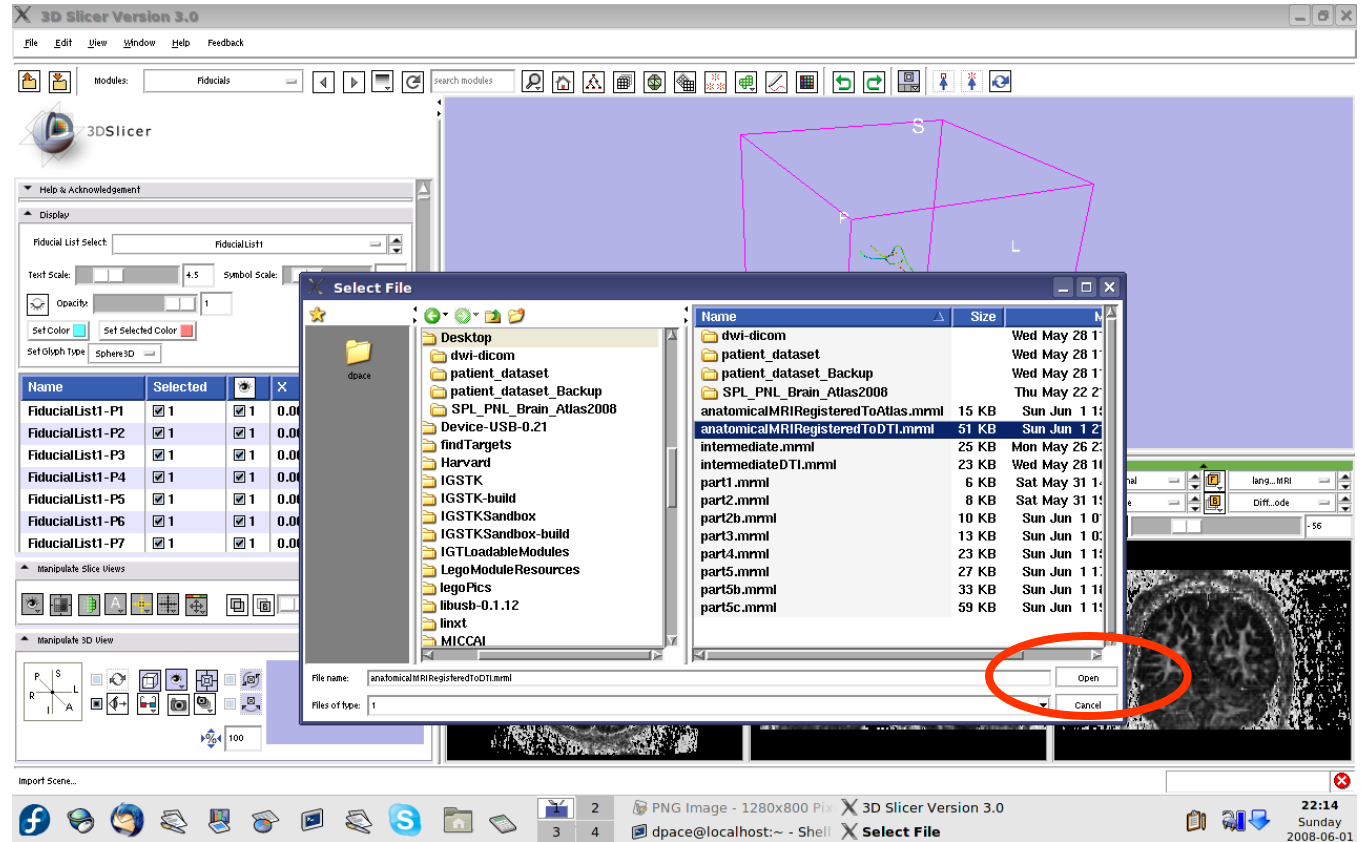
Note: Make sure that you select “Import Scene” and not “Load Scene”, as “Load Scene” will delete your work so far





Import the anatomical-DTI registration transform

Select
“anatomical
MRI Registered
ToDTI.mrml”,
then click
“Open”



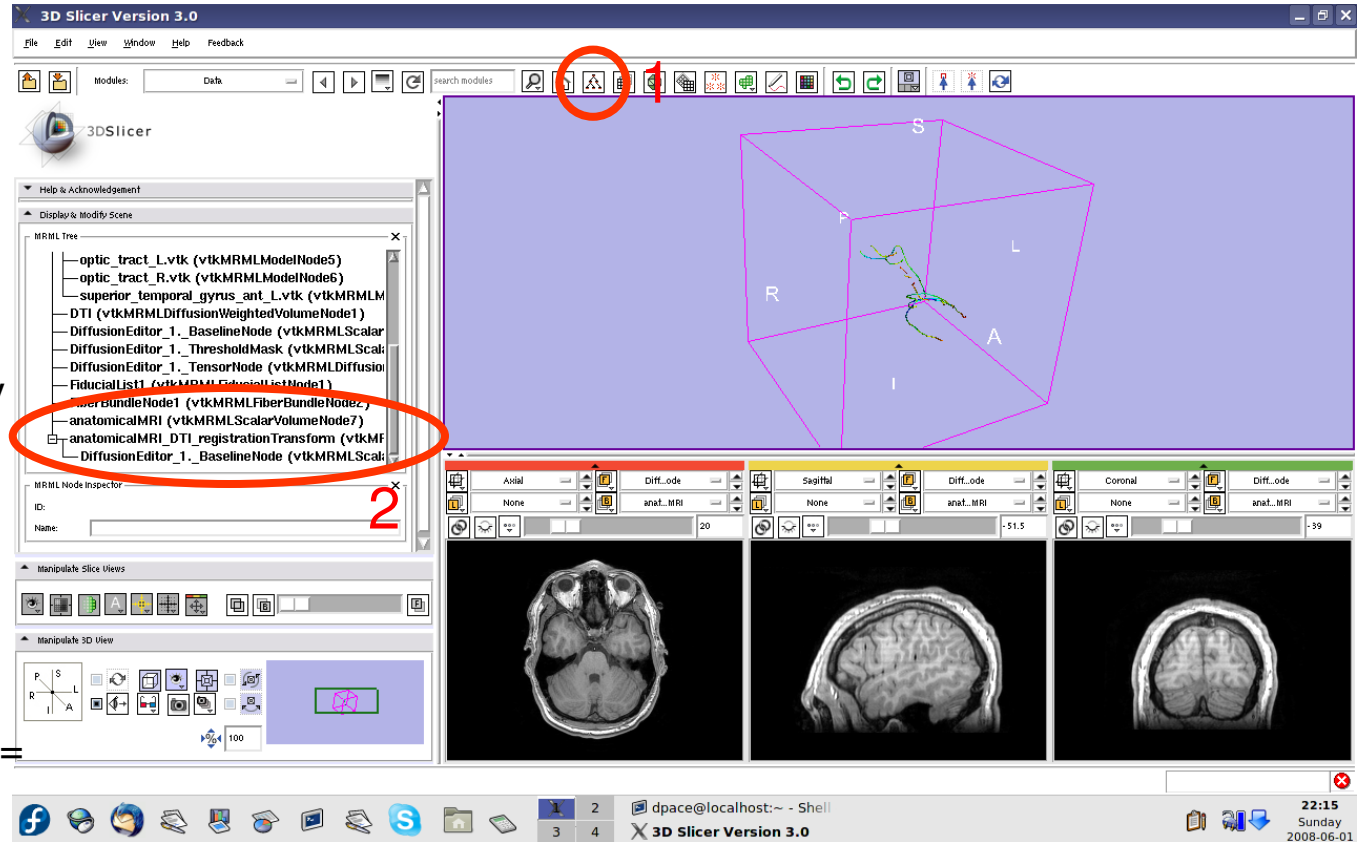


Inspect the MRML scene

Open the Data module

Inspect the atlas MRML scene - 3 new nodes

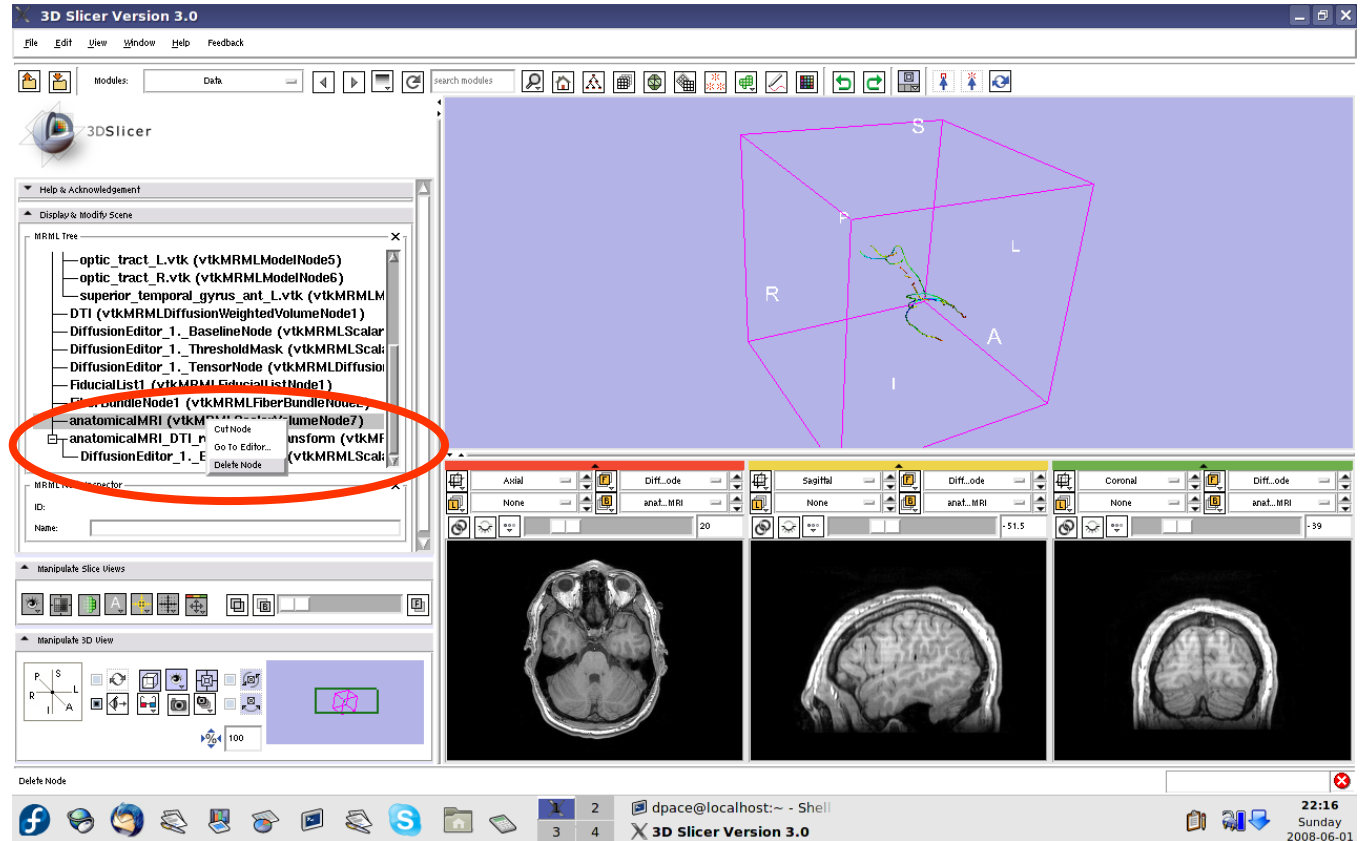
- anatomicalMRI = copy of the patient's anatomical MRI
- BaselineNode = copy of the patient's DTI baseline node
- anatomicalMRI_DTI_registrationTransform = aligns the DTI images with the anatomical image





Inspect the MRML scene

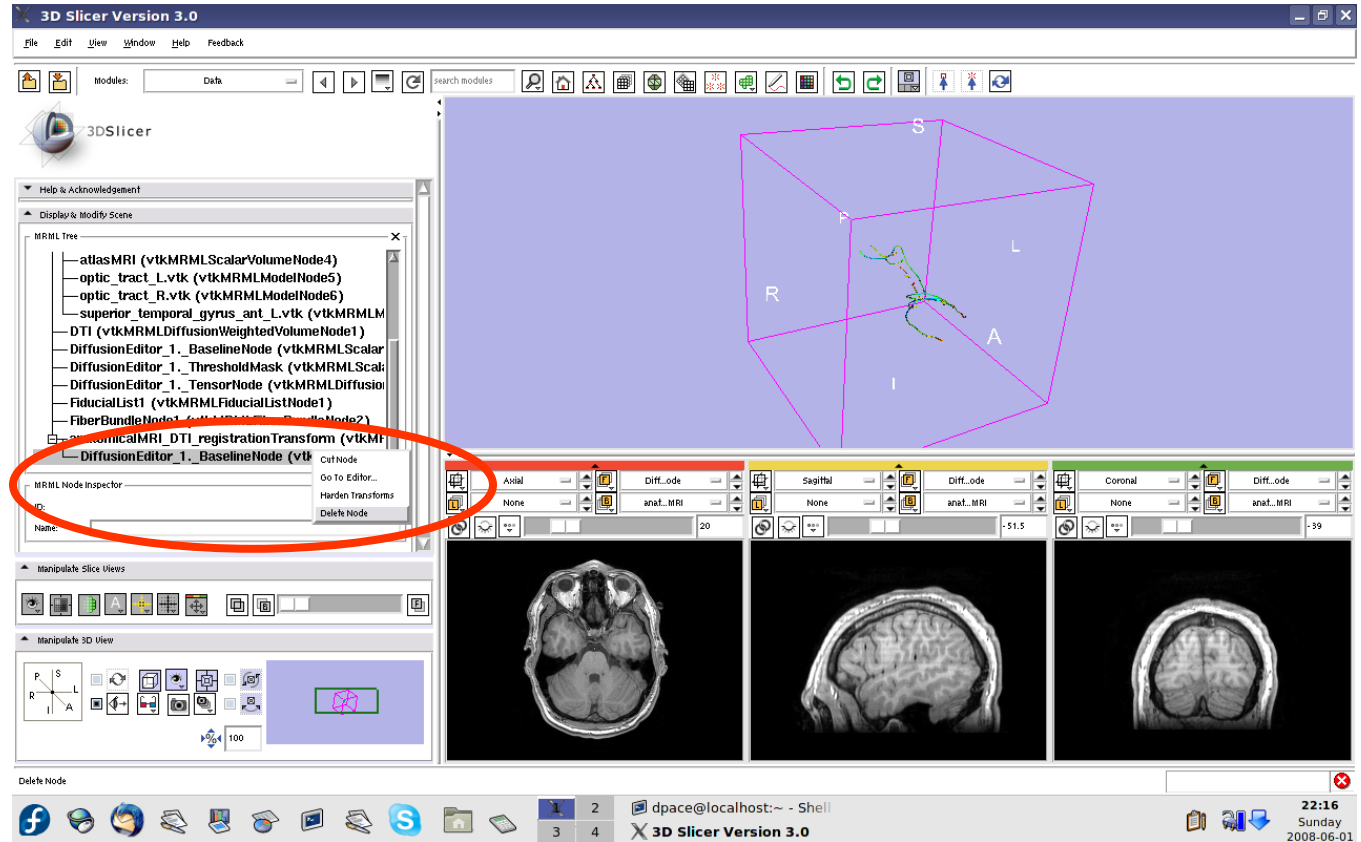
Delete the duplicate anatomicalMRI node by right-clicking and selecting “Delete Node”





Inspect the MRML scene

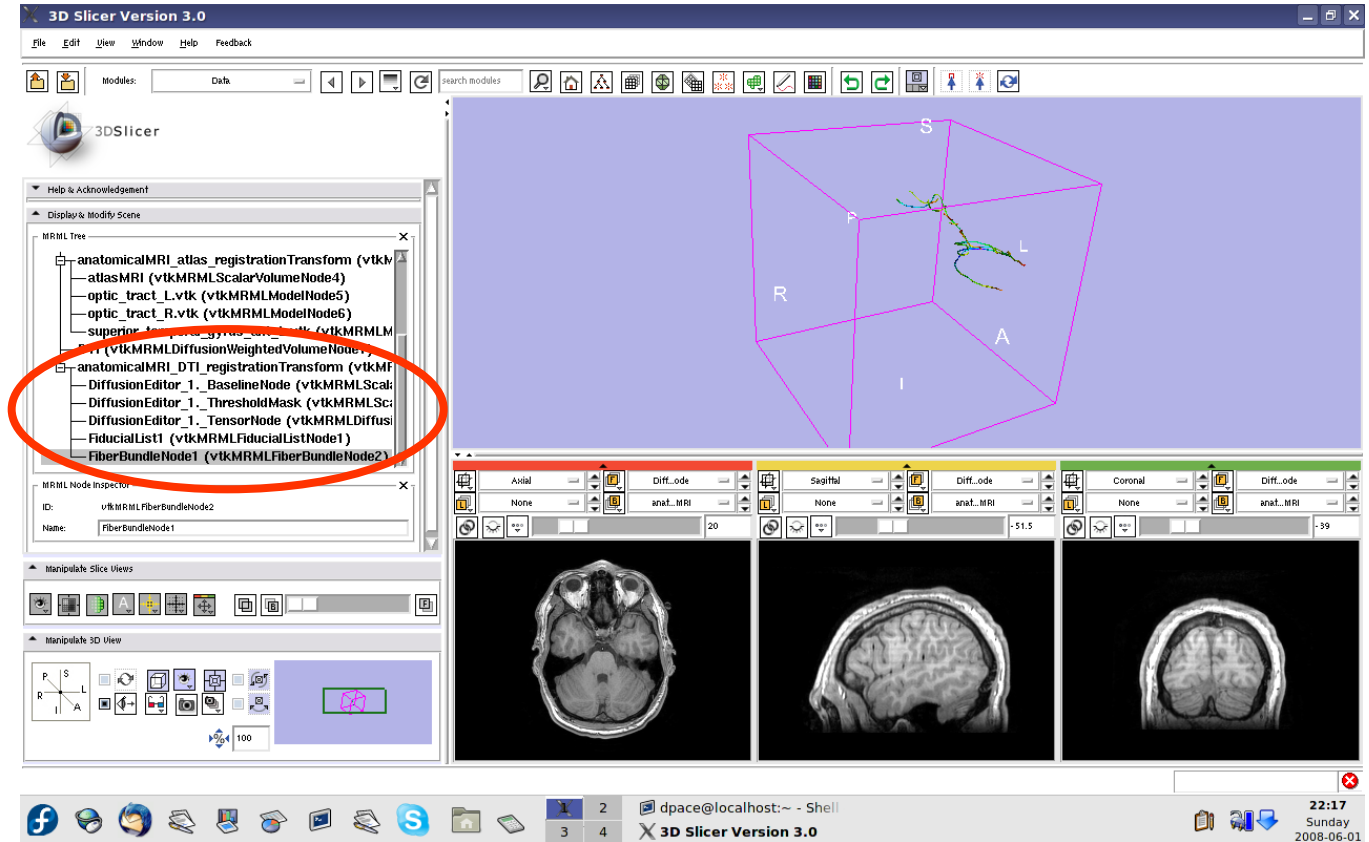
Delete the duplicate BaselineNode node by right-clicking and selecting “Delete Node”





Inspect the MRML scene

Drag the three diffusion editor nodes, the fiducial list used to seed the tractography and the fiber bundle node under the anatomicalMRI_DTI_registrationTransform

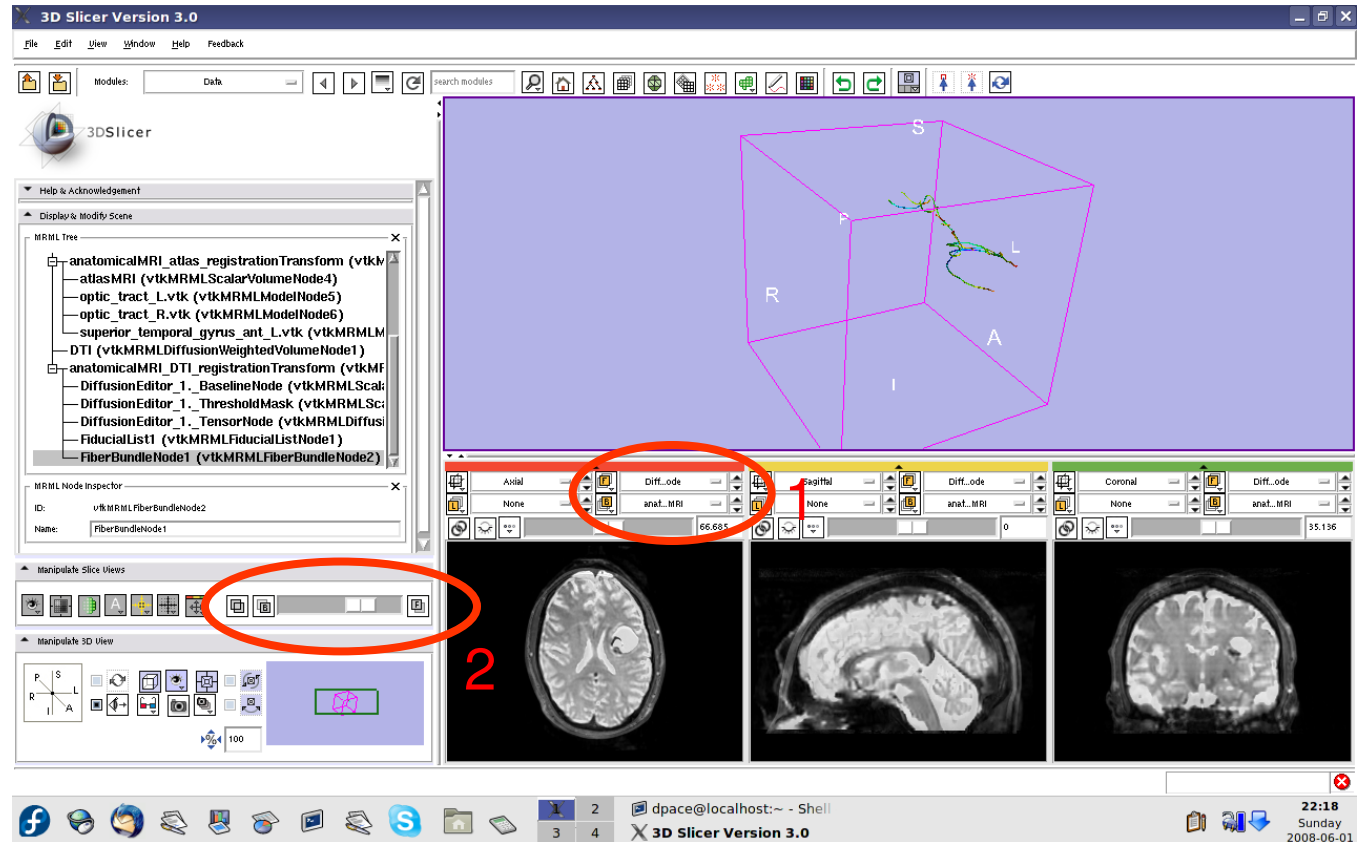




Inspect the anatomical MRI-DTI registration

Set the foreground to the baseline DTI node and the background to anatomicalMRI

Scale the opacities to see how well the atlas MRI and patient anatomical MRI image volumes are aligned

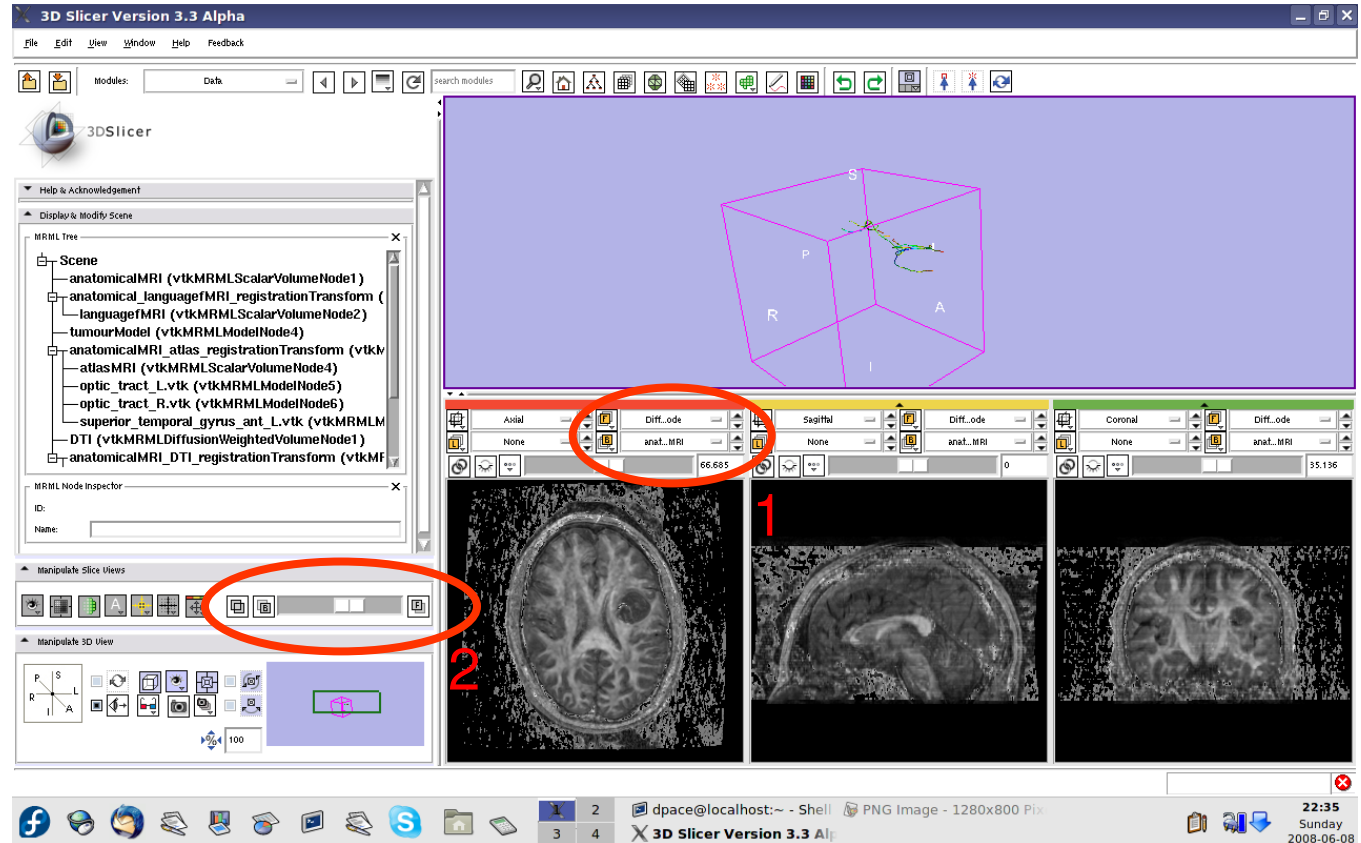




Inspect the anatomical MRI-DTI registration

Set the foreground to the tensor node and the background to anatomicalMRI

Scale the opacities to see how well the DTI FA map and patient anatomical MRI image volumes are aligned



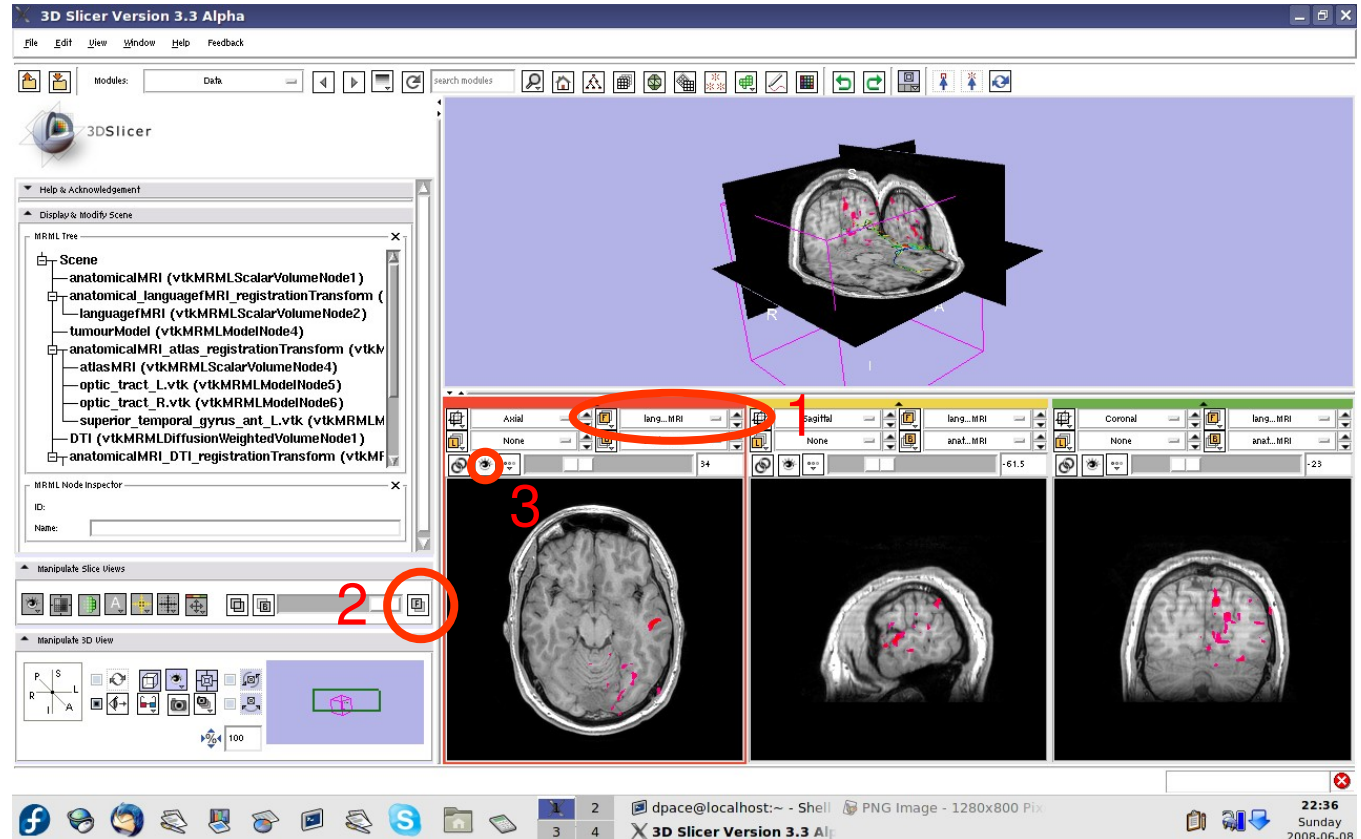


Inspect the entire scene so far

Set the foreground to languagefMRI

Click on the “visibility” button

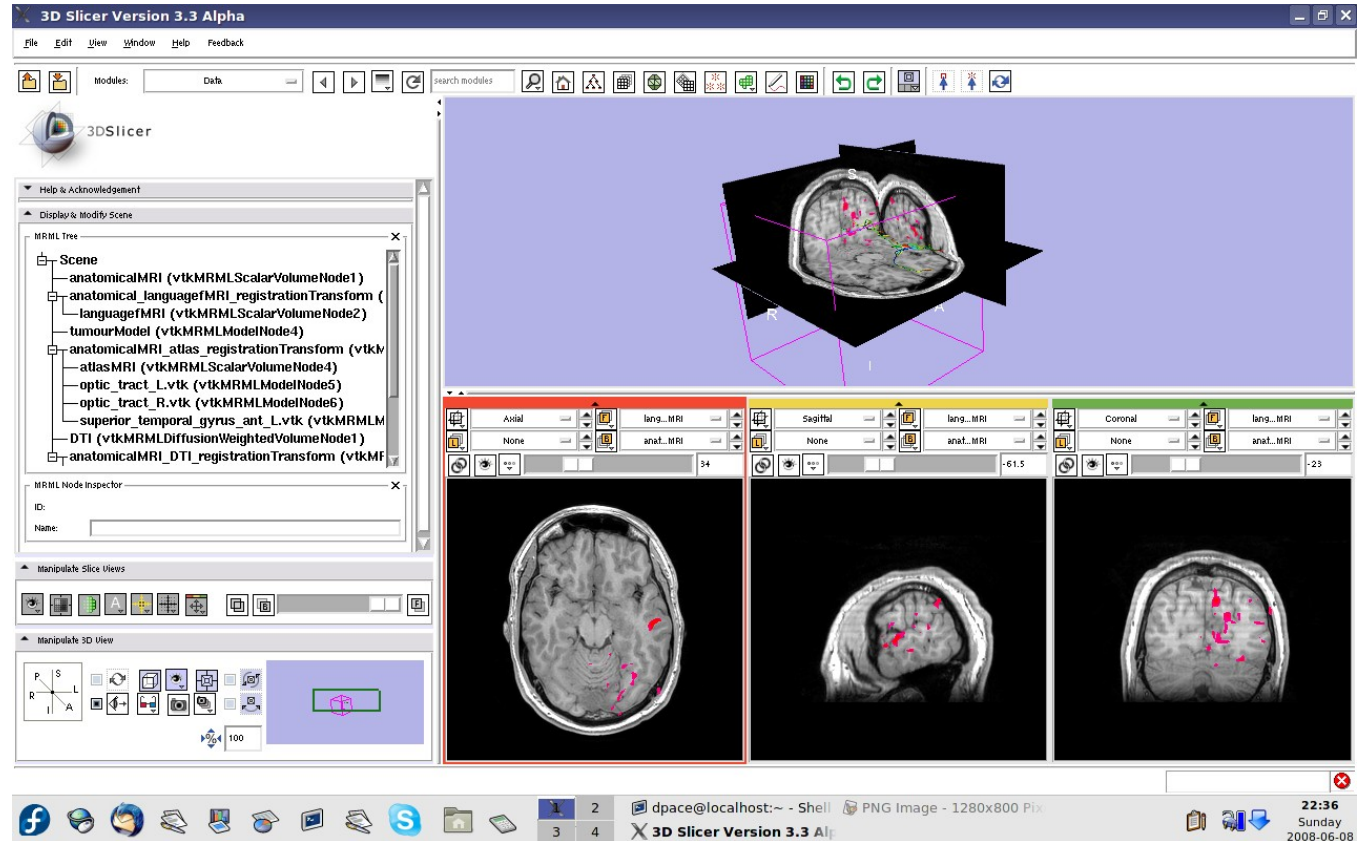Click on the Foreground layer button to show the language fMRI data





Inspect the entire scene so far

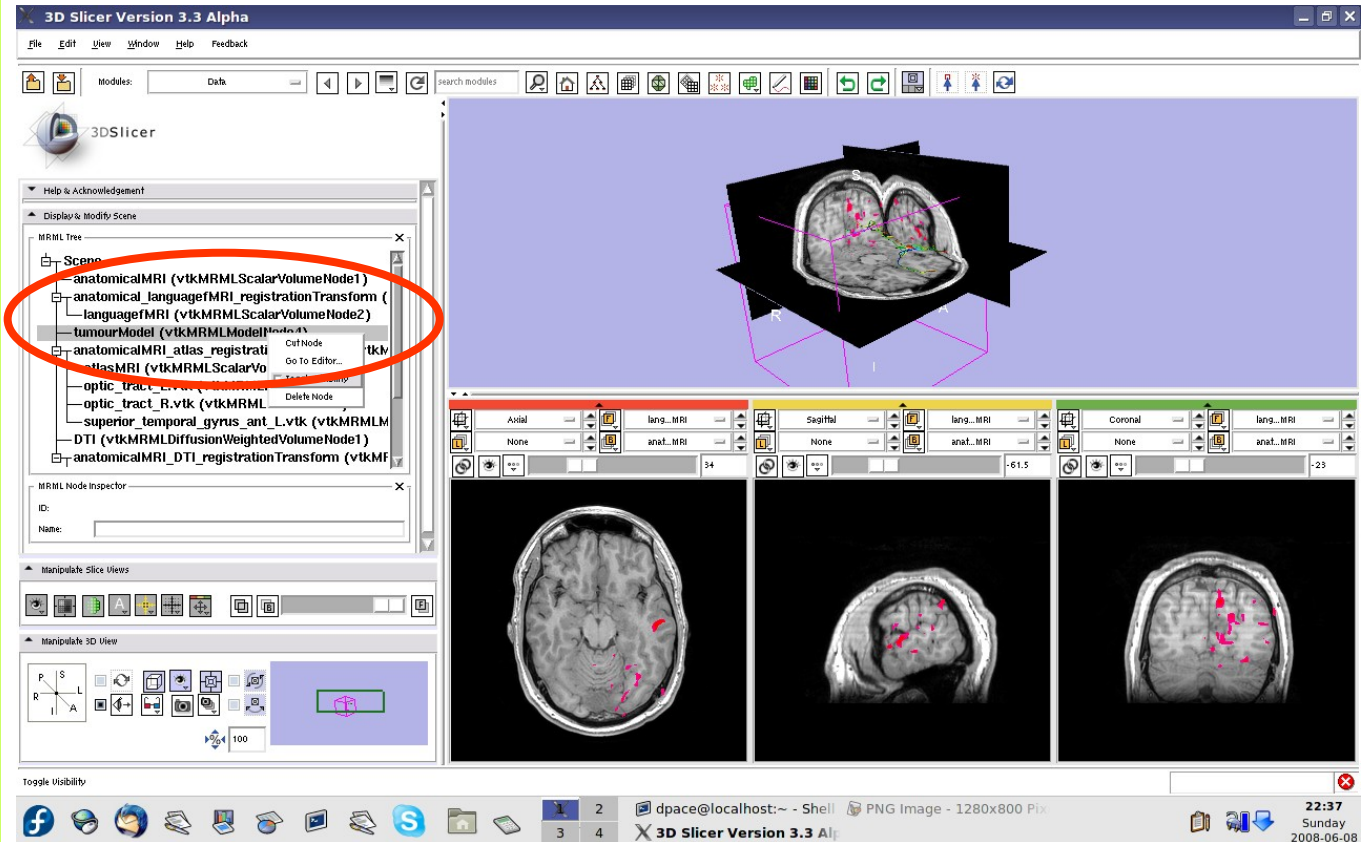
Slice through the image volume to get a good view





Inspect the entire scene so far

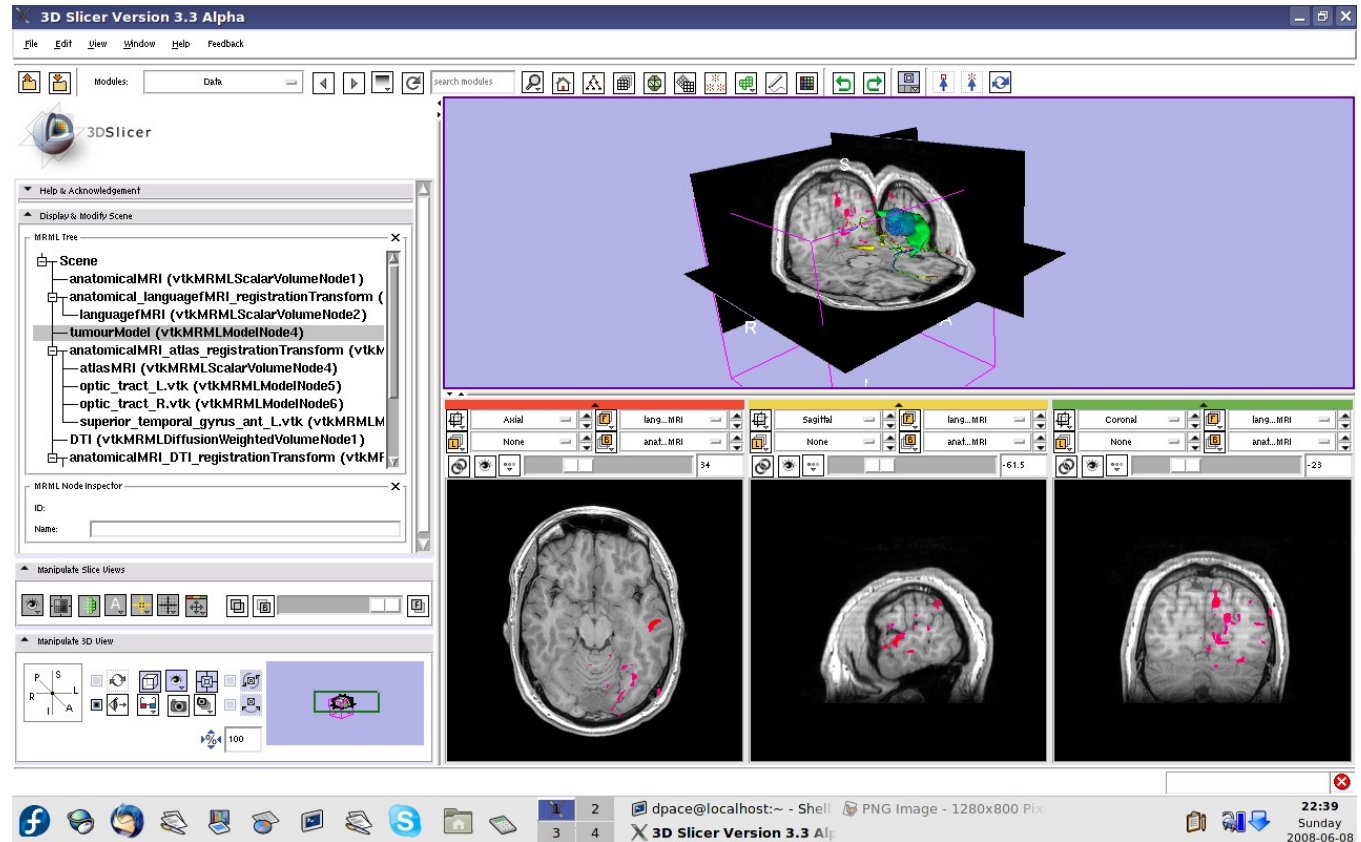
Turn the visibility on for the four models in the scene (tumour, left and right optic tracts, and left anterior superior temporal gyrus) by right-clicking and selecting “Toggle Visibility”





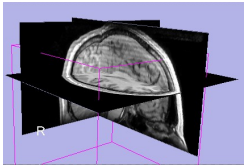
Inspect the entire scene so far

The scene now contains anatomical MRI data, functional MRI data, a segmented tumour volume, estimates of other brain structures and brain fiber tractography

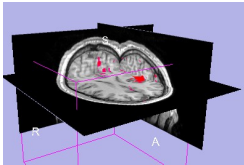




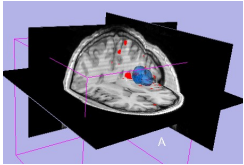
Overview



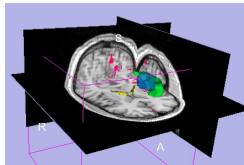
1. Loading and visualizing anatomical MRI data



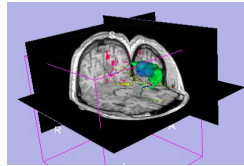
1. Incorporating fMRI data using image registration and thresholding



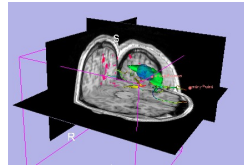
1. Creating a 3D model of the tumour volume



1. Predicting the locations of brain structures using image registration and a brain atlas



1. Incorporating brain fiber tractography from diffusion weighted images

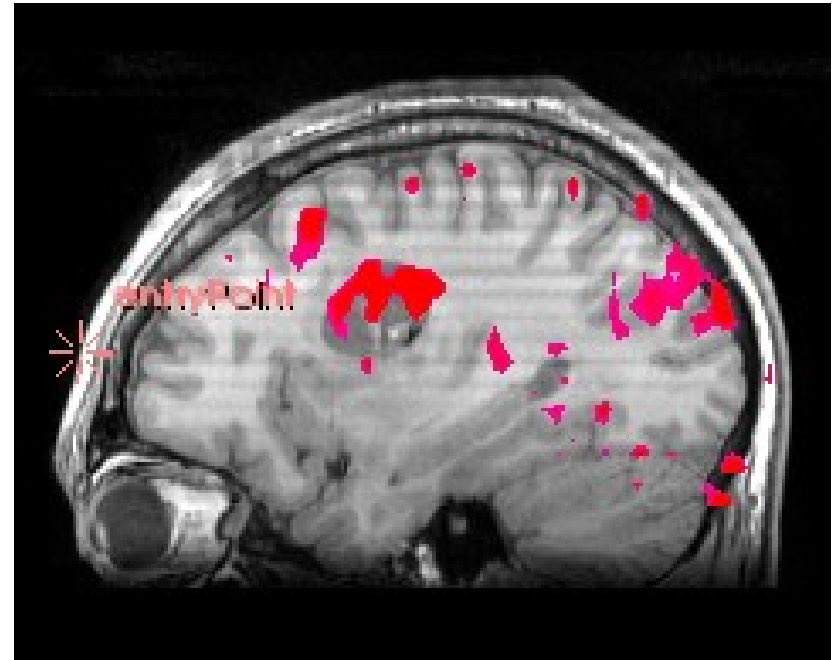


1. **Annotating the preoperative plan and saving the scene**



Plan annotation

- **Utility of plan annotation in IGT:**
 - Surgeons can mark important points on the plan, such as the planned surgical access point, so that their notes can be brought into the operating room





Plan annotation

- **Steps involved in this section:**

Mark the entry point and the tumour access point on the plan

Measure the distance between the two points

Save the scene



Annotate the plan

Open the
Fiducials
module

Create a new
Fiducial List

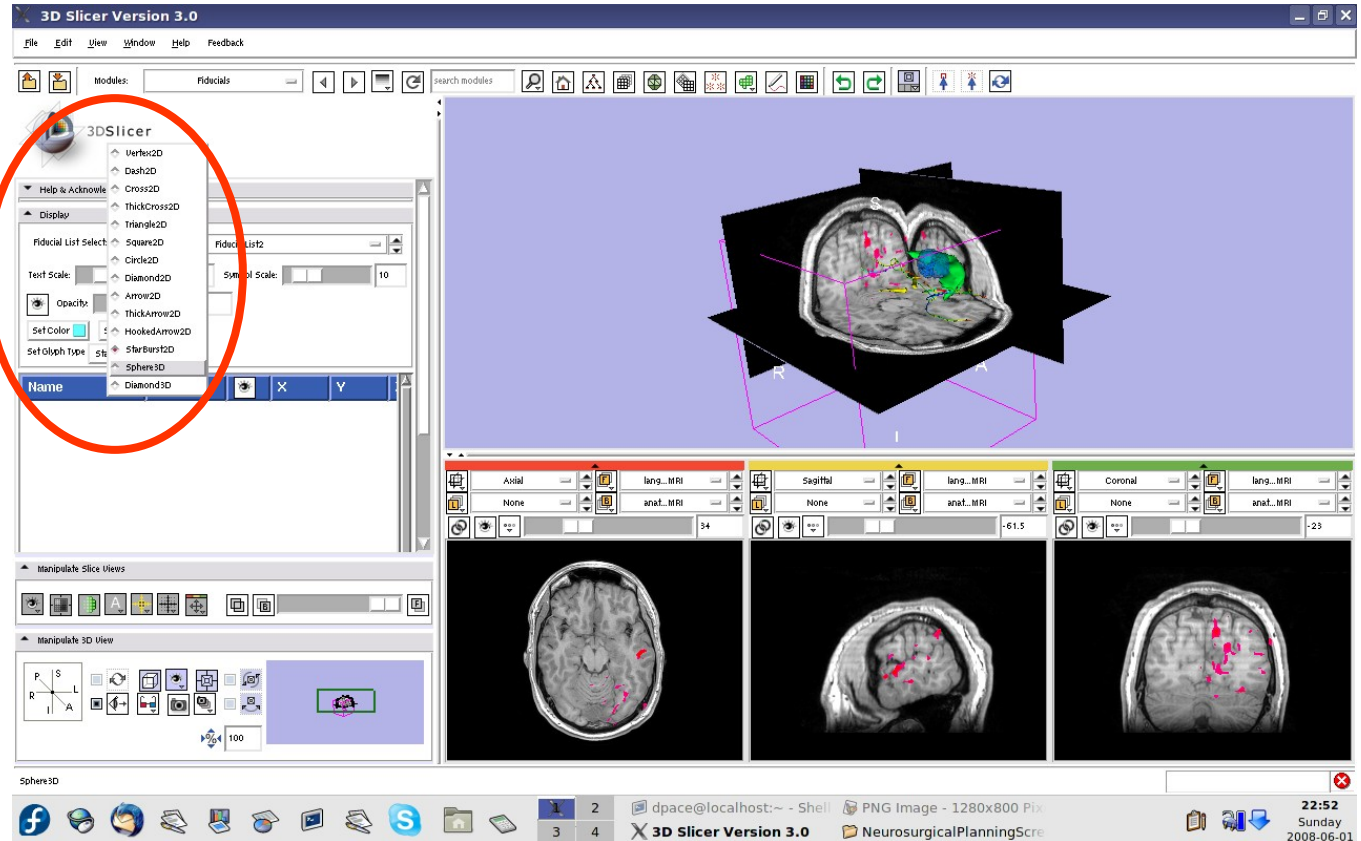
The screenshot shows the 3D Slicer 3.0 interface. The 'Fiducials' module is active, and the 'Create New Fiducial List' button is circled in red. The 'Fiducial List Select' dropdown is also circled in red. The 3D view shows a brain model with several red fiducial markers. The 'Fiducial List' table is visible, listing seven fiducial points (P1-P7) with their coordinates and status.

Name	Selected	X	Y
FiducialList1-P1	<input checked="" type="checkbox"/>	0.00...	-30.4...
FiducialList1-P2	<input checked="" type="checkbox"/>	0.00...	-16.7...
FiducialList1-P3	<input checked="" type="checkbox"/>	0.00...	-4.08...
FiducialList1-P4	<input checked="" type="checkbox"/>	0.00...	4.99...
FiducialList1-P5	<input checked="" type="checkbox"/>	0.00...	14.9...
FiducialList1-P6	<input checked="" type="checkbox"/>	0.00...	24.0...
FiducialList1-P7	<input checked="" type="checkbox"/>	0.00...	31.3...



Annotate the plan

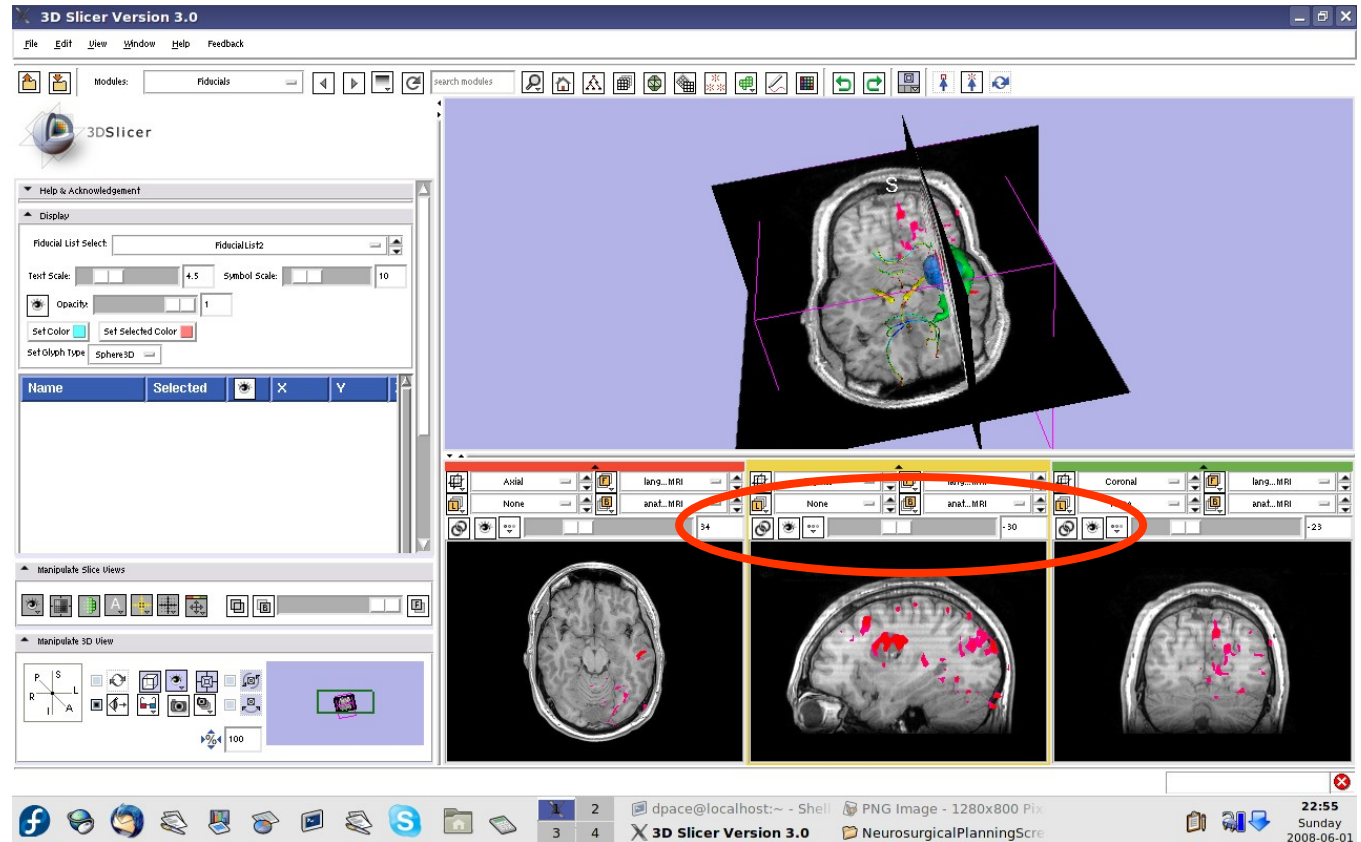
Set the glyph
type to
Sphere3D





Annotate the plan

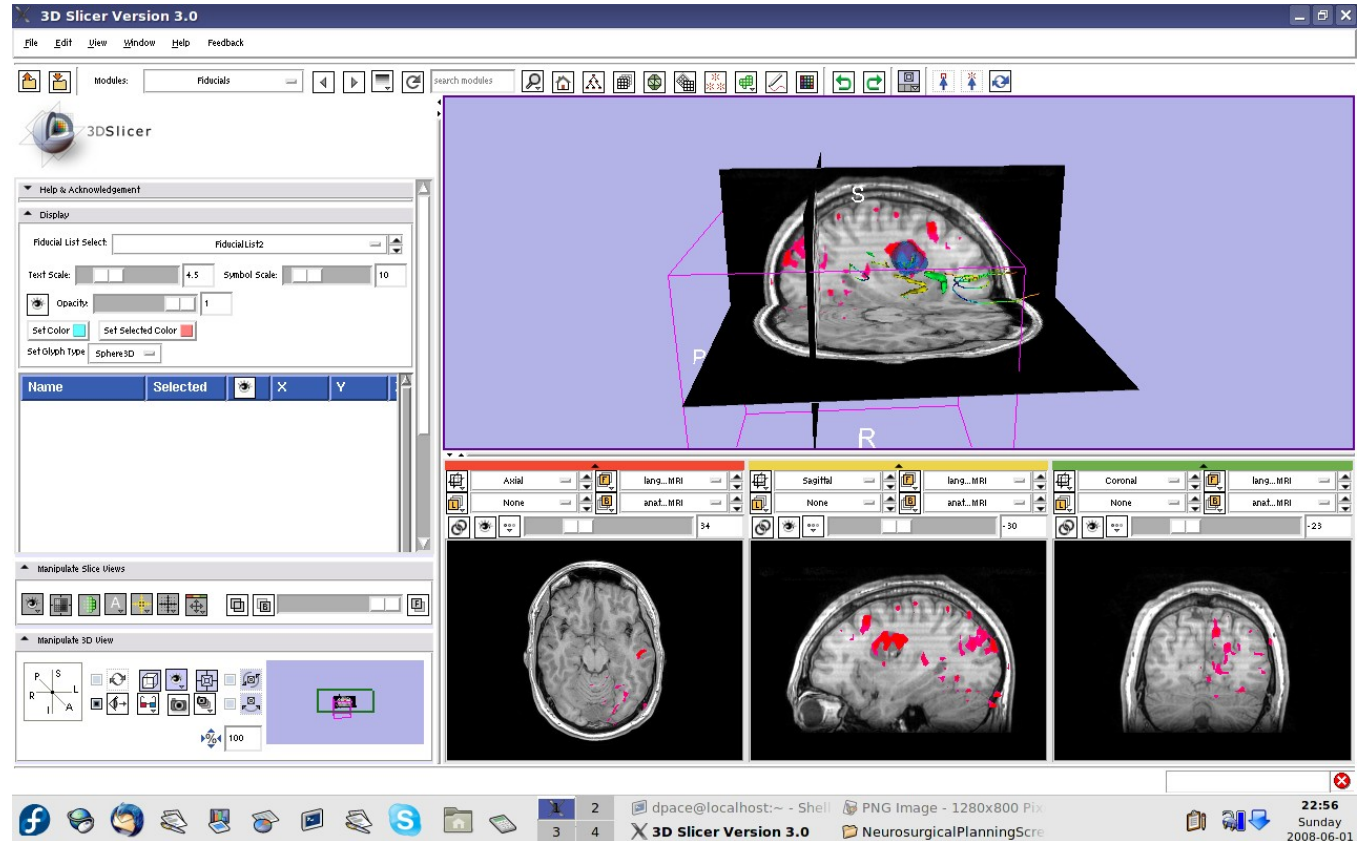
Slice through the sagittal plane until it roughly bisects the tumour volume





Annotate the plan

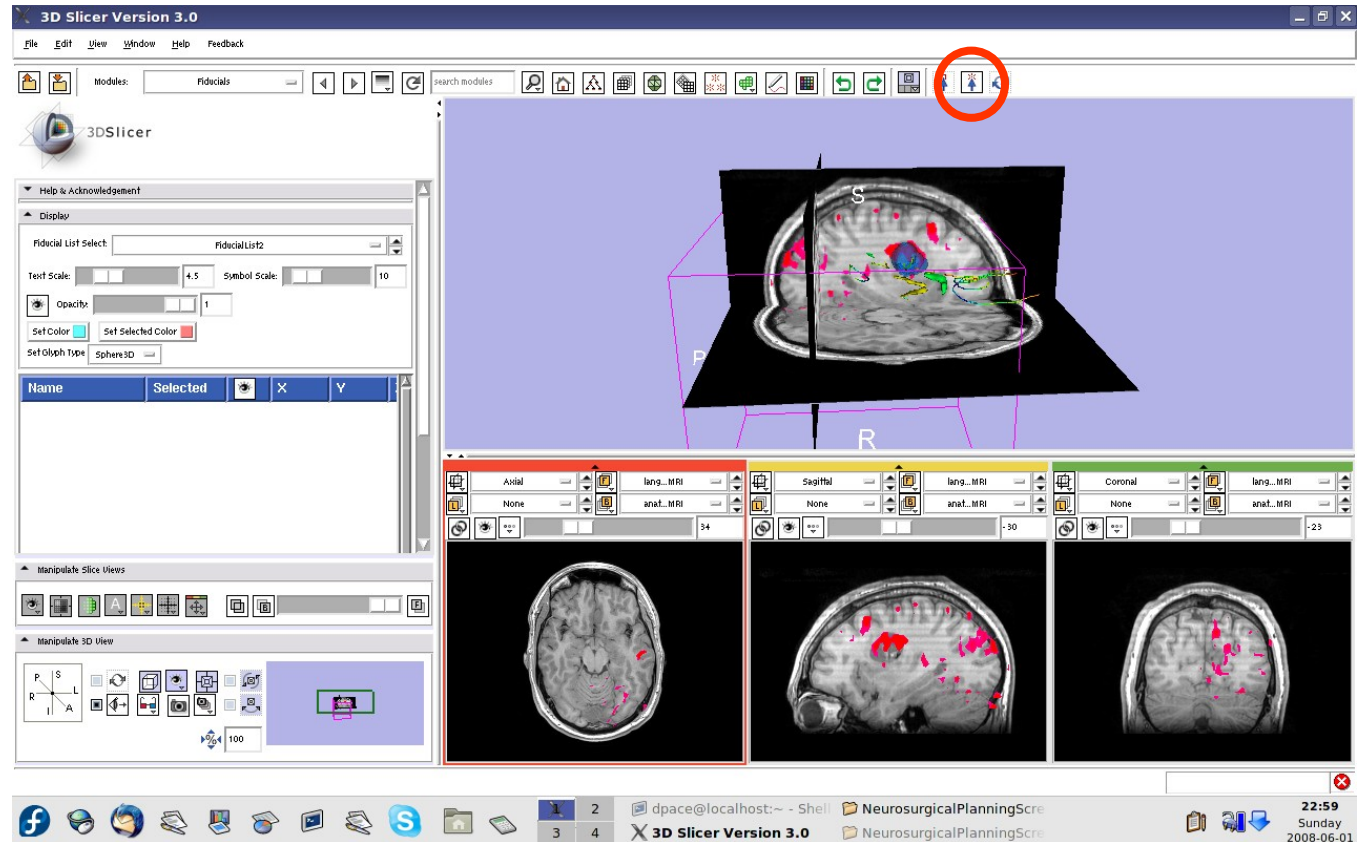
Adjust the 3D Viewer to get a view from the right





Annotate the plan

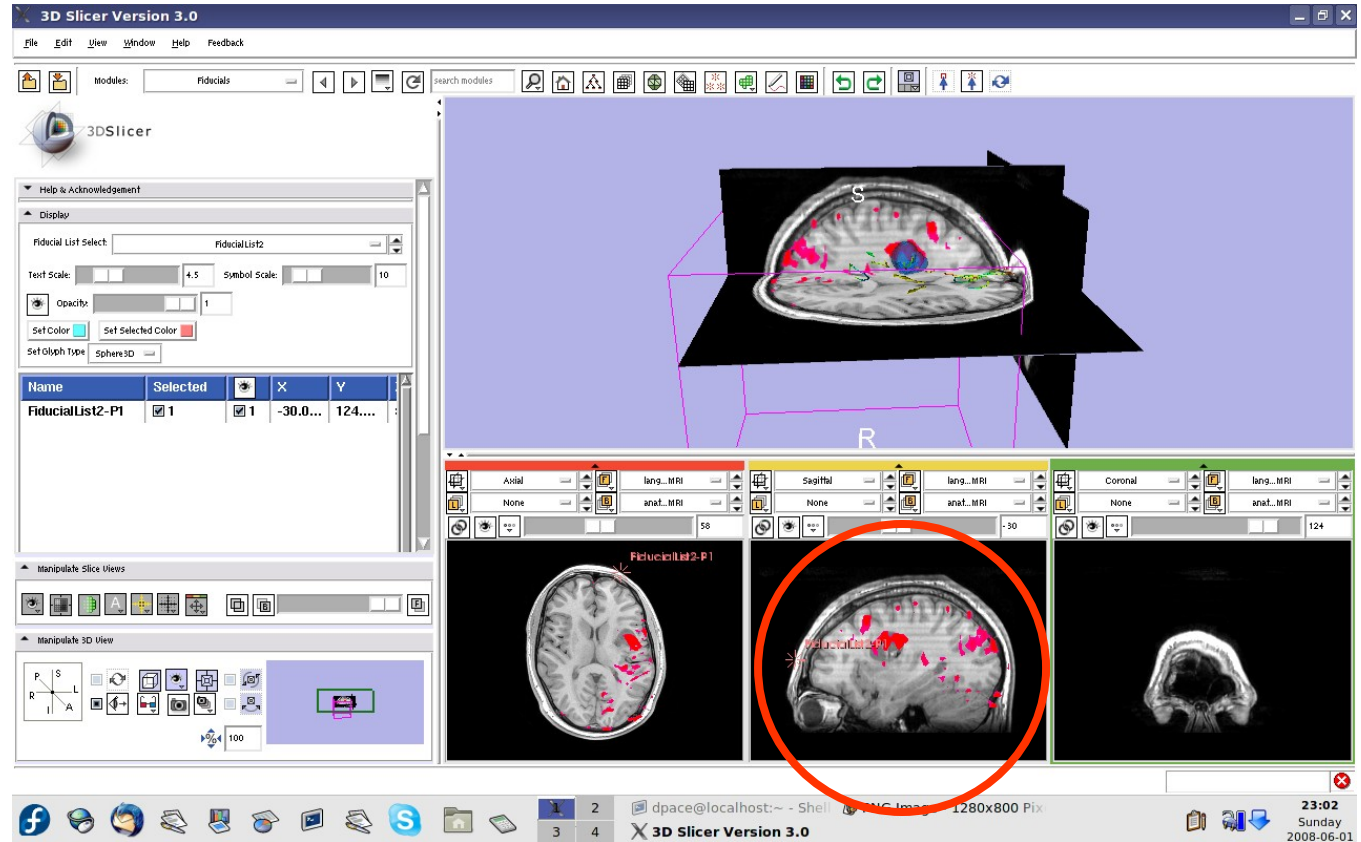
Set the mouse mode to “place items”





Annotate the plan

Place a fiducial on the sagittal plane representing the planned entry point for the left frontal craniotomy





Annotate the plan

Double-click on the name of the fiducial and change it to "entryPoint"

The screenshot shows the 3D Slicer interface with a brain MRI scan. A plan is visible on the scan, and several fiducials are marked. The 'Fiducial List' table is highlighted, showing the following data:

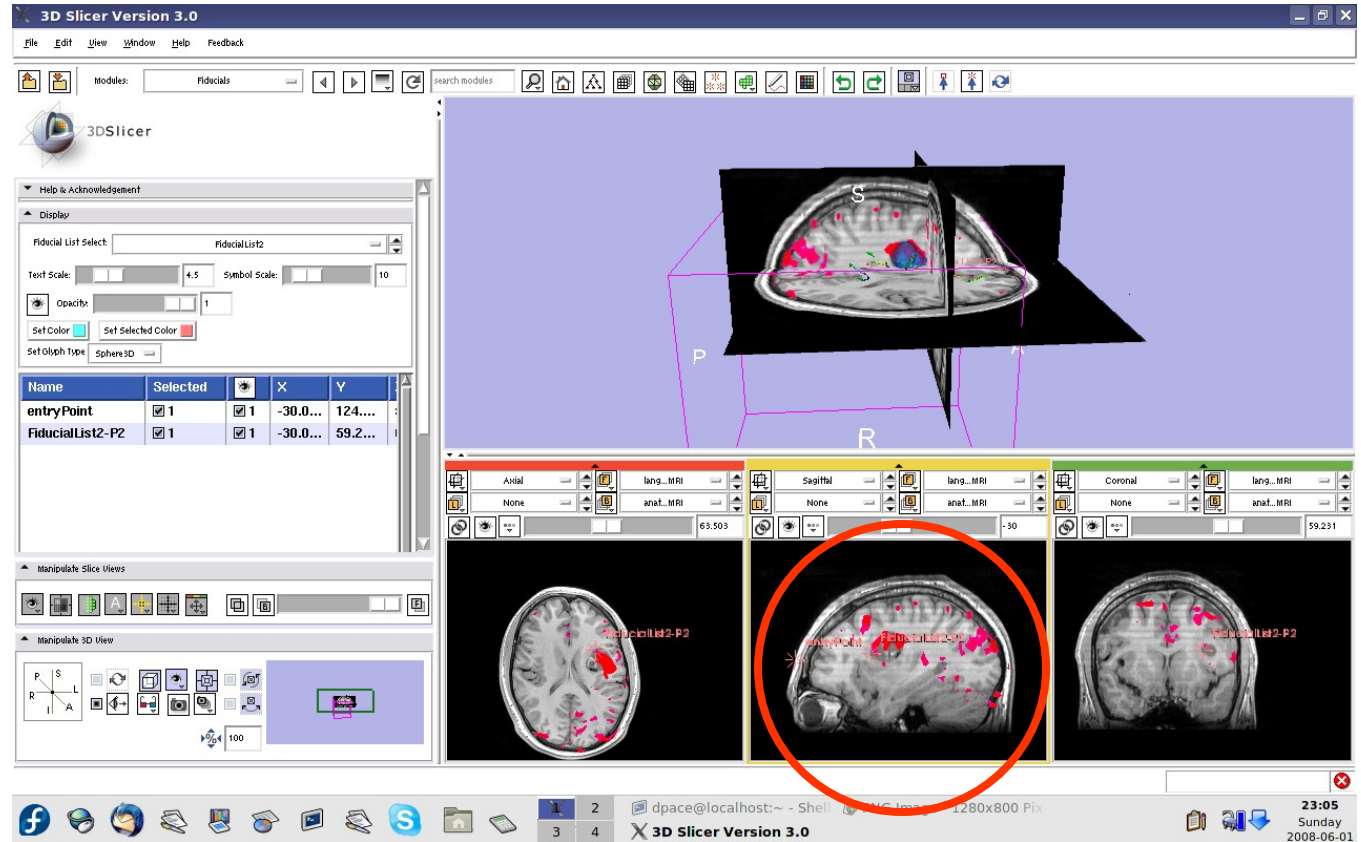
Name	Selected	X	Y
entryPoint	<input checked="" type="checkbox"/>	-30.0...	124...

The 'entryPoint' name is circled in red, indicating the action described in the text.



Annotate the plan

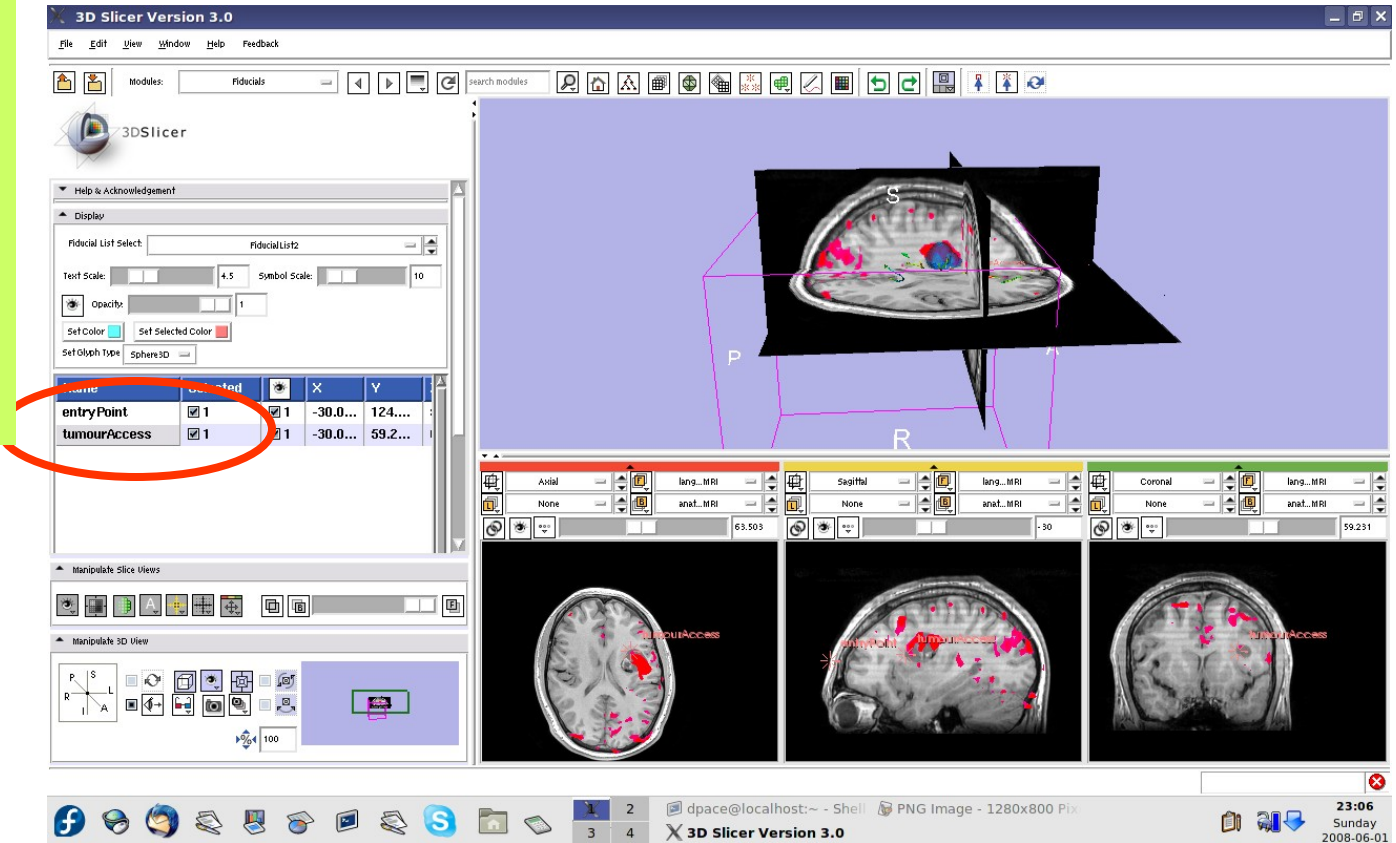
Place a fiducial on the sagittal plane representing the planned access point to the tumour





Annotate the plan

Double-click on the name of the fiducial and change it to “tumour Access”

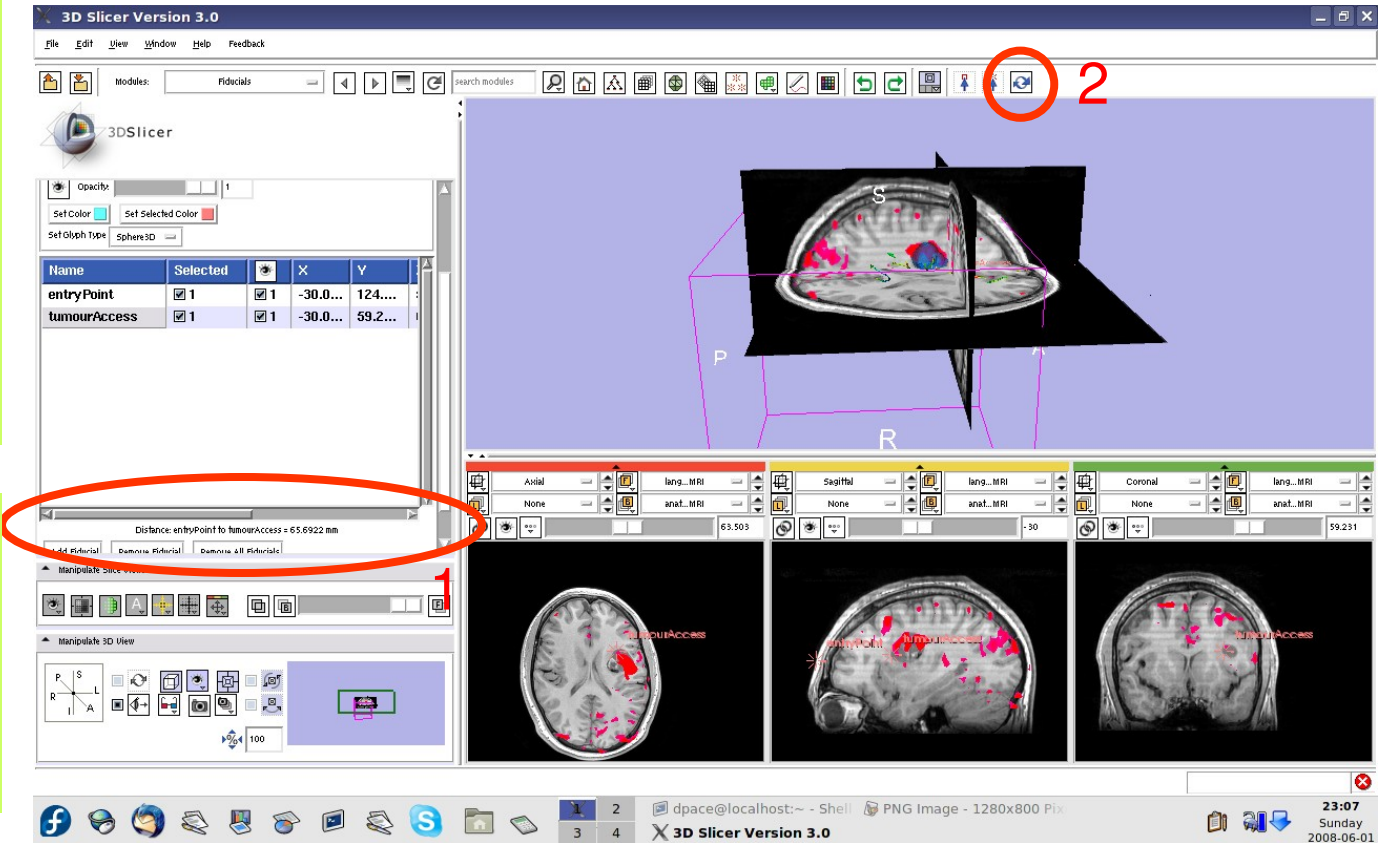




Distance measurements

Scroll down, and note that the distance between the two fiducials is shown

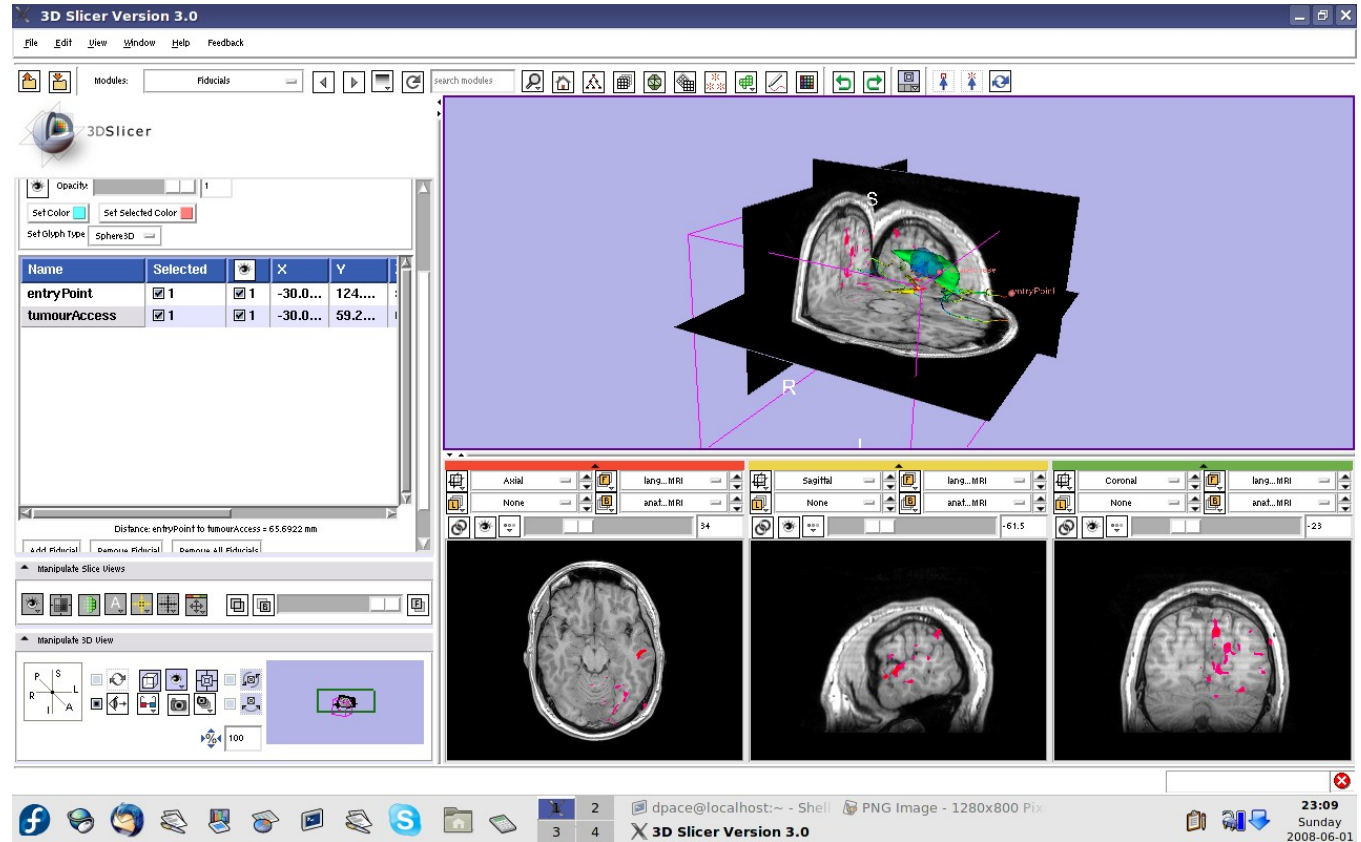
Change the mouse mode to “transform view”





Inspect the final scene

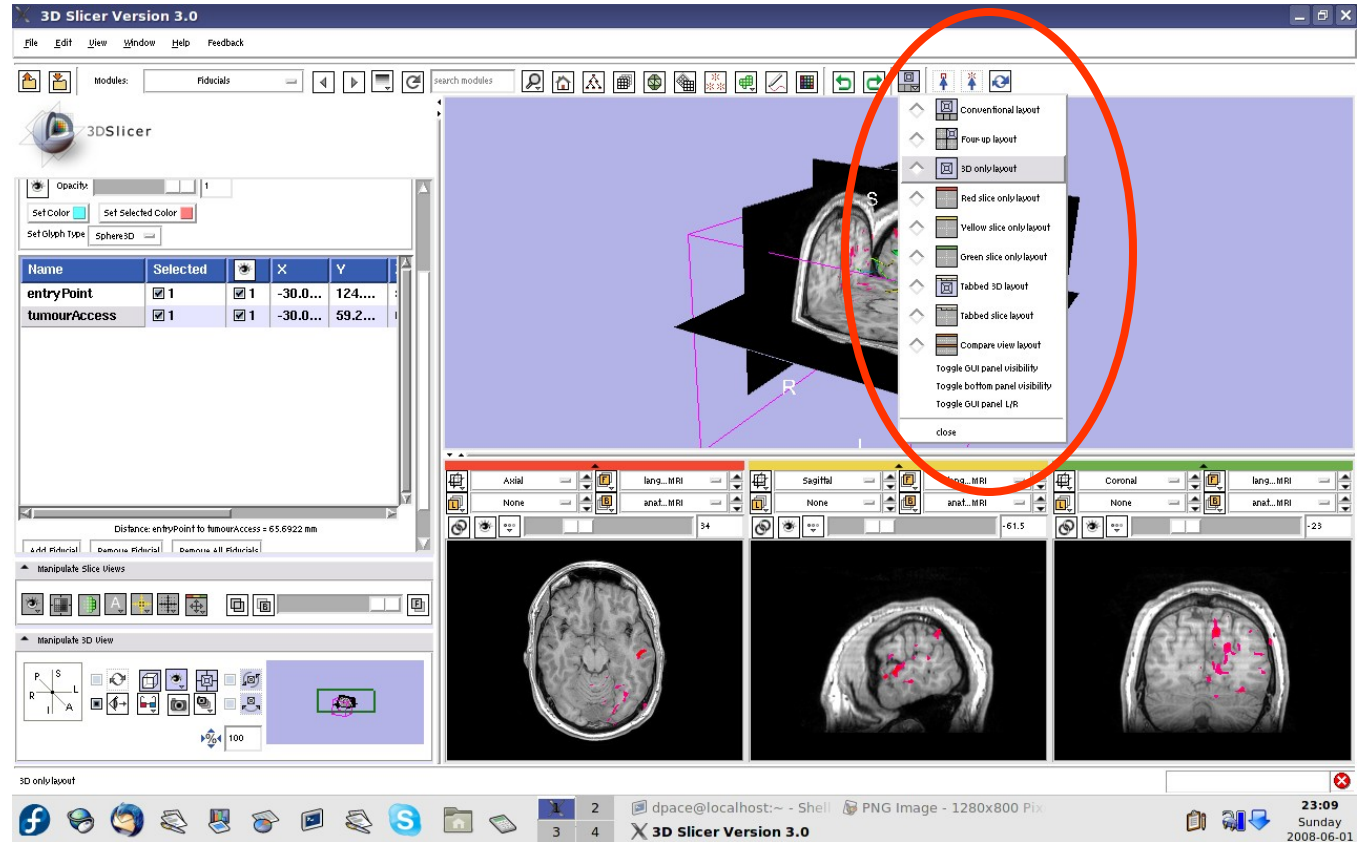
Slice through the image volume to get a good view





Inspect the final scene

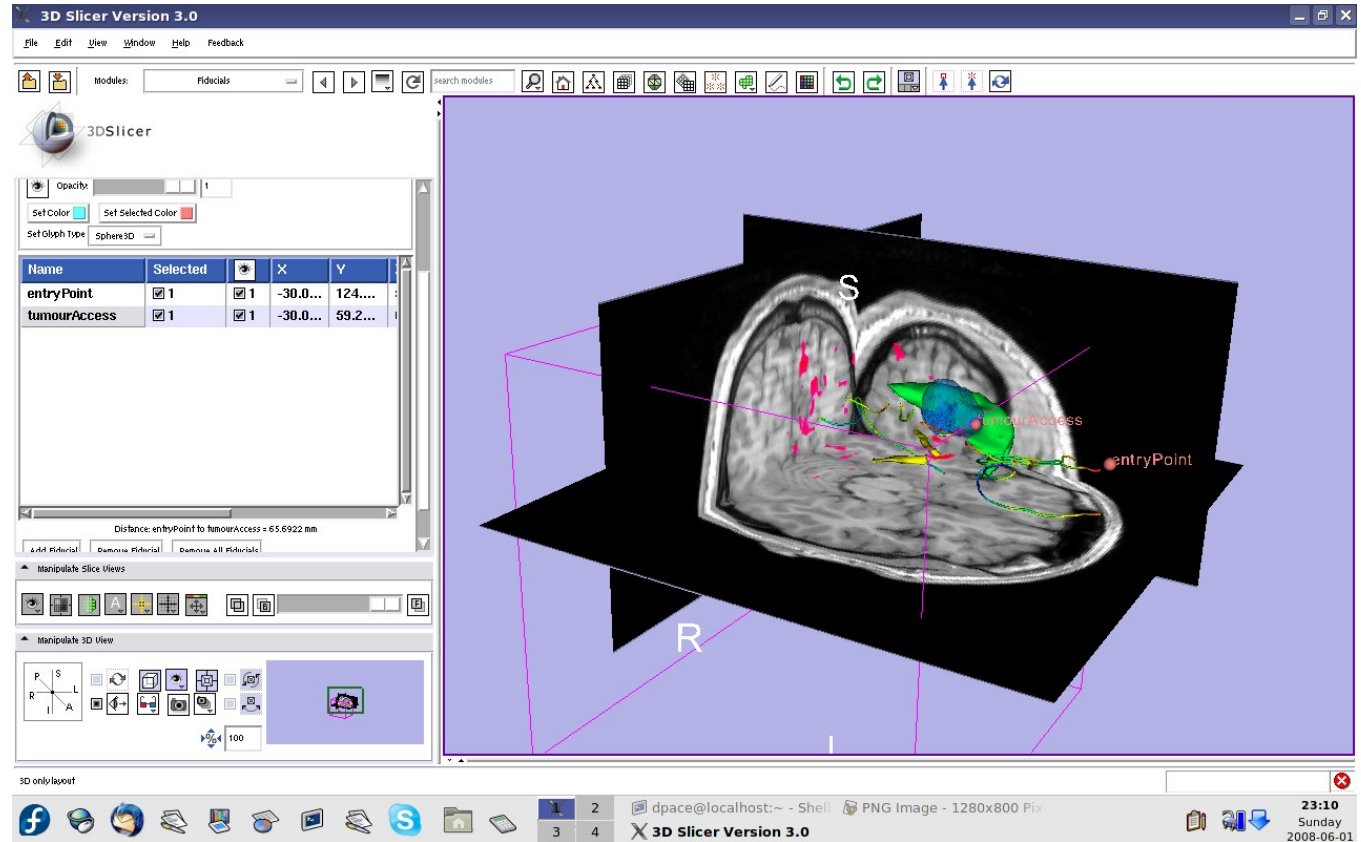
Set the layout to the “3D only layout”





Inspect the final scene

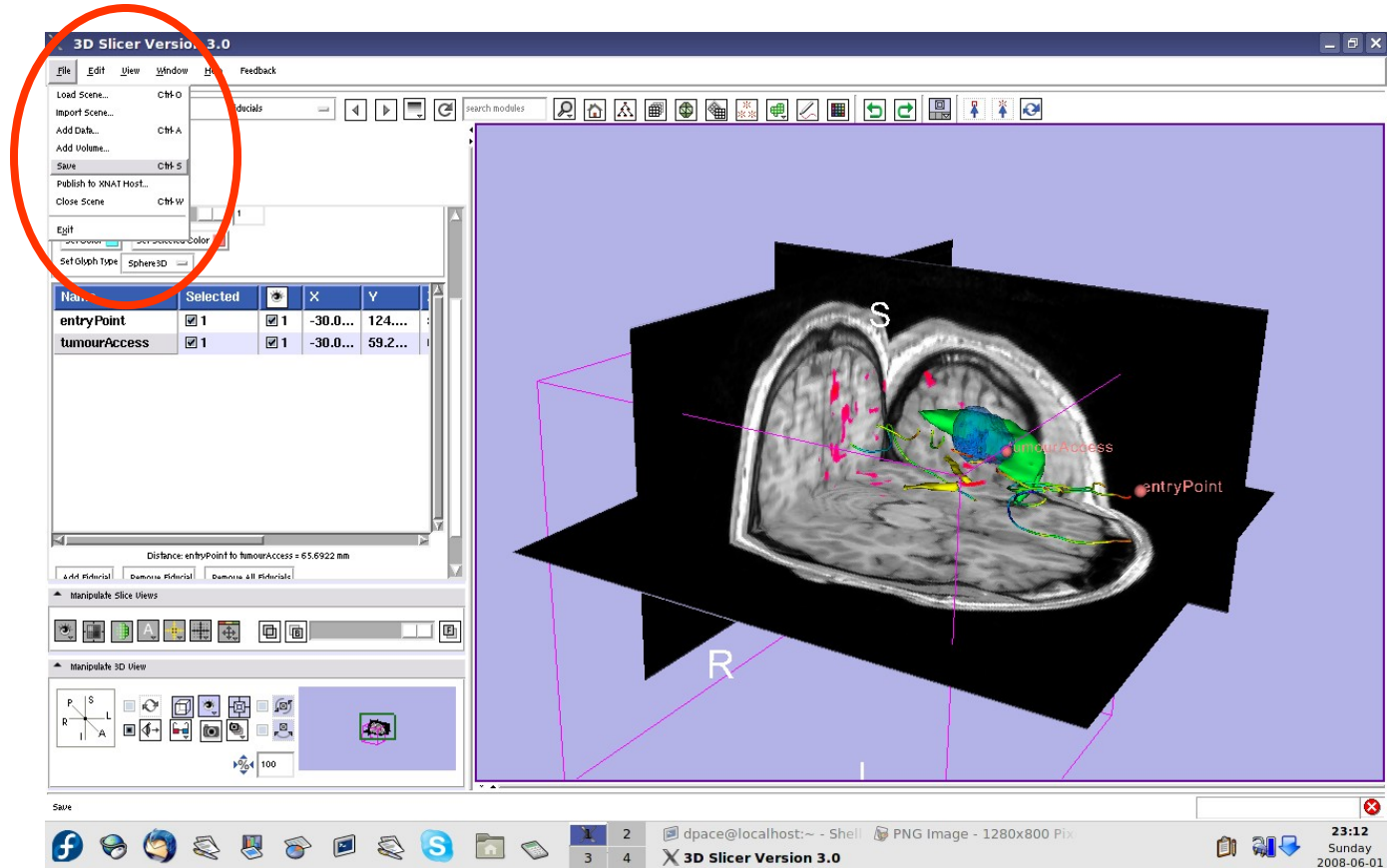
The result of neurosurgical planning





Save the scene

Select File ->
Save



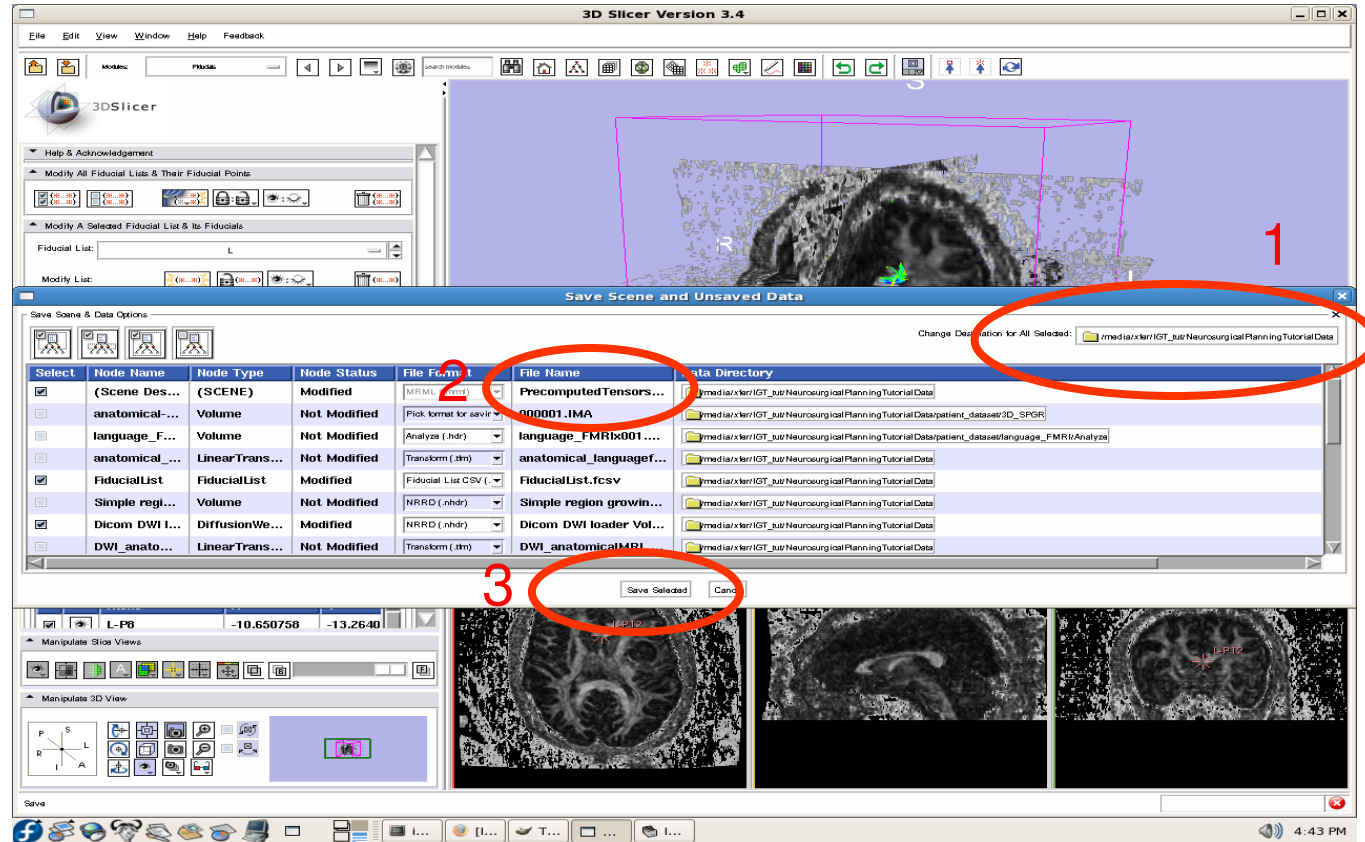


Save the scene

Click to set output directory for all files

Enter Scene Name under Node Type “Scene”

Click “Save Selected”





Overview

- **In this tutorial, you learned how to**
 - Register image volumes together
 - Segment and build models of structures of interest
 - Load diffusion weighted images, calculate tensors and perform fiber tractography
- in order to build a preoperative neurosurgical plan incorporating**
 - anatomical MRI
 - functional MRI
 - a model of the tumour
 - brain structure models from a registered atlas
 - fiber tractography
 - annotated fiducial points



Conclusions

- Slicer3 has extensive support for Image Guided Therapy
- Slicer3 is free open-source software that allows IGT researchers to share algorithms and work within a common framework



For more information...

Image registration:

- Read about the mutual information similarity measure here:

Wells, S. *et al.*, Multi-modal volume registration by maximization of mutual information. *Medical Image Analysis*, 1(1):35-51 (1996).

Collignon, A. *et al.*, Automated multimodality image registration based on information theory. *Proceedings of the International Conference on Information Processing in Medical Imaging*, 263-274 (1995).



For more information...

Model Making:

- Slicer3 uses the marching-cubes algorithm to generate models - read about it here:

Lorensen, W.E. and Cline, H.E. Marching cubes: a high resolution 3D surface construction algorithm. ACM SIGGRAPH Computer Graphics 21(4):163-169, 1987.



For more information...

Diffusion Tensor Imaging:

- A review on DTI:

Le Bihan, D. *et al.*, Diffusion Tensor Imaging: concepts and applications. *Journal of Magnetic Resonance Imaging*, 13:534-546 (2001)

- A review on tractography:

Mori, S. and van Zijl, P.C.M., Fiber tracking: principles and strategies - a technical review. *NMR in Biomedicine*, 15:468-480 (2002)